

M. Zhianpour MD¹
M. Sirus MD²

Primary Ovarian Burkitt's Lymphoma with Peritoneal and Retroperitoneal Metastasis

Ovarian Burkitt's lymphoma is rare in adulthood. Metastatic spread from ovarian malignancies occurs most commonly to the peritoneum, with nodular thickening of the peritoneum and serosal surface of the bowel, omental thickening (omental cake) and ascites. Metastasis to the para-aortic lymph nodes and liver has also been reported. Nonetheless, to the best of our knowledge, metastasis to the retroperitoneum has not still been reported.

Herein, we reported an ovarian Burkitt's lymphoma in a 20-year-old woman who presented with ascites, large bilateral ovarian masses, peritoneal and retroperitoneal metastasis.

In evaluating any ovarian neoplasm with retroperitoneal metastasis in a young woman, Burkitt's lymphoma should be considered as a possibility.

Keywords: ovary, Burkitt lymphoma, peritoneal cavity, retroperitoneal space

Introduction

Primary ovarian lymphoma is very rare and accounts for 1.5% of ovarian neoplasms and 0.5% of non-Hodgkin's lymphomas.¹ Burkitt's lymphoma is a highly undifferentiated B-cell lymphoma. It is a very rare type of rapidly-growing lymphoma and is highly fatal if left untreated.²

Ovarian Burkitt's lymphoma occurs mostly in African children. Burkitt's lymphoma was reported as the most common type of ovarian tumor in 169 Nigerian patients under 20 years of age.³ Involvement of the ovary by Burkitt's lymphoma is uncommon in adults—even in African patients. In a 27-year study on 10 patients with adult-onset Burkitt's lymphoma at the teaching hospital of Ibadan, Nigeria, the incidence of adult involvement was only 3%.⁴

Extragenital involvement occurs early with involvement of the omentum, fallopian tubes or lymph nodes.⁵

We presented this case because of low incidence of the disease and its metastasis to the retroperitoneum.

Case Presentation

A 20-year-old woman admitted for progressive enlargement of abdomen since one month prior to admission.

She had a normal vaginal delivery six months before admission and normal menstrual cycles since 40 days afterward. Positive clinical and laboratory findings are shown in Table 1.

Transvaginal ultrasonography using a 7-MHz transvaginal probe, revealed two large solid masses in the adnexa. The lesions were hypervascular. The uterus was large with loss of differentiation between endometrium and myometrium. There were no signs or symptoms regarding involvement of extra-abdominal organs.

1. Associate Professor, Department of Radiology, Alzahra Hospital, Isfahan University of Medical Sciences, Isfahan, Iran.

2. Assistant Professor, Department of Radiology, Alzahra Hospital, Isfahan University of Medical Sciences, Isfahan, Iran.

Corresponding Author:
Motahare Zhianpour
Address: Department of Radiology,
Alzahra Hospital, Isfahan, Iran.
Tel: +98311-233-4893
Fax: +98311-625-5555
Email: Zhianpour@yahoo.com

Received March 6, 2007;
Accepted after revision November 11,
2007.

Iran. J. Radiol. 2008;5(1):35-38

Based on these data, the diagnosis of choriocarcinoma with metastasis was then made.

After administration of 700 mL of oral and 100 mL intravenous contrast media, a spiral computed tomography (CT) with 10-mm slice thickness, was taken from the abdomen and pelvis of the patient. CT revealed a massive ascites and a huge tumor containing cystic and solid enhancing regions in the left side of pelvis. The tumor extended up to the level of the lower pole of the left kidney. Another similar lesion, although much smaller, was detected in the right side of the pelvis (Fig. 1). Lesions were located anterior to the ureters and tracking of ovarian veins led to tumors. There was right-sided hydronephrosis and encasement of the right distal ureter by the tumor (Fig. 1). Numerous nodules all over the peritoneum suggested peritoneal seeding. Tumors in the pancreatic tail and porta hepatis were noted (Fig. 2).

CT differential diagnoses were: 1) Dysgerminoma, 2) Cystadenocarcinoma, and 3) Krukenberg tumor.

Bilateral salpingo-oophorectomy, right hemicolectomy, appendectomy, partial small intestine resection, debulking of the lesion around the right distal ureter, excision of metastatic lymph nodes and debulking of masses, were performed for the patient. Then, the patient was referred to an oncologist for chemotherapy.

Dysgerminoma was the most likely postoperative diagnosis.

Pathology showed large ovaries measured 20×14×10 and 15×11×17 cm in size with a thin capsule. There was necrosis and hemorrhage in the ovarian lesions, macroscopically. Diffuse neoplastic proliferation of

Table 1. Positive Clinical and Laboratory Findings

Clinical	Routine laboratory tests
Patient complaints	Mild leukocytosis
Progressive enlargement of abdomen	
Physical examination	
Abdominal distention	
Ascites	
Large abdominal masses	

lymphoid cells was evident microscopically. The cells had basophilic cytoplasm and intermediate-sized nuclei with mild pleomorphism and 1–2 nucleoli.

There was also starry sky appearance due to histiocytes with intracytoplasmic debris. Immunohistochemical (IHC) staining was positive in >90% of cells, confirming the final diagnosis of primary Burkitt's lymphoma of the ovaries.

Despite chemotherapy the patient passed away shortly after the surgery.

Discussion

Burkitt's lymphoma is a type of non-Hodgkin's lymphoma derived from B-lymphocytes.

Primary ovarian Burkitt lymphoma is rare. Only one case of Burkitt's lymphoma was found among eight patients with primary ovarian non-Hodgkin's lymphoma in 29 to 62-year-old patients.⁶ In another 11-year study on 101 patients with ovarian tumors in young women, only three cases of Burkitt's lymphoma were reported.⁷

Burkitt's lymphoma occurs most commonly in

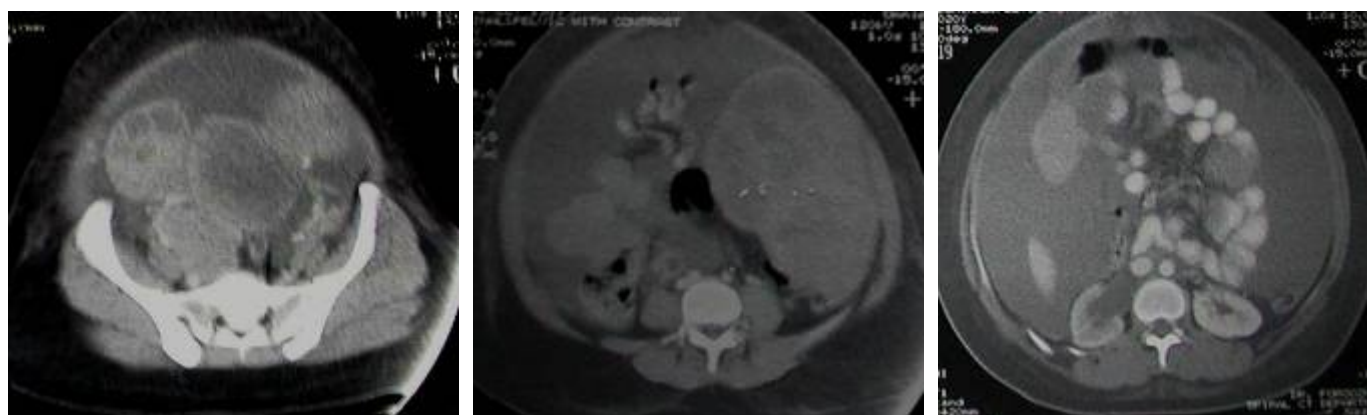

Fig. 1. Spiral abdominopelvic CT with oral and intravenous contrast reveals ascites, bilateral pelvic masses, intraperitoneal masses, encasement of the right ureter by tumor and right-sided hydronephrosis.

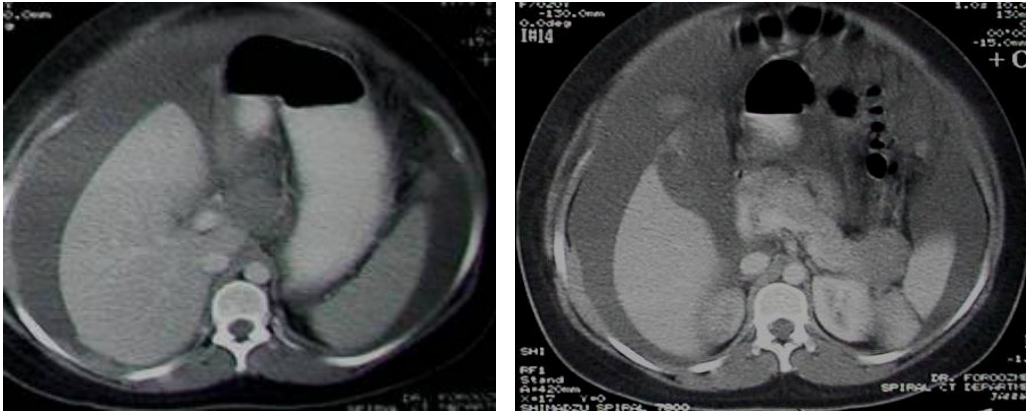


Fig. 2. Masses in porta hepatis and tail of the pancreas.

children.⁸ Common symptoms are abdominal masses and menstrual abnormality. The constant finding at laparotomy is bilateral multinodular ovarian masses.⁴

Patients may present with various clinical pictures. There are reports of unilateral ovarian Burkitt's lymphoma.^{6,9} Bilateral Burkitt's lymphoma with secondary amenorrhea is extremely rare. One case of bilateral ovarian Burkitt's lymphoma with secondary amenorrhea in a 24-year-old woman was previously reported.⁸ Our patient had bilateral Burkitt's lymphoma with normal menstrual cycle.

Burkitt's lymphoma during pregnancy is rare.² Our patient has referred to the hospital six months after delivery and considering that the doubling time for Burkitt's lymphoma is almost 24 hours,⁵ we believe that she was disease-free during her pregnancy.

Deciding whether ovarian malignancy is primary or secondary is not always easy. We believe that the diagnosis of primary ovarian Burkitt's lymphoma in our patient was based on the location of the tumor bulk in the ovaries and that there was no evidence of lymphoma elsewhere.

The anatomic location of ovaries are anterior or anterolateral to the ureters. Therefore, tracking of ovarian veins along the anterior surface of psoas major muscles to ovaries is easy by CT.¹⁰ In our patient, CT showed bilateral tumors anterior to ureters and the ovarian veins led to lesions.

No specific imaging features can differentiate Burkitt's lymphoma from other neoplasms and the diagnosis is not expected before histologic examination of the tumor.¹¹

Imaging appearance of our patient was hypo-echoic on ultrasonography, vascular on Doppler and mixed

density with contrast enhancement on CT, which is similar to those reported by Eren, et al,⁵ and Ferrozzi, et al.¹² There are reports of metastasis of tumor to the peritoneum with omental cake and to the serosal surface of the bowel. Nevertheless, spreading of ovarian Burkitt's lymphoma to retroperitoneum and tail of the pancreas has not been reported earlier, to the best of our knowledge.

Although ovarian Burkitt's lymphoma is rare, it should be considered in the differential diagnosis of malignant ovarian tumors, especially in patients under the age of 20 years.

References

1. Yamada T, Iwao N, Kasamatsu H, Mori H. A case of malignant lymphoma of the ovary manifesting like an advanced ovarian cancer. *Gynecologic Oncol* 2003 July;90(1):215-9.
2. Magloire LK, Pettker CM, Buhimschi CS, Funai EF. Burkitt's lymphoma of the ovary in pregnancy. *Obstet Gynecol* 2006 Sep;108(3Pt2):743-55.
3. Junaid TA. Ovarian neoplasms in children and adolescents in Ibadan, Nigeria. *Cancer* 1981 Feb 1; 47(3):610-4.
4. Konje JC, Otolorin EO, Odukova OA, Ladipo OA, Ogunniyi J. Burkitt's lymphoma of the ovary in Nigerian adults—a 27-year review. *Afr J Med Med Sci* 1989 Dec;18(4):301-5.
5. Eren S, Kantarci M, Erdogan F. Ovarian Burkitt's lymphoma as a cause of 'omental cake' sign on computerized tomography. *J Obstet Gynaecol* 2004 Jun; 24(4):463-5.
6. Vang R, Medeiros LJ, Warnke RA, Higgins JP, Deavers MT. Ovarian non-Hodgkin's lymphoma: a clinicopathologic study of eight primary cases. *Mod Pathol* 2001 Nov;14(11):1093-9.
7. Sengupta SK, Everett VJ. Ovarian neoplasms in children and adolescents in Papua New Guinea. *Aust N Z J Obstet Gynaecol* 1987 Nov;27(4):335-8.
8. Baloglu H, Turken O, Tutuncu L, Kizilkaya E. 24-year-old female with amenorrhea: bilateral primary ovarian Burkitt lymphoma. *Gynecol Oncol* 2003 Nov;91(2):449-51.
9. Mukhtar AU, Mugerwa B. Burkitt's lymphoma of the ovary. *Cent Afr J Med* 1999 Apr;45(4):104-5.
10. Faysal AS, Samuel CJ. Recognition of the ovaries and ovarian origin of pelvic masses with CT. *Radiographics* 2004;24:133-46.

11. Chishima F, Hayakawa S, Ohta Y, Sugita K, Yamazaki T, Sugitani M, et al. Ovarian Burkitt's lymphoma diagnosed by a combination of clinical features, morphology, immunophenotype, and molecular findings and successfully managed with surgery and chemotherapy. *Int J Gynecol Cancer* 2006 Jan-Feb;16(Suppl1):337-43.
12. Ferrozzi F, Catanese C, Uccelli M, Bassi P. Ovarian lymphoma. Findings with Ultrasonography, computerized tomography and magnetic resonance. *La Radiologia Medica* 1998;95:493-7.