

H. Mazaher MD<sup>1</sup>  
 Sh. Sharif Kashani MD<sup>1</sup>  
 H. Sharifian MD<sup>1</sup>

## Fibrosis Index: A New Doppler Index for Differentiation of Cirrhosis from Chronic Hepatitis

**Background/Objective:** So far, many authors have conducted several studies to assess the value of Doppler sonography in distinguishing cirrhosis from chronic hepatitis. However, none of them has been proved to be used in clinical settings. We developed a new Doppler index, the so-called "Fibrosis index", and performed a prospective study to evaluate its efficacy in differentiation of cirrhosis from chronic hepatitis.

**Patients and Methods:** 30 patients with biopsy-proven cirrhosis and 30 patients with chronic viral hepatitis (HBV or HCV) underwent US and histologic examination. Doppler sonography was performed by a sonologist, and histologic assessment was done by a pathologist, both of whom were blind to the results of each other. A series of Doppler indices of hepatic circulation including peak portal flow velocity, resistive index of hepatic artery and "fibrosis index," a new index introduced here, which is defined as the resistive index of hepatic artery divided by peak portal flow velocity multiplied by 100 were measured. These indices were compared across the two study groups.

**Results:** The result of histopathology examination showed that six patients from chronic hepatitis group had also cirrhosis; so there were 24 cirrhotic and 36 patients with chronic hepatitis. Significant differences were observed in the resistive index of hepatic artery, peak portal flow velocity and fibrosis index between the two groups of patients. Based on the statistical analysis a cut-off value was set for fibrosis index. The sensitivity, specificity and accuracy of the fibrosis index were 94.4%, 100%, and 96%, respectively.

**Conclusion:** Assessment of fibrosis index, as a Doppler-derived index, is an appropriate non-invasive method for distinguishing cirrhosis from chronic hepatitis and might decrease the need for biopsy in the suspected patients.

**Keywords:** Doppler sonography, cirrhosis, chronic hepatitis

### Introduction

Cirrhosis, the end-stage of many diseases like viral and drug-induced hepatitis, causes a lot of complications and no treatment is still available but liver transplantation. As the majority of cases who will terminate in cirrhosis such as chronic hepatitis, might cure in earlier stages, the differentiation between chronic liver disease and cirrhosis is quite important.<sup>1</sup> Until recently, liver biopsy was the only means to evaluate hepatic fibrosis.<sup>2</sup> However, liver biopsy is an invasive and painful procedure, and associates with low, but a definite risk of patient morbidity and mortality.<sup>1,3-6</sup> Therefore, it is important to use non-invasive methods in differentiation between cirrhosis and the stages before cirrhosis.

Changes in hemodynamic circulation of the liver occur as chronic liver disease progresses to liver cirrhosis. Doppler sonography provides a quantitative measurement of blood flow to the liver, thus, many researchers have investigated the efficacy of Doppler sonography as an inexpensive and non-invasive method of assessing the degree of hepatic fibrosis. Some studies could show the difference between cirrhosis and the stages before cirrhosis by measuring hepatic artery resistive indices (RI), which is significantly higher in the cirrhotic patients. Some authors demonstrate that the blood velocity in portal vein is lower in cirrhotic

I. Assistant Professor, Department of Radiology, Amir A'alam Hospital, Tehran University of Medical Sciences, Tehran, Iran.

Corresponding Author:  
 Shervin Sharif Kashani  
 Address: Department of Radiology, Amir A'alam Hospital, Tehran, Iran.  
 Tel: +98-21-66704998  
 Fax: +98-21-66704805  
 E-mail: sh\_shk\_md\_rad@yahoo.com

Received June 20, 2006;  
 Accepted after revision September 2, 2006.

Autumn 2006; 7-10

patients than in patients with chronic hepatitis. Furthermore, there are other studies who used the measurement of relative flow or blood velocity in the hepatic artery and vein.<sup>7-15</sup> However, there is controversy on the reproducibility of these studies and none of them described a definite method for differentiation between cirrhosis and the stages before cirrhosis. Regarding to the fact that the hepatic artery RI in cirrhosis is higher than chronic hepatitis, and the peak portal flow velocity (PPFV) is lower in cirrhosis than in chronic hepatitis, we considered a ratio of these two parameters as a new and potentially better index for differentiation of cirrhosis from chronic hepatitis. As a result, we conducted this study to evaluate the efficacy of the index for differentiation cirrhosis from chronic hepatitis.

## Patients and Methods

### Patient population

From January 2004 to February 2005, 30 patients with biopsy-proven cirrhotic liver disease and 30 patients with chronic viral hepatitis proven by serologic tests for hepatitis C and B virus, underwent Doppler sonography (US) and histologic examination. The patients with primary diagnosis of chronic hepatitis underwent liver biopsy; according to the histopathology results, six patients from them had also cirrhosis. Therefore, there were 36 patients with cirrhotic group and 24 patients had chronic hepatitis.

Patients co-infected with other viral hepatitis or human immune deficiency virus (HIV) were excluded from the study. Due to the effects of aging on hemodynamics of liver and the higher rate of portal blood flow in children, only those patients aged between 14 and 70 years were included in the study. The patients using oral contraceptive pills or any other regular medications, those consumed more than 10 g of alcohol per day, with hypertension, diabetes mellitus, and advanced cirrhosis (class 'C' of the Child-Pugh scheme) were excluded from the study. Those patients in whom it was not possible to approach and evaluate the peak portal flow velocity (PPFV) at porta hepatis with a Doppler angle lower than 60 degree were also excluded from the study.

The liver biopsy specimens of  $\geq 2$  cm in length were considered as appropriate and interpreted by a single

independent pathologist who did not aware of the sonography results. The pathologist report was cirrhotic or non-cirrhotic, according to the modified HAI classification (stages 5 and 6 were considered cirrhosis). The time between sonography and histology examination was not longer than three weeks.

All patients gave written informed consent; this study was conformed to the guidelines outlined by the declaration of Helsinki, 1975. Permission was obtained from the Medical Ethics Committee of our University.

### Doppler examination

All subjects fasted for at least eight hours before the ultrasound (US) examination. Patients were studied with B-mode US in supine or slightly left posterior oblique position by an experienced sonologist who were blind to the report of histology. The measurements were performed during deep suspended inspiration by a 3.5 MHz convex probe with a Siemens Senoline G50 system. The measured parameters included peak portal flow velocity (PPFV), peak systolic velocity (PSV) and end-diastolic velocity (EDV) of hepatic artery at porta hepatis with a Doppler angle between 40 to 60 degree. The hepatic artery resistive index (RI) calculated by the Doppler device, using the following equation:

$$RI = \frac{PSV (cm/s) - EDV (cm/s)}{PSV (cm/s)}$$

was also measured.

The "fibrosis index (FI)," a newly-described index in this article, was evaluated in each case using the following formula:

$$FI = \frac{\text{Hepatic Artery RI}}{PPFV (cm/s)} \times 100$$

### Statistical analysis

Data were confirmed to be normally distributed. Statistical analyses were performed using SPSS version 13.0. The significance of differences between groups was tested by independent *Student's t* test. P-value <0.05 was considered statistically significant. A receive-operating characteristic (ROC) curve was used to determine the best cut-off values of the US parameters for diagnosis of liver cirrhosis.

**Table 1.** Comparison of the mean of RI, PPFV and FI in the chronic hepatitis and cirrhotic patients

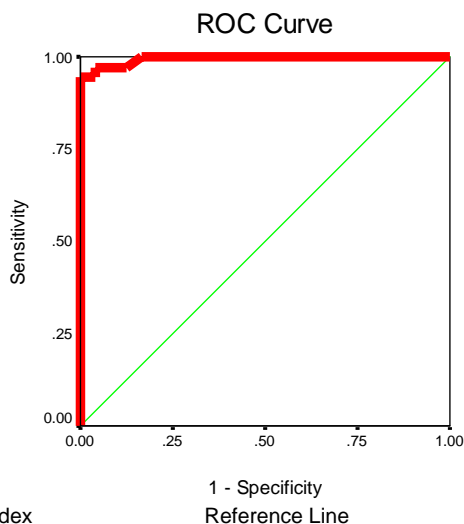
Indexes	Mean±SD (Min-Max)		P-Value
	Chronic Hepatitis	Cirrhosis	
Resistive Index of Hepatic Artery (RI)	0.67±0.03 (0.55-0.72)	0.73±0.04 (0.66-0.83)	<0.0001
Peak Portal Flow Velocity (PPFV)	25.91±4.37 (19.5-38)	14.26±4.10 (7.6-23)	<0.0001
Fibrosis Index (FI)	2.63±0.43 (1.78-3.54)	5.55±1.53 (3.09-9.81)	<0.0001

## Results

Among all patients, 35 (58%) were male and 25 (42%) were female. In the cirrhotic group (n=36), 21 (58%) patients were male while in the chronic hepatitis group (n=24), 14 (58%) were male (p=1). The mean±SD age of cirrhotic patients was 49.2±9.1 (range: 14–70) years. The mean±SD age of those with chronic hepatitis was 36.2±12.1 (range: 16–70) years; the mean age between two groups was significantly different (p<0.0001). The mean±SD age of men was 46.3±13.7 years and of women was 40.9±8.7 years at all (p<0.07).

The results of US measurements of the RI, PPFV and the FI were different between the two groups. The mean values of RI and FI were significantly (p<0.0001) higher in cirrhotic patients than in those with chronic hepatitis. On the other hand, the mean PPFV was significantly (p<0.0001) higher in those with chronic hepatitis than in patients with cirrhosis (Table 1).

For evaluation of the diagnostic efficacy of this newly introduced index, FI for differentiation between cirrhosis and chronic hepatitis, we plotted a ROC curve (Figure 1). Area under the curve of the ROC curve was 0.99 (p<0.0001) (Table2).



**Fig 1.** ROC curve of the FI for differentiation of cirrhosis from chronic hepatitis.

Considering the fact that patients with chronic hepatitis should not be diagnosed as end-stage cirrhosis, the test must not have any false positive values. Therefore, based on the ROC curve, the value of 3.6 was considered as the best cut-off value for the FI in differentiating cirrhosis from chronic hepatitis. According to this cut-off value, FI has a specificity of 100%, a sensitivity of 94.4%, a positive predicative value of 100%, a negative predicative value of 92.3%, and an accuracy of 96%.

## Discussion

Sonography is the first imaging modality to be used in the workup of patients with liver diseases such as viral hepatitis. Nowadays, the gold standard for the diagnosis of liver cirrhosis is histopathologic study of a biopsy specimen. Unfortunately, liver biopsy is associated with the risk of some morbidity and mortality. Therefore, a reliable non-invasive measure which could replace the biopsy would be of paramount importance.

Pervious studies on patients with chronic liver disease, have shown an increase in hepatic artery RI in these patients, which has been thought to be related to the architectural derangement occurs in the liver with increasing severity of the disease. These changes are more prominent in cirrhotic patients.<sup>12-15</sup> In our study, there is also a correlation between the hepatic artery RI value and the presence of cirrhosis.

Although, in some studies, there were no differences in portal flow velocity between cirrhotic and non-cirrhotic patients, Gaiani et al. demonstrated a difference in portal flow velocity between cirrhotic and non-cirrhotic patients; Haktanir et al. found the portal flow velocity as a useful index for the diagnosis of cirrhosis; and Yogesh et al. showed that portal flow velocity among the cirrhotic patients is lower than those with non-cirrhotic chronic liver disease.<sup>16-18</sup> These results are in concordance with ours.

Other studies used other US parameters in differen-

**Table 2.** Trend of sensitivity and specificity in the ROC analysis

Positive if Greater Than or Equal To:	Sensitivity	1 - Specificity
0.7800	1.000	1.000
1.8100	1.000	0.958
2.5250	1.000	0.667
3.1200	0.972	0.125
3.6	0.944	0
4.0600	0.778	0
5.0400	0.583	0
6.0850	0.389	0
7.0000	0.167	0
8.2350	0.056	0
9.3150	0.028	0
10.8100	0.000	0

tiation of cirrhotic patients. Colli et al. reported that US can detect severe fibrosis or cirrhosis with a specificity of 95% and a sensitivity of only 54%.<sup>19</sup> Hung et al. evaluated the validity of US in diagnosis of cirrhosis with a diagnostic sensitivity of 77.5% and a specificity of 92% in patients with hepatitis B.<sup>20</sup> In all of these studies, the sensitivity and specificity of the sonographic parameters were lower than the FI index which is introduced in this study.

According to the high sensitivity, specificity and accuracy of FI, we found it as an appropriate measure for differentiation of liver cirrhosis and chronic hepatitis.

Considering our study settings (including the inclusion and exclusion criteria), we speculate that the external validity of this study could be low. Therefore, to determine the efficacy of FI under various clinical settings, further studies to examine a more heterogeneous group of patients with cirrhosis and chronic hepatitis should be done.

Other limitations of our study were the relatively small number of patients, and the fact that histologic fibrosis scores were not assessed in this study. Therefore, it was impossible to study the correlation between the FI and the severity of the hepatic fibrosis.

In conclusion, FI is an appropriate non-invasive test for the diagnosis of liver cirrhosis and it will decrease the need for liver biopsy in suspected patients. It is also suggested to develop a study to find out the probable correlation between the FI and the degree of liver fibrosis in patients with chronic hepatitis.

## References

- Goe PJ, Mutimer D. Treatment of chronic hepatitis. *Br Med J* 2001; 323: 1164-1167.
- Bravo AA, Sheth SG, Chopra S. Liver biopsy. *N Engl J Med* 2001; 344:495-500.
- Castera L, Negre I, Samii K, Buffet C. Pain experienced during percutaneous liver biopsy. *Hepatology* 1999; 30:1529-1530.
- Cadranel JF, Rufat P, Degos F. Practices of liver biopsy in France: results of a prospective nationwide survey. for the Group of Epidemiology of the French Association for the Study of the Liver (AFEF). *Hepatology* 2000; 32: 477-481.
- Stone MA, Mayberry JF. An audit of ultrasound guided liver biopsies: a need for evidence-based practice. *Hepatogastroenterology* 1996; 43: 432-434.
- Thampanitchawong P, Piratvisuth T. Liver biopsy: complications and risk factors. *World J Gastroenterol* 1999; 5: 301-304.
- Cosgrove DO, Blomley MJK, Eckersley RJ. Ultrasound of the liver and biliary tract In: Blumgart L, Fong Y, eds. *Surgery of the liver and biliary tract*. 3rd ed. London, England: Saunders 2000: 227-269.
- Bolondi L, Gaiani S, Barbara L. Liver and portal hypertension In: Taylor KJW, Burns PN, Wells PNT. *Clinical applications of Doppler ultrasound*. 2nd Ed. New York, NY: Raven Press, 1995:133-154.
- Vilgrain V. Ultrasound of diffuse liver disease and portal hypertension. *Eur Radiol* 2001; 11:1563-1577.
- Bernatik T, Strobel D, Hahn EG, Becker D. Doppler measurements: a surrogate marker of liver fibrosis? *Eur J Gastroenterol Hepatol* 2002; 14: 383-387.
- Hirata M, Akbar SM, Horiike N, Onji M. Noninvasive diagnosis of the degree of hepatic fibrosis using ultrasonography in patients with chronic liver disease due to hepatitis C virus. *Eur J Clin Invest* 2001; 31: 528-535.
- Piscaglia F, Gaiani S, Calderoni D, Donati G, Celli N, Gramantieri L et al. Influence of liver fibrosis on hepatic artery Doppler resistance index in chronic hepatitis of viral origin. *Scand J Gastroenterol* 2001; 36: 647-652.
- Walsh KM, Leen E, MacSween RN, Morris AJ. Hepatic blood flow changes in chronic hepatitis C measured by duplex Doppler color sonography: relationship to histological features. *Dig Dis Sci* 1998; 43: 2584-2590.
- Piscaglia F, Gaiani S, Zironi G, Gramantieri L, Casali A, Siringo S et al. Intra- and extra hepatic arterial resistances in chronic hepatitis and liver cirrhosis. *Ultrasound Med Biol* 1997; 23: 675-682.
- Sacerboti DS, Merkel S, Bolognes M. Hepatic arterial resistance in cirrhosis with & without portal vein thrombosis and correlation with portal hemodynamic. *Gastroenterology Instituto dimeticin clinic university of Podava: Italy* 1992; 108(4):1152-1158.
- Gaiani S, Gramantieri L, Venturoli N, Piscaglia F, Siringo S, D'Errico A, Zironi G, Grigioni W, Bolondi L. What is the criterion for differentiating chronic hepatitis from compensated cirrhosis? A prospective study comparing ultrasonography and percutaneous liver biopsy. *J Hepatol* 1997; 27: 979-985.
- Haktanir A, Cihan BS, Celenk C, Cihan S. Value of Doppler sonography in assessing the progression of chronic viral hepatitis and in the diagnosis and grading of cirrhosis. *J Ultras Med* 2005; 24(3): 311-321.
- Chawla Y, Radha S, Dhiman Jang K, Dilawari B. Portal hemodynamics by duplex Doppler sonography in different grades of cirrhosis. *Digestive Disease and Sciences* 198; 43(2): 354-357
- Colli A, Fraquelli M, Andreoletti M, Marino B, Zuccoli E, Conte D. Severe liver fibrosis or cirrhosis: accuracy of US for detection--analysis of 300 cases. *Radiology* 2003; 227: 89-94.
- Hung CH, Lu SN, Wang JH, Lee CM, Chen TM, Tung HD et al. Correlation between ultrasonographic and pathologic diagnoses of hepatitis B and C virus-related cirrhosis. *J Gastroenterol* 2003; 38: 153-157.