

A. M. Kajbafzadeh MD,¹
M. Mehdizadeh MD.²

Hook Phenomenon Intermittent distal ureteral obstruction following reimplantation

Background/Objectives: To evaluate the child with intermittent ureteral obstruction following antireflux surgery and to introduce a new imaging technique for diagnosis of the so-called "hook" phenomenon, the most serious complication of antireflux surgery.

Patients and Methods: Twenty-five children with a history of antireflux surgery who were referred for either persistent urinary tract infection (UTI) or progressive hydronephrosis were included in the study. All the children with signs and symptoms of voiding dysfunction or persistent reflux were excluded.

A new imaging technique was devised to evaluate these patients for the presence of "hook phenomenon", in which a renal ultrasound was performed both on a full bladder and after voiding. If dilatation of the urinary tract was detected on full bladder, and this dilatation decreased dramatically following micturition, then a catheter was passed into the bladder and was filled with normal saline (based on the estimated bladder capacity in order to avoid over-distension). An intravenous urogram and saline cystogram were performed simultaneously. After 20 minutes, 2 abdominal radiographs were obtained on full and emptied bladder, both.

Results: On the intravenous urogram, some children showed typical "J- hook-shaped" ureters. In all the cases marked hydronephrosis was noted, with no contrast material seen entering the bladder on the 20 minute radiogram. Upon evacuation of the bladder, both ureters promptly drained into the bladder and the "J-hooking" of the ureters and hydronephrosis resolved.

Conclusion: "J- hook phenomenon" is one of the most common causes of hydronephrosis and hydroureter following ureteral re-implantation is intermittent ureteral obstruction from creation of the new ureteral hiatus at an inappropriate site. This complication is frequently misdiagnosed as irreversible uretero-vesical junction obstruction from ischemia or fibrosis. Once the diagnosis of "J- hook" phenomenon is confirmed, early ureteral reimplantation with creation of a new hiatus is the treatment of choice.

Keywords: Reflux, Ureter, Reimplantation, Complications, Surgery

Introduction

Vesico-ureteral reflux (VUR) occurs in 0.5 -18.5 percent of neurologically intact children with no history of a symptomatic urinary tract infection.^{1,2} It is seen in approximately 30-50 percent of children with neuropathic bladder disease.³ The incidence of VUR in children with a single episode of UTI is over 50 per cent⁴ and its management remains controversial. In those pediatric patients with intact bladder function, the success rates for anti-reflux procedures range from 95 to 98 percent when performed by experienced surgeons.^{5,6} The complication rate is higher in those with bladder dysfunction, secondary to posterior urethral valve, and neuropathic or non-neurogenic bladder dysfunction; and may rise from a range of 5 to 10 percent to a range of 30 per cent, and even higher when performed by a less experienced surgeon. Ureteral obstruction is considered the most important complication of anti-reflux surgeries.⁷ The basic surgical principles for prevention of ureteral obstruction are: a) gentle handling of the ureter, b) avoiding angulation of the ureter around the extravescical structures, c) securing the ureter to the immobile (less distensible) portion of the posterior bladder wall, to prevent angulation of the ureter by a full bladder,

From

1. Departments of Pediatric
Urology, Children's Hospital
Medical Center, Teheran University
of Medical Sciences, Teheran, IRAN

2. Departments of Pediatric
Radiology, Children's Hospital
Medical Center, Teheran University
of Medical Sciences, Teheran, IRAN

Corresponding Author:

Dr Kajbafzadeh,

No. 36, 2nd floor, 7th St.

SAADAT-ABAD Ave. Tehran -
19987, IRAN

Tel: +9821 208 9946,

Fax: +9821 2069 451,

E-mail: kajbafzd@sina.tums.ac.ir

and d) ensuring that the muscular hiatus or submucosal tunnel does not constrict or kink the ureter.

If the new hiatus is placed either too high, or too far laterally (relative to distensible portion of the bladder), "J-hooking" phenomenon will occur by a full bladder.

Therefore, the presence of an obstruction at the completion of re-implantation cannot be ruled out merely by the easy negotiation of a catheter through the ureteral orifice, simply because an empty bladder would not create a "J-hook" type of ureteral obstruction. This complication may result from virtually any one of surgical techniques that require creation of a new hiatus 8. Urinary obstruction caused by "J-hook" phenomenon is often suggested by demonstration of hydronephrosis on post-operative ultrasound. When the child presents with prolonged abdominal or flank pain, unexplained ileus, a palpable flank mass, symptomatic urinary tract infection, diminished urinary output or rising serum creatinine values, an intermittent ureteral obstruction must be suspected. Under these circumstances, our proposed imaging technique may enable the surgeon to arrive at an early diagnosis.

Patients and Methods

Our patient population consisted of 25 children who had undergone some type of anti-reflux surgery and referred for further management.

All the patients took a general physical examination, had a voiding diary (frequency volume chart), gave a urinalysis and urine culture, underwent a voiding cystogram to rule out reflux (by the referral

physician), urinary tract ultrasound on a full bladder and following micturition, a simultaneous saline cystogram and an intravenous pyelogram, a ⁹⁹Tc DTPA scan on a full bladder and following bladder drainage, a natural fill urodynamics study and a rectal line in situ.

Our imaging protocol consists of an ultrasound of the entire urinary tract on a full bladder, measurement of the antero-posterior diameter of the renal pelvis and the urinary bladder and also the diameter of the distal ureters both on a full and an empty bladder. All of these children, who showed hydronephrosis on post operative ultrasound of the bladder (full and empty), were suspected of having "J-hook" phenomenon of the ureter.

Major criteria for exclusion from the study were abnormal urodynamic findings or persistent vesico-ureteral reflux.

Our imaging protocol consisted of a complete ultrasound of the entire urinary tract with the bladder full and empty, measurement of the antero-posterior diameter of the renal pelvic, and also diameter of distal ureters both when the bladder was full and when empty. The diagnosis of "hook phenomenon" was established by prompt decompression of the dilated collecting system and ureters upon evacuation of the bladder (Figure 1). To further confirm this impression, an intravenous urogram was performed when the bladder was saline-filled and emptied. The capacity of the bladder was measured based on the formula: (age in years +2) × 30 cc. As soon as the child expressed discomfort, even before reaching the estimated bladder volume, infusion of normal saline was discontinued.

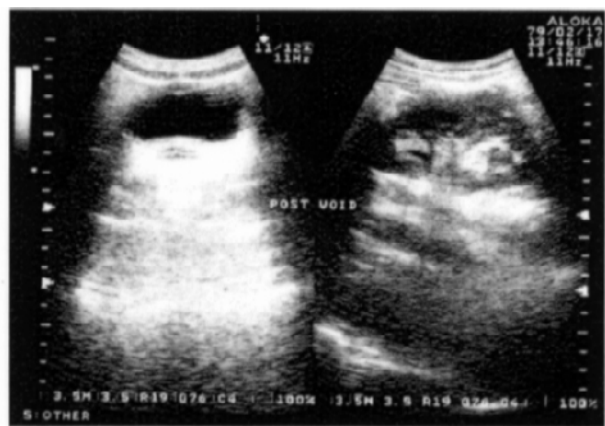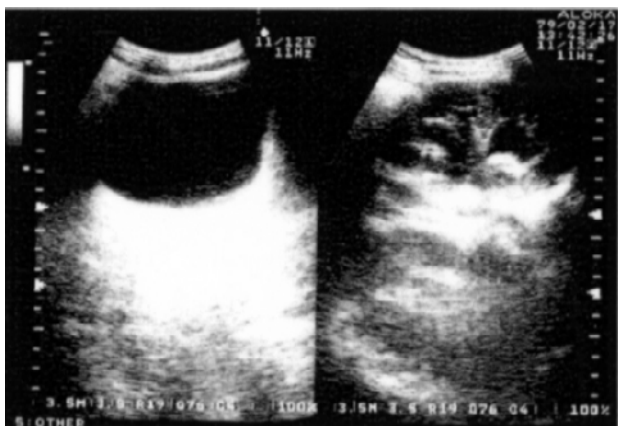


Figure 1: Urinary ultrasound in Hook phenomenon. A) On full bladder. Note hydronephrosis of the urinary tract B) Following bladder emptying. The hydronephrosis is completely obviated.

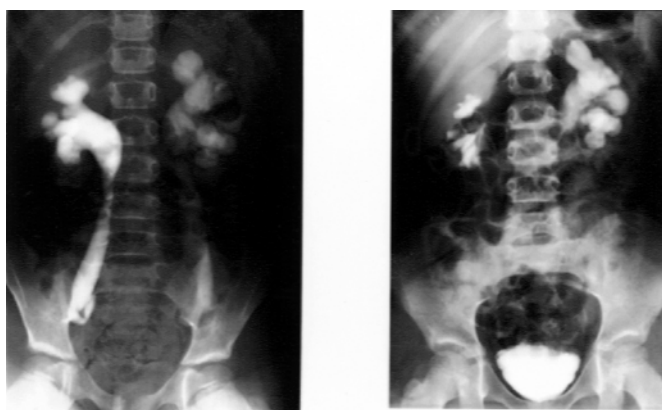

Figure 2: Saline cystogram and IVU A) Note the hook-shaped ureter and no entrance of contrast media into the bladder. B) After urination the hook-shaped ureter disappeared and contrast media entered the bladder.

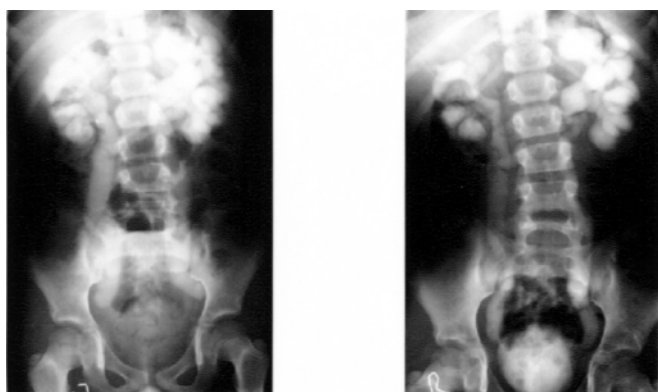
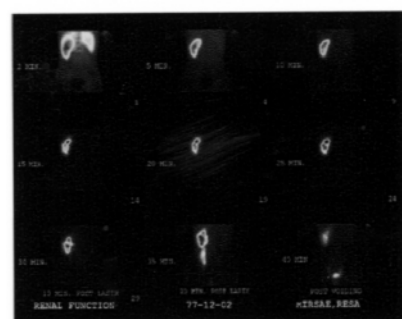
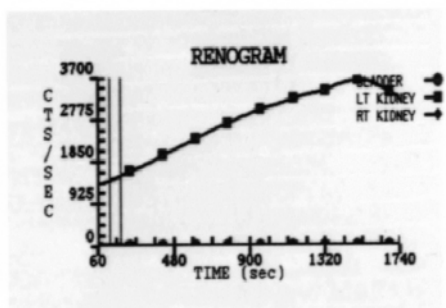


Figure 3: Saline cystogram in patient with hook phenomenon A) Note marked dilatation without a hook-shaped ureter and no entrance of the contrast media into the bladder. B) After urination, hydronephrosis decreased markedly and contrast media entered the bladder.

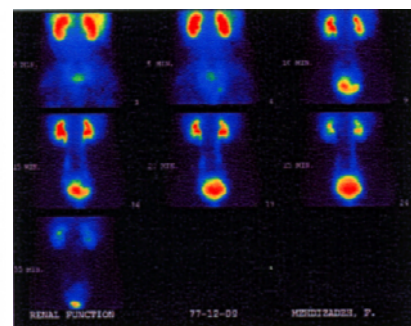
A second group of pediatric patients (n=10), who had undergone an anti-reflux surgery utilizing Gil-Vernet technique (without creation of a new muscular hiatus) 9, were also evaluated using the above mentioned imaging technique.



A



B



C

Figure 4: A) Combined saline cystogram and a diuretic renal scan in a child with a history of right nephrectomy and left ureteral reimplantation, demonstrates no wash-out of the radiopharmaceutical with the bladder was full. Note the good drainage following bladder emptying. B) Renal scans curves. Note no radiopharmacy in the full bladder. C) Normal renal scans on full bladder. Note the radiopharmacy in the bladder after a few seconds

Results

On the intravenous urogram of the saline-filled bladder, stasis of the contrast material was noted as a result of “J-hook” phenomenon. Upon evacuation of the bladder, the dilated ureters resumed normal course and caliber (Figure 2 and 3). In order to avoid the dilution effect of the contrast material, a potential pitfall in diagnosis of the obstruction, a ^{99m}Tc - DTPA diuretic renal scans was performed. A ^{99m}Tc - DTPA scan was done after filling the bladder to capacity.

The post-diuretic renal scan demonstrated immediate wash-out of the radiotracer in the control group. But, there was no radiotracer wash-out 20 minutes after injection of Furosemide in the patient group, unless the bladder was evacuated (Figures 4 and 5). The gold standard of the diagnosis was the intra-operative confirmation during surgical reconstruction.

“Hook” phenomenon was confirmed in all the studied 25 children. Narrowing of the distal third of the ureter was noted on IVU, when the bladder was full, a finding also seen during cystoscopy. When the bladder was emptied, the ureteral orifices returned to normal, and a catheter would easily be negotiated through the orifice, which was not the case with a full bladder. According to the discharge notes, two cases had a previous Cohen anti-reflux surgery, and the remaining 23 cases that had been treated with Politano-Leadbetter technique, showed typical “J-hook” phenomenon of the ureters.

In the 10 patients who had undergone Gil-Vernet technique⁹ (mentioned earlier in the patients and methods above) we were unable to find any ureteral obstruction. The only reason for evaluation of this group of children was recurrent urinary tract infection without hydronephrosis. There was no “J-hook” phenomenon seen in this group of patients.

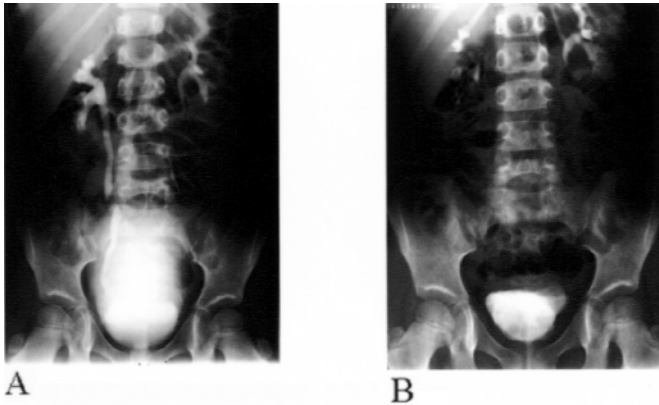


Figure 5: Combined saline cystogram and IVU in a normal volunteer, A, note contrast media in saline full bladder a few minutes after contrast injection, mild ureteral stasis without hydronephrosis

Discussion

During the first few months of anti-reflux surgery the degree of upper tract dilatation should not exceed that of the preoperative voiding cystourethrogram. When an obstruction is suspected, full and emptied bladder ultrasound should be obtained to assess the presence of obstruction from a "J-hook" phenomenon. In this clinical setting, a ^{99m}Tc DTPA renal scan will be necessary. Should this test show a diminished or prolonged excretion on a full bladder and a good wash-out when bladder is empty, an intravenous urogram is not necessary, unless the ^{99m}Tc DTPA renal scan is equivocal.

In order to reduce the potential risk for development of "J-hook" phenomenon during an anti-reflux surgery; it is imperative to bring the ureter through a new muscular hiatus, not too far up, down or lateral relative to the bladder wall as originally emphasized by Politano and Leadbetter.¹⁰ Furthermore, the ureter should be secured to the less distensible portion of the bladder, so as not to form an angle when the bladder fills up. Various surgical procedures have been used in these children for correction of uretero-vesical junction obstruction, such as insertion of a double-J ureteral stent, cutaneous ureterostomy, nephrostomy, trans-uretero-ureterostomy etc. More severe cases of obstruction particularly those associated with "J-hooking" of a ureter through the peritoneum, will require exploration and reimplantation.

There are rare reported cases that the ureter was brought up through the peritoneum or bowel wall.¹¹ The complication rate from this technique ranges from 5-10 per cent to 10-30 per cent in those children with bladder dysfunction, particularly when ureteral tapering and reimplantation become necessary.⁷ The complication rate may be even higher when the surgery is done by a surgeon who not regularly performs anti-reflux procedures in children. Preservation of the anatomical integrity in every type

of anti-reflux surgery is crucial if one has to avoid the occurrence of "J-hook" phenomenon.

Ureteral obstruction must be suspected when hydronephrosis persists for more than 3 months of anti-reflux surgery, especially in a symptomatic child or one with diminished renal function. These children may require nephrostomy to decompress the kidneys especially if the hydronephrosis does not respond to the bladder free drainage. Once the child becomes stable and the urinary tract infection is under control, an antegrade pyelography (nephrostomography) with the bladder filled and emptied is carried out to identify the site and type of obstruction. If the obstruction persists even after emptying the bladder, then a true uretero-vesical junction obstruction is diagnosed and reoperation is contemplated.

The incidence of reoperation for uretero-vesical junction obstruction ranges from 1.2 to 4 per cent. If the ureteral orifice has been created too far up and too far laterally the incidence of obstruction is higher.⁷ Selecting a more medial hiatus along the posterior less distensible portion of the bladder prevents kinking and "J-hooking" of the ureter. The most challenging cases are those asymptomatic patients with persistent post-operative hydronephrosis. Under these circumstances, concurrent IVU and saline cystogram, radiograph will usually show hydronephrosis and hydroureter. A post-voiding radiograph will show disappearance of hydronephrosis.

Intermittent uretero-vesical obstruction, as a result of angulation of the ureter, develops as the bladder begins to fill. In these circumstances, a diuretic ^{99m}Tc DTPA renal scan, done on an empty bladder, may not show obstructed. Other investigators have recommended an antegrade pyelogram combined with gradual filling of the bladder, during which the ureter will reveal a kink at the site of new ureteral hiatus and hence progressive ureteral dilatation. However, this procedure seems to be more invasive than our technique. This type of obstruction usually does not occur with Cohen's technique, unless the ureteral hiatus is moved to a new position.

In conclusion, all patients with apparently successful anti-reflux surgery need to be followed up for at least 5 further years for potential late complications.

Selecting a more medial location for the ureteral hiatus along the less expansible posterior portion of the bladder will prevent kinking and hooking of the ureter as was originally described by Politano and Leadbetter in 1958.¹⁰ Preservation of anatomical integrity in every anti-reflux surgery is essential for preventing the "J-hook" phenomenon.

References

1. Ransley PG .Vesico-ureteral reflux: Continuing surgical dilemma. *Urology* 1978; 12:246-250.
2. Kollerman VWM.Uiberbewertung Der Pathogenetischen Bedeutung Des Vesiko-Ureteralen Refluxes Im Kindesalter. *Z Urol* 1974; 67:573.
3. Bauer SB. Vesico-ureteral reflux in children with neurogenic bladder dysfunction. In: Johnston JH (Ed.), *International Prospective in Urology*, Baltimore: Williams & Wilkins, Vol. 10 1984: pp 159-177.
4. International Reflux Study Committee: Medical versus surgical treatment of primary vesico-ureteral reflux. *Pediatrics* 1981; 67: 392-400.
5. Weiss R, Duckett, J, Spitzer A. On behalf of the International Reflux study in Children: Results of randomized clinical trial of medical versus surgical management of infants and children with grade III and IV primary vesico-ureteral reflux (United States Branch). *J Urol* 1992; 148: 1667.
6. Hjalmas K, Lohr G, Tamminen-Mobius T.et al: Surgical results in the International reflux study in children (Europe).*J Urol* 1992; 148:1657.
7. Mesrobian HGJ, Kramer SA and Kelalis PP: Reoperative ureteroneocystostomy: review of 69 patients. *J Urol* 1985; 133:388.
8. Atala A, Keating MA: Vesico-ureteral reflux and megaureter "Late complication of ureteral reimplantation". In:Walsh, PC, Retic AB, Vaughan ED, Wein AJ: *Campbell's Urology*, 8th ed. Philadelphia. W.B. Saunders Co. 2002:2090-2091,
9. Gil-Vernet JM: New technique for surgical correction of vesicoureteral reflux. *J Urol* 1984; 131:456.
10. Politano VA ,Leadbetter WF. An operative technique for the correction of vesicoureteral reflux. *J Urol* 1958; 79:932.
11. Tocci PE, Politano VA, Lynne CM et al. Unusual complications of transvesical ureteral reimplantation. *J Urol* 1976; 115. 731.