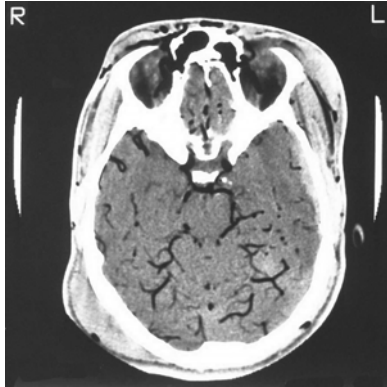
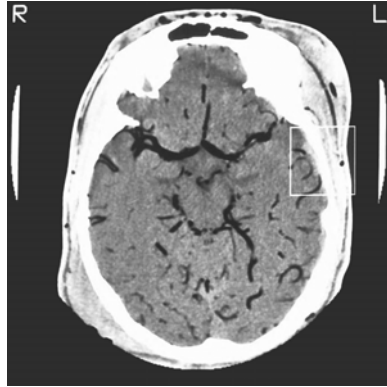


## PHOTO QUIZ

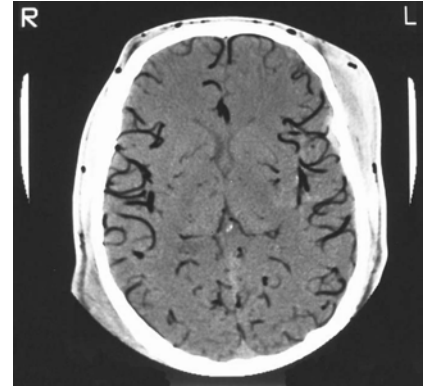
### What Is Your Diagnosis?



*Figure 1* - Axial CT scan without contrast at sellar level



*Figure 2*- The same patient's CT scan at paraventricular level



*Figure 3*- The same patient's CT scan at mid-brain level

A 25-year-old man was admitted to the emergency room after a car crash on his way home. On admission, the patient was in deep coma, had a pulse rate of 84 and BP of 120/60 mmHg. An emergency brain CT scan without IV contrast was obtained of which three sections are shown above: In spite of hyperbaric oxygen therapy, the patient expired two hours after admission.

## Diagnosis: Massive Cerebral Vascular Air Embolism

Prepared by: M. Taghipour MD, B. Zamani MD and F. Zare MD

Department of Neurosurgery (M.T. and B.Z.) and Radiology (FZ) Shiraz University of Medical Sciences.

*Figure 1-* Sellar level Image shows diffuse air filling within the arteries of the circle of willis, middle and posterior cerebral arteries and subcutaneous extracranial veins. There is also a right posterior occipital subgaleal hematoma, and air in orbital vessels.

*Figure 2-* Same pattern at the brain stem level showing air in ACA, cisternal vessels, frontal subcutaneous emphysema and presence of air in the veins, together with the left frontal subgaleal hematoma.

*Figure 3-* Para-ventricular level, air in cisternal arteries and angular cortical branches of M.C.A. There is also air in subcutaneous veins and left fronto-temporal and right occipital subgaleal hematomas.

These two sections of brain CT scan show widespread hypodensities in cerebral vessels of both hemispheres. Findings are consistent with massive cerebral arterial air embolism. A small epidural hematoma is also present in the left temporal area.

Autopsy was not performed but the cause of the death was felt to be due to sudden severe cardiovascular collapse due to massive systemic arterial air embolism and/or severe cerebral hypoxia.

Air embolism is divided into two categories; venous and arterial.

Venous air embolism usually occurs in pulmonary vasculature causing impairment of gas exchange, pulmonary hypertension and sometimes heart failure<sup>1</sup>.

Systemic arterial air embolism, however, is a life threatening condition which occurs more frequently in open heart surgery<sup>2</sup>, but can occur also in other conditions such as decompression sickness, left ventriculography<sup>3</sup>, and penetrating or blunt chest trauma<sup>4</sup>.

Systemic arterial air embolism can occur in any part of the body causing varying degrees of damage depending on the amount of air and the rate of entering the systemic circulation, the organ supplied by the blocked artery<sup>5</sup> and also the time taken to

make the diagnosis and to begin the appropriate treatment.

Arterial air embolism following chest trauma, which was the case in our patient, is due to a pulmonary bronchovenous fistula<sup>6</sup>. The process is initiated by the passage of air from the bronchial tree to the pulmonary venous system, on account of the bronchopulmonary pressure gradient<sup>9</sup>.

Chest CT-Scan and transesophageal echocardiography are valuable methods in early diagnosis of this condition<sup>7,8</sup>. Immediate thoracotomy for hilar cross-clamping of the pulmonary vessels, or interruption of ventilation of the involved lung are life saving maneuvers<sup>9</sup>.

### References:

1. Brubakk Ao, Vik A, Flook V. Gas Bubbles and the lungs. In: lundgren CEG, Miller JN, eds. The lung at depth. New York:Marcell Dekker , 1999: 237-94.
2. Tascano M, Chiaravelli R, Ruvolo G, Macchivelli A, Scibilia G, Marino B. Management of air embolism during open heart surgery with retrograde perfusion of cerebral vessels and hyperbaric Oxygenation. Thoracic Cardiovas Surg, 1983; 31, 18-24.
3. Goldenberg I, Shupaic A, Shoshani O, Bovlos M. Left ventriculography complicated by cerebral air embolism. Israel naval medical institute, IDF medical corps,Haifa,. Cathet Cardiovascular Diagn (US) 1995; 35:331-4
4. Sauda R, Goarin JP, Roubly JJ, Jaquens Y, Guesda R, Viars P. Systemic gas embolism complicating pulmonary contusion: Diagnosis and management using transesophageal echocardiography. Am J Respir Circl care med. 1995; 152: 812-5
5. El-Halabi A, Botras A, Nowacka E. Massive systemic air embolism following a blunt chest injury.
6. Meir GH, Wood WJ, Symbas PN. Systemic air embolism from penetrating lung injury. Ann Thoracic Surg 1979; 27:161.
7. Graham Jm, Beal AC,Mattox KL, Vaughn GD. Systemic air embolism following penetrating trauma to the lung. Chest 1979; 72: 449.
8. Oka Y, Inouo T, Hong Y, Sisto Da, Storm Ja, Frater RW. Retained intracardiac air: Transesophageal echocardiogram for detection of venous air embolism. J Anaesthet 1995; 75: 447-50.
9. Honowell Lh. Perioperative management of thoracoabdominal trauma. In: Grande Cm, editor. Textbook of trauma, Anesthesia & critical care. St loius, Missori. Mossby year book Inc, 1993: 559-82.