



# The Therapeutic Efficacy of Antegrade Balloon Aortic Valvuloplasty under Intra-aortic Balloon Pumping for Treating Cardiogenic Shock due to Critical Aortic Valve Stenosis

Yasushi Hirano<sup>1,2,\*</sup>, Yoshihito Sakata<sup>1</sup>

<sup>1</sup>Department of Cardiology, Ikegami General Hospital, Tokyo, Japan

<sup>2</sup>Department of Cardiovascular Medicine, Juntendo University Graduate School of Medicine, Tokyo, Japan

## ARTICLE INFO

*Article Type:*  
Research Article

*Article History:*  
Received: 23 Jul 2016  
Accepted: 04 Jan 2017

*Keywords:*  
Shock  
Cardiogenic  
Hemodynamics  
Atrial Pressure

## ABSTRACT

**Background:** Treatment of critical Aortic Stenosis (AS) in hemodynamically unstable patients is a major clinical challenge.

**Objectives:** This study aimed to retrospectively investigate the safety of antegrade Balloon Aortic Valvuloplasty (BAV) using the Inoue balloon and an Intra-Aortic Balloon Pump (IABP) for treating AS with cardiogenic shock and to determine the immediate efficacy of the procedure with respect to hemodynamic improvements in patients with critical symptomatic AS.

**Patients and Methods:** This retrospective study was conducted on 47 symptomatic critical AS patients excluded from undergoing surgical aortic valve replacement who were treated using antegrade BAV. The high-risk group included 14 cases whose mean Left Atrial Pressure (LAP) remained above 25 mmHg despite aggressive medical therapy. These cases were treated using antegrade BAV and an IABP (BAV-IABP group). On the other hand, 33 cases with stable hemodynamics due to medications comprised the relatively low-risk group and were treated using antegrade BAV alone (BAV-alone group).

**Results:** Immediate procedural success was achieved in all cases within 24 h. In the BAV-IABP group, the proportion of patients with improved aortic valve areas ( $125.6 \pm 56.7\%$  vs.  $70.9 \pm 32.3\%$ ,  $P < 0.004$ ), reduced pressure gradients ( $67.8 \pm 9.1\%$  vs.  $59.6 \pm 17.2\%$ ,  $P < 0.040$ ), and decreased LAP ( $48.4 \pm 15.4\%$  vs.  $17.9 \pm 9.9\%$ ,  $P < 0.001$ ) was significantly larger compared to the BAV-alone group.

**Conclusions:** Antegrade BAV under IABP provided safe and effective immediate valvuloplasty in very high-risk patients who were not suitable for definitive therapy.

## 1. Background

Management of cardiogenic shock caused by critical Aortic Stenosis (AS) is clinically challenging, and affected patients have dismal prognoses. Thus, it is important to relieve AS mechanically. However, surgical Aortic Valve Replacement (AVR) and Transcatheter Aortic Valve Implantation (TAVI) are poorly tolerated in patients with cardiogenic shock because of their labile hemodynamic statuses, profound myocardial compromise, and poor functional reserves in the left ventricle and other vital organs. In comparison to conventional retrograde BAV, antegrade Balloon Aortic Valvuloplasty (BAV) utilizing the Inoue balloon improves

the immediate post-BAV Aortic Valve Area (AVA) (1). The advantages of antegrade BAV over the conventional retrograde approach include its overflow to crossing the aortic valve, reduced risk of Left Ventricular (LV) perforation, decreased bleeding-related risk, decreased embolization of debris by minimal arterial access, and compatibility with the simultaneous use of an Intra-Aortic Balloon Pump (IABP) in the aorta (2). Furthermore, the “dumbbell”-shaped Inoue balloon has rapid inflation and deflation cycles, enabling stepwise inflations with durable multiple inflations. Indeed, it can be securely positioned because of its unique inflation pattern (3). Although antegrade BAV is a useful approach, it remains challenging under hemodynamically unstable conditions and can result in fatal consequences (4). Systolic Blood Pressure (BP) must be maintained during the procedure by administering

\*Corresponding author: Yasushi Hirano, Department of Cardiology, Ikegami General Hospital, 6-1-19 Ikegami, Ohta-ku, Tokyo, 146-8531, Japan, Tel: +81-33752-3151, Fax: +81-34752-2612, E-mail: yasushihirano7@gmail.com

positive inotropic agents, but this often causes further elevations of the mean Left Atrial Pressure (LAP), which results in worsening pulmonary edema. Hence, it is often difficult to stabilize a patient's hemodynamic status using inotropic agents. To achieve successful valvuloplasty under these grave conditions, antegrade BAV can be performed with additional hemodynamic support. In this context, placement of an IABP is vitally important because it augments vital organs perfusion and controls intracardiac pressure (5).

In the present study, antegrade BAV with the Inoue balloon was used in combination with an IABP to treat critical AS with cardiogenic shock.

## 2. Objectives

This study aims to investigate the safety of antegrade BAV retrospectively and to determine the immediate efficacy of antegrade BAV with IABP regarding hemodynamic improvements in patients with critical symptomatic AS.

## 3. Patients and Methods

### 3.1. Subjects

Consecutive patients with severe AS who presented with active cardiovascular symptoms and were treated with antegrade BAV because of contraindications for surgical AVR or TAVI between October 2006 and March 2013 were screened (6). Each case was thoroughly discussed with our cardiothoracic surgery team in terms of risks and possibilities of surgical AVR or TAVI. Among these patients, only those who had critical AS, which was determined using an echocardiographic two-dimensional plane metric evaluation that confirmed an AVA of  $\leq 0.75$  cm<sup>2</sup>, and whose hemodynamic data were available during and after the procedures were included in this study. With respect to hemodynamic data, LAP is one of the most sensitive indicators of hemodynamic severity and it can be monitored during antegrade BAV. All eligible patients were then divided into two groups. The BAV-IABP group comprised patients who were profoundly hemodynamically compromised (defined as a systolic BP of  $< 80$  mmHg and a mean LAP of  $\geq 25$  mmHg with administration of positive inotropic agents). These patients were treated with antegrade BAV under IABP support. On the other hand, the BAV-alone group comprised patients whose hemodynamic statuses were relatively stable (defined as a systolic BP  $\geq 80$  mmHg that was achieved without using the maximum doses of positive inotropic agents and a mean LAP that was maintained at  $< 25$  mmHg). The patients' baseline characteristics, comorbidities, certainty of therapeutic efficacy, and immediate outcomes with respect to their hemodynamic parameters after antegrade BAV were compared.

The study protocol was approved by the Ethics Committee of Ikegami General Hospital (Number 2014S - 8, April 23, 2014). The participants provided informed consents, and the authors conformed to institutional guidelines and those of the American Physiological Society.

### 3.2. Antegrade Balloon Aortic Valvuloplasty

The right femoral vein was pre-closed using percutaneous

closure and the Proglide® device (Abbott Vascular, Illinois, USA), and a 14-Fr sheath was placed. The femoral artery was similarly pre-closed using the Proglide® device in preparation for placement of a 7.5-Fr IABP (USCI, Tokyo, Japan). The untied suture knots were closed when the devices were removed at the end of the procedure to obtain complete hemostasis (7, 8). A Mullins sheath was inserted into the Left Atrium (LA) via a transseptal puncture. Then, a balloon-tipped wedge catheter was advanced from the LA to the left ventricle and was passed over the Inoue coil-tipped wire to create an intra-ventricular loop. The wedge catheter was further advanced across the aortic valve and over the aorta in an antegrade fashion down into the descending aorta. A 0.032-inch stiff wire (Cook Medical, Indiana, USA) was placed into the descending aorta through the inner lumen of the balloon catheter, and a 5-Fr long sheath was placed using any other arterial access to monitor the BP and to deliver the 10-mm goose neck snare to hold the 0.032-inch wire in place. After creating this wire loop that spanned from the right femoral vein across the aortic valve and into the descending aorta, the Inoue balloon was advanced over the wire from the right femoral vein and across the aortic valve where balloon inflations were performed (6). The diameter of the aortic valve annulus was measured in advance at the junction of the LV outflow tract and the aortic valve using a long-axis view of a two-dimensional echocardiogram. This value was utilized to guide the final size of the balloon inflation. Valvuloplasty was performed by applying multiple manual inflations with stepwise increases in balloon size up to the measured diameter of the annulus. Burst pacing (200 beats/minute for less than 2 seconds) was applied as needed in order to stabilize the position of the balloon during inflation (9). Additional valvuloplasty was repeated in case of insufficient improvement in hemodynamic parameters after prior multiple manual inflations.

### 3.3. Measurements

Hemodynamic parameters associated with the procedures, including mean LAP, transvalvular Pressure Gradients (PGs), and AVA over BAV, were measured. After transseptal puncture, aortic and LV pressures were measured simultaneously to compute the mean transaortic valve PG (LV-Ao PG). Additionally, AVA was calculated based on the Gorlin formula using the mean LV-Ao PG and the cardiac output. It should be noted that AVA, PG, and LAP measurements were repeated following the BAV procedures.

### 3.4 Statistical Analysis

The data were expressed as mean  $\pm$  Standard Deviation (SD) for continuous variables and as percentage for categorical ones. The characteristics of the two groups were compared using student t-test for normally distributed continuous variables and chi-square test for categorical ones. Student t-test was also used to compare the variables before and after BAV procedures. All statistical analyses were performed using IBM® SPSS® software, version 22 (IBM Corporation, Armonk, NY). Besides,  $P < 0.05$  was considered to be statistically significant.

#### 4. Results

Between October 2006 and March 2013, 405 patients were treated using antegrade BAV. Among these patients, 47 were eligible for analysis, including 14 hemodynamically compromised patients in the BAV-IABP group and 33 patients with stable hemodynamic statuses at baseline in the BAV-alone group. No deaths occurred in either group during and within 24 h following the procedures. Post-procedural echocardiography also revealed no severe residual shunts in the two groups. In the BAV-IABP group, there were no major IABP-related complications. Additionally, intra-aortic balloon pumping was discontinued and the IABP was removed immediately after the BAV procedures in 11 out of the 14 cases. In the three remaining cases, the IABP was removed within 24 h following the procedures.

The clinical characteristics of the patients and their hemodynamic parameters before BAV have been presented in Table 1. The results showed no significant differences between the BAV-IABP and BAV-alone groups with respect to age and sex distribution. Considering the patients' baseline statuses before BAV, the mean LV ejection fraction was significantly lower in the BAV-IABP group compared to the BAV-alone group ( $26.0 \pm 12.0\%$  vs.  $59.6 \pm 11.8\%$ ,  $P < 0.001$ ). In terms of hemodynamic parameters before BAV, AVA was significantly smaller in the BAV-IABP group than in the BAV-alone group ( $P < 0.001$ ). There was a trend toward higher PG before BAV in the BAV-alone group compared to the BAV-IABP group, but the difference was not statistically significant ( $P = 0.073$ ). Moreover, the mean

LAP before BAV was significantly higher in the BAV-IABP group compared to the BAV-alone group ( $P < 0.001$ ).

The patients' comorbidities have been presented in Table 2. Accordingly, the patients in the BAV-IABP group were more likely to have end-stage renal disease requiring hemodialysis (21.4%), pulmonary hypertension (21.4%), and infectious diseases (28.6%).

##### 4.1. Changes in Hemodynamic Parameters Following Balloon Aortic Valvuloplasty

Changes in individual catheter-derived hemodynamic parameters following BAV procedures have been shown in Figure 1. Immediately after BAV, AVA improved significantly in both groups. Yet, the percentage of increase in AVA was much greater in the BAV-IABP group compared to the BAV-alone group ( $125.6 \pm 56.7\%$  vs.  $70.9 \pm 32.3\%$ ,  $P = 0.004$ ) (Figure 1A). Moreover, statistically significant reductions occurred in transvalvular PG following BAV in both groups. Nonetheless, the percentage of reduction in transvalvular PG was much greater in the BAV-IABP group in comparison to the BAV-alone group ( $67.8 \pm 9.1\%$  vs.  $59.6 \pm 17.2\%$ ,  $P = 0.04$ ) (Figure 1B). Furthermore, the mean LAP decreased significantly in both groups, but the percentage of reduction was significantly greater in the BAV-IABP group than in the BAV-alone group ( $48.4 \pm 15.4\%$  vs.  $17.9 \pm 9.9\%$ ,  $P < 0.001$ ) (Figure 1C).

##### 4.2. Representative Case Presentation from the Balloon Aortic Valvuloplasty-Intra-Aortic Balloon Pump Group

**Table 1.** The Patients' Clinical Features and Hemodynamic Parameters before Balloon Aortic Valvuloplasty

	BAV with IABP, (n = 14)	BAV Alone, (n = 33)	P value *
Age, years	$79.7 \pm 9.6$	$83.2 \pm 7.5$	0.190
Male sex, n (%)	4 (28.6)	6 (18.2)	0.685
Pre EF, %	$26.0 \pm 12.0$	$0.39 \pm 0.14$	$< 0.001$
Pre AVA, cm <sup>2</sup>	$59.6 \pm 11.8$	$0.61 \pm 0.16$	$< 0.001$
Pre PG, mmHg	$51.9 \pm 13.3$	$60.9 \pm 16.3$	0.073
Pre LAP, mmHg	$38.1 \pm 7.6$	$18.7 \pm 2.9$	$< 0.001$

The data have been presented as mean  $\pm$  standard deviation or number (%).

Abbreviations: AVA, aortic valve area; BAV, balloon aortic valvuloplasty; EF, ejection fraction; IABP, intra-aortic balloon pump; LAP, left atrial pressure; PG, pressure gradient

\*  $P < 0.001$ : statistically significant.

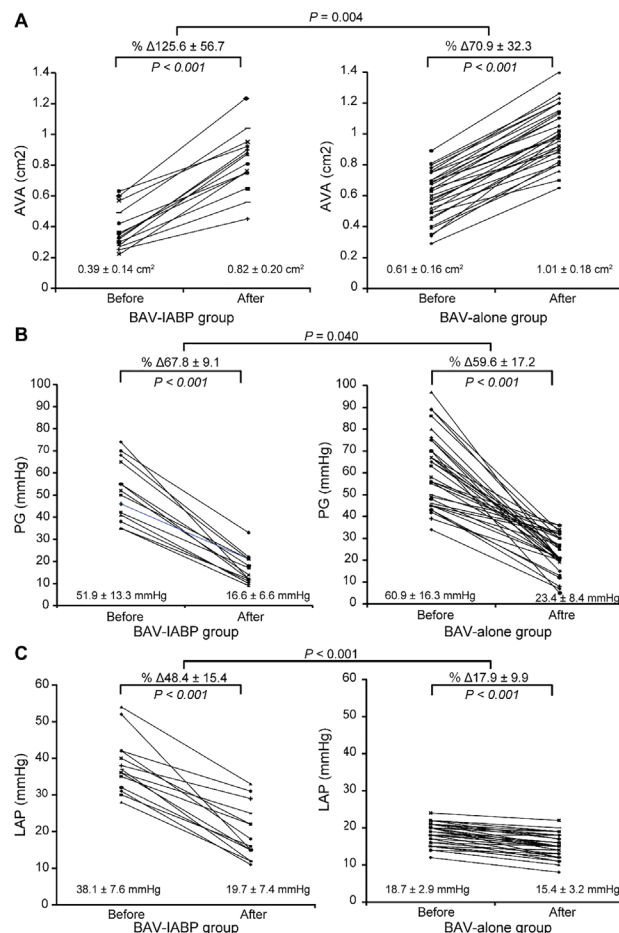
**Table 2.** Comorbidities in the Patients Treated with Balloon Aortic Valvuloplasty

	BAV with IABP, (n = 14)	BAV alone, (n = 33)
Coronary artery disease	28.6 (4)	21.2 (7)
Prior coronary artery bypass graft surgery	14.3 (2)	0 (0)
Arrhythmia	21.4 (3)	12.1 (4)
Pulmonary hypertension	21.4 (3)	0 (0)
Peripheral arterial disease	0 (0)	15.2 (5)
End-stage renal disease on hemodialysis	21.4 (3)	9.1 (3)
Chronic renal disease	14.3 (2)	21.2 (7)
Chronic obstructive pulmonary disease	0 (0)	15.2 (5)
Liver disease	0 (0)	3 (1)
Cerebral vascular accident	0 (0)	6.1 (2)
Neoplastic disease requiring therapeutics	7.1 (1)	15.2 (5)
Bicuspid aortic valve disease	7.1 (1)	0 (0)
Hypertension	0 (0)	18.2 (6)

Data have been presented as percentage (number).

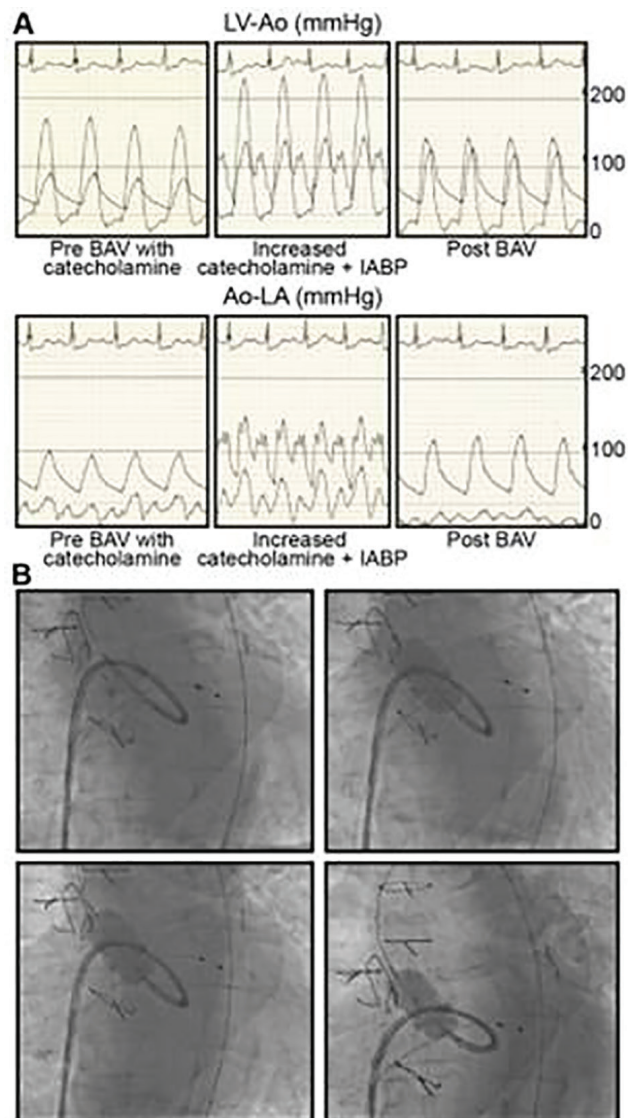
Abbreviations: BAV, balloon aortic valvuloplasty; IABP, intra-aortic balloon pump





**Figure 1.** Immediate Outcomes with Respect to Changes in Hemodynamic Parameters after Antegrade Balloon Aortic Valvuloplasty in the Two Study Groups: (A) aortic valve area, (B) pressure gradients, (C) left atrial pressure. AVA, aortic valve area; BAV, balloon aortic valvuloplasty; IABP, intra-aortic balloon pump; LAP, left atrial pressure; PG, pressure gradient.

Here, we describe the case of a 76-year-old man who had end-stage renal disease and was undergoing chronic hemodialysis. He had undergone coronary artery bypass grafting and surgical AVR with a 20-mm Carpentier-Edwards bioprosthetic valve 6 years ago. He developed critical AS as a consequence of progressive degeneration of the bioprosthesis, and his clinical condition was aggravated to medically resistant heart failure categorized as class IV according to the New York Heart Association classification. The patient complained about orthopnea, hemoptysis, and repeated syncope. His BP was 74/58 mmHg and his mean LAP was 28 mmHg when he was administered with positive inotropic agents. An IABP augmented his BP to 140 mmHg and maintained the mean LAP at < 35 mmHg while he was taking the maximum dose of catecholamine (Figure 2A). An emergent antegrade BAV using a 20-mm Inoue balloon was performed under stable hemodynamic conditions provided by the IABP (Figure 2B). Immediately after six balloon inflations to achieve the maximum balloon size, his BP was recovered to 125/55 mmHg while he was taking the minimal doses of positive inotropic agents. Indeed, his mean LAP was reduced to 12 mmHg without any further IABP support.



**Figure 2.** A Representative Case of BAV Accompanied by IABP Placement. (A): Hemodynamic Parameters. The Simultaneously Obtained LV and Aortic Pressures Demonstrated Critical Aortic Stenosis. Administration of Catecholamine Elevated Both LV Systolic Pressure and LVEDP. Placement of the IABP Augmented the Perfusion Pressures of Vital Organs and Helped Minimize the Increase in LVEDP. An antegrade BAV was performed while maintaining the hemodynamic conditions. The striking improvements in the systemic blood pressure and the mean left atrial pressure were confirmed after the successful antegrade BAV. (B): A critically stenosed immobile bioprosthetic valve was dilated using a 20-mm Inoue balloon, which was compatible with the IABP located in the descending aorta. Ao, aortic; LA, left atrial; LV, left ventricular.

## 5. Discussion

The present study findings provided novel insights into treatment of severe AS using BAV procedures. The results indicated that antegrade BAV could be undertaken in patients who were profoundly hemodynamically compromised without any serious adverse events. The results also demonstrated that AVA increased and PG decreased significantly immediately after BAV procedures. In addition, LAP reduced significantly immediately following antegrade BAV procedures. Hence, antegrade

BAV may be a safe and effective therapeutic option for severe AS, even in patients who are profoundly hemodynamically compromised, if IABP support is added.

Advanced AS causes myocardial failure, elevated LA and LV pressures, aggravation of functional Mitral Regurgitation (MR), and low cardiac outputs. In critical AS, depression of diastolic aortic pressure and elevation of LV End-Diastolic Pressure (LVEDP) considerably reduce LV-Ao diastolic pressure gradient and vital organs' perfusion. Moreover, elevation of BP by positive inotropic agents during BAV transiently aggravates intracardiac pressures (namely LVEDP and LAP) and the severity of functional MR, potentially worsening the hemodynamic status. Use of an IABP must be compatible with the Inoue balloon introduced via the antegrade approach, and there should not be any conflicts between the devices in the aorta. Placement of IABP increases the perfusion of vital organs and controls intracardiac pressures, thereby providing potent hemodynamic and myocardial support during antegrade BAV (3). In the current study, the procedures were completed in all BAV-IABP cases.

Utilizing the Inoue balloon via an antegrade approach has advantages, including rapid inflation-deflation cycles and self-positioning inflation pattern (6). Since it has rapid inflation-deflation cycles, burst pacing requirement is limited to a duration of < 2 s and it does not have any negative impacts on patients' hemodynamics (10). It has been reported that leaflet mobility gradually improves over the multiple inflations up to the measured diameter of the aortic annulus (11). The Inoue balloon is most suitable for achieving full inflation because its diameter increases in a stepwise manner. Transvenous introduction of the Inoue balloon and pre-closure technique combined with placement of a 14-Fr venous sheath and an IABP are also associated with freedom from vascular complications or embolic events (7, 8).

In the present study, the immediate reduction in the mean LAP induced by BAV was significantly greater in the BAV-IABP group than in the BAV-alone group. This difference may reflect the more pronounced therapeutic impact of BAV in patients with compromised hemodynamics (3). Although the immediate hemodynamic response in the BAV-IABP group was acceptable, the intermediate- to long-term prognosis following BAV depends on patients' conditions (12).

This study had several limitations. First, the factors that contribute to the clinical picture of cardiogenic shock with critical AS are often complex and are overlain by concomitant vital organs disorders that include critical coronary artery disease, MR, atrial fibrillation, and sometimes infectious diseases. Therefore, it can be difficult to evaluate involvement of AS irrespective of other comorbidities. Second, there were notable differences between the BAV-IABP and BAV-alone groups regarding the patients' clinical and hemodynamic statuses, which led to difficulties in making precise comparisons. Third, our evaluations and comparisons of the study groups were limited to the period that spanned from immediately after the procedure to the early phase following BAV. Thus, the results are not applicable to long-term effects of BAV.

Given that the results of this study highlighted the importance of reduced LAP in treatment of severe AS with BAV, future works should focus on additional approaches to achieve LAP reductions; for example, by using noninvasive positive-pressure ventilation therapy. Furthermore, intermediate- to long-term studies should be carried out on these patients to determine their additional treatment requirements as well as their prognoses.

In conclusion, antegrade BAV under IABP provided safe and effective immediate valvuloplasty. It also led to hemodynamic improvements in treatment of patients with critical AS accompanied by profound hemodynamic compromise and cardiogenic shock.

### Acknowledgements

The authors are grateful for the staff in the Department of Cardiology, Ikegami General Hospital and Department of Cardiovascular Medicine, Juntendo University Graduate School of Medicine for their assistance.

### Authors' Contribution

Yasushi Hirano and Yoshihito Sakata: study concept and design; Yasushi Hirano and Yoshihito Sakata: acquisition of data; Yasushi Hirano and Yoshihito Sakata: analysis and interpretation of data; Yasushi Hirano and Yoshihito Sakata: drafting of the manuscript; Yasushi Hirano and Yoshihito Sakata: critical revision of the manuscript for important intellectual content; Yasushi Hirano: statistical analysis; Yasushi Hirano and Yoshihito Sakata: administrative, technical, and material support; Yoshihito Sakata: study supervision.

### Funding/Support

The authors report no financial relationships or conflicts of interests regarding the manuscript content.

### Financial Disclosure

The authors report no financial relationships or conflicts of interests regarding the manuscript content.

### References

1. Sakata Y, Matsubara K, Tamiya S, Hayama Y, Usui K. The Efficacy and Safety of Antegrade Inoue-Balloon Aortic Valvuloplasty to Treat Calcific Critical Aortic Stenosis. *The Journal of invasive cardiology*. 2015;**27**(8):373-80.
2. Feldman T. Transseptal antegrade access for aortic valvuloplasty. *Catheterization and cardiovascular interventions : official journal of the Society for Cardiac Angiography & Interventions*. 2000;**50**(4):492-4.
3. Eisenhauer AC, Hadjipetrou P, Piemonte TC. Balloon aortic valvuloplasty revisited: the role of the inoue balloon and transseptal antegrade approach. *Catheterization and cardiovascular interventions : official journal of the Society for Cardiac Angiography & Interventions*. 2000;**50**(4):484-91.
4. Desnoyers MR, Salem DN, Rosenfield K, Mackey W, O'Donnell T, Isner JM. Treatment of cardiogenic shock by emergency aortic balloon valvuloplasty. *Annals of internal medicine*. 1988;**108**(6):833-5.
5. Aksoy O, Yousefzai R, Singh D, Agarwal S, O'Brien B, Griffin BP, et al. Cardiogenic shock in the setting of severe aortic stenosis: role of intra-aortic balloon pump support. *Heart*. 2011;**97**(10):838-43.
6. Sakata Y, Syed Z, Salinger MH, Feldman T. Percutaneous balloon aortic valvuloplasty: antegrade transseptal vs. conventional retrograde transarterial approach. *Catheterization and cardiovascular interventions : official journal of the Society for Cardiac Angiography & Interventions*. 2005;**64**(3):314-21.

7. Mylonas I, Sakata Y, Salinger M, Sanborn TA, Feldman T. The use of percutaneous suture-mediated closure for the management of 14 French femoral venous access. *The Journal of invasive cardiology*. 2006;**18**(7):299-302.
8. Solomon LW, Fusman B, Jolly N, Kim A, Feldman T. Percutaneous suture closure for management of large French size arterial puncture in aortic valvuloplasty. *The Journal of invasive cardiology*. 2001;**13**(8):592-6.
9. David F, Sanchez A, Yanez L, Velasquez E, Jimenez S, Martinez A, et al. Cardiac pacing in balloon aortic valvuloplasty. *International journal of cardiology*. 2007;**116**(3):327-30.
10. Witzke C, Don CW, Cubeddu RJ, Herrero-Garibi J, Pomerantsev E, Caldera A, et al. Impact of rapid ventricular pacing during percutaneous balloon aortic valvuloplasty in patients with critical aortic stenosis: should we be using it? *Catheterization and cardiovascular interventions : official journal of the Society for Cardiac Angiography & Interventions*. 2010;**75**(3):444-52.
11. Isner JM, Samuels DA, Slovenkai GA, Halaburka KR, Hougen TJ, Desnoyers MR, et al. Mechanism of aortic balloon valvuloplasty: fracture of valvular calcific deposits. *Annals of internal medicine*. 1988;**108**(3):377-80.
12. Kuntz RE, Tosteson AN, Berman AD, Goldman L, Gordon PC, Leonard BM, et al. Predictors of event-free survival after balloon aortic valvuloplasty. *The New England journal of medicine*. 1991;**325**(1):17-23.