



## Complications of Transcatheter Closure in Patent Ductus Arteriosus Patients

Faranak Behnaz<sup>1</sup>, Azita Chegini<sup>2,\*</sup>, Sima Rafiiian<sup>3</sup>, Mahboobeh Rasouli<sup>4</sup>

<sup>1</sup> Shohada Tajrish Hospital, Shahid Beheshti University of Medical Sciences, Tehran, IR Iran

<sup>2</sup> Blood Transfusion Research Center, High Institute for Research and Education in Transfusion Medicine, Tehran, IR Iran

<sup>3</sup> Shahid Modarres Hospital, Shahid Beheshti University of Medical Sciences, Tehran, IR Iran

<sup>4</sup> Department of Biostatistics, School of Public Health, Iran University of Medical Sciences, Tehran, IR Iran

### ARTICLE INFO

#### Article Type:

Research Article

#### Article History:

Received: 4 Mar 2017

Revised: 29 Jul 2017

Accepted: 24 Sep 2017

#### Keywords:

Cardiac Catheterization

Adverse Effects

Ductus Arteriosus

Treatment Outcome

Cardiovascular Surgical Procedures

### ABSTRACT

**Background:** Published studies have shown excellent success rates and also low rates of life-threatening complications with trans-catheter closure of patent ductus arteriosus (PDA). However, most studies to date have been conducted in developed nations and reports from developing countries such as Iran are lacking.

**Objectives:** To report our experience with trans-catheter closure of patent ductus arteriosus (PDA) and compare two devices and complications.

**Patients and Methods:** From 2007 to 2011, 72 consecutive PDA cases were prospectively enrolled. For PDAs  $\leq 2$  mm, the coiling method was employed whereas patients with PDA  $> 2$  mm received Amplatzer duct occlusion (ADO). Success was defined as trivial residual shunt ( $< 1$  mm) in the echocardiography performed 30 minutes after the procedure. After the procedure, the patients were admitted to the pediatric cardiology ward and observed for 72 hours during which the occurrence of major and minor complications was monitored. Major complications included cardiac arrest, displacement and/or embolization of the device and patient needing blood transfusion due to severe hemorrhage. Sampling was based on convenience method and the patients who had significant pulmonary artery hypertension were excluded from our study. Statistical analyses were done using SPSS software version 23 (IBM corp., New York, United States). Continuous variables are presented as mean  $\pm$  standard deviation. The Mann-Whitney U test was used to compare the differences between two independent groups. Categorical variables were depicted as proportions and compared across the intervention groups, using Chi-square with Fisher's exact test where appropriate. In all tests, a P value  $< 0.05$  was deemed necessary to reject the null hypothesis.

**Results:** With the coiling (n = 39) and Amplatzer methods (n = 33), successful closure was observed totally and recovered with no major complications. Frequent complications were benign arrhythmia (44.4%), and hemorrhage in 1 (1.4%) of the patients. Complication rate did not differ between the two techniques (P  $> 0.05$ ).

**Conclusions:** Excellent and comparable success rates for both closure techniques were observed and no major complications were observed.

### 1. Background

Patent ductus arteriosus (PDA) is an arterial structure that connects the upper portion of descending aorta to the pulmonary artery. During fetal period, patency of the ductus is essential in normal development of the fetus and

its premature closure will result in right heart failure and subsequent hydrops fetalis (1). Immediately after birth, however, rapid increase in oxygen tension of the circulation due to functioning lungs forces the small muscle cells of the ductus to constrict (2). Within the next two to three weeks, advancement of fibrosis leads to lumen obliteration and a permanent anatomical closure of the ductus ensues (2). If this process fails to initiate or progress, then PDA is formed. PDA accounts for 5 - 10% of all congenital heart

\*Corresponding author: Azita Chegini, Blood Transfusion Research Center, High Institute for Research and Education in Transfusion Medicine, Tehran, Iran. P.O. Box: 14665-1157, Tel: +98-2188601501, E-mail: azita\_chegini@yahoo.com.

diseases and is estimated to occur in approximately 1 in 2000 live births (3, 4).

The natural history of PDA varies and is largely dependent on the size of the vessel lumen, degree of shunting, and pulmonary vascular resistance (1). In a patient with large PDA, if no corrective measure is taken, persistent patency of the lumen leads to left heart failure, pulmonary hypertension, and subsequently Eisenmenger's syndrome (5, 6). In rare instances, the clinical picture might also be complicated by ductus aneurysm, endarteritis, aortic dissection, and laryngeal nerve impingement (7-10). For these reasons, a therapeutic closure of the PDA is often sought, preferably at an early age (11).

In the past two decades, trans-catheter techniques have become the standard of care in the treatment of PDA, supplanting surgical ligation of the ductus in the majority of cases. Owing to the significant technical advancements in the field of trans-catheter embolization, even large PDAs are now routinely closed by deployment of state-of-the-art devices and surgery is reserved for very large PDA, PDA with a complex anatomy, preterm infants, or in patients with failed catheterization (1, 4). Coil occlusion and Amplatzer duct occlusion (ADO) are the two most common trans-catheter techniques used for PDA embolization with excellent success rates and limited complications reported by large series and randomized clinical trials (12-18). These patients need special anesthetic management which depends on physiological and pharmacological principles (19). Most studies to date have only enrolled patients from centers in developed countries, and reports from developing countries, and in particular the Middle East, are lacking. This is especially important since success rate of the procedure and also rate of complications largely depend on the experience of the interventional cardiologist and also the level of care offered by the facility before, during, and after the procedure.

## 2. Objectives

In the present study, in a prospective evaluation of patients with PDA, we report our experience in a university affiliated teaching hospital in Iran (Shahid Modarres Hospital). Additionally, we provide a comparison between the coiling and ADO techniques for use in treatment of patients with PDA.

## 3. Patients and Methods

From January 2007 to March 2011, transcatheter closure of PDA was attempted in 72 patients aged between 20 days and 51 years. All patients had clinical and/or echocardiographic signs of PDA confirmed by thorough physical examination and imaging techniques. The patients who had significant pulmonary artery hypertension were excluded from our study. In this center, the selection of the device type was based on the PDA size. For PDAs  $\leq$  2 mm coiling method was employed whereas patients with PDA larger than 2 mm were treated with the ADO technique. With this strategy, over the course of four years, 39 patients were treated with the coiling method and in the other 33 cases, ADO device was deployed. Prior to catheterization, written informed consent was obtained from legal guardian of all participants.

The ethics committee of the university also approved the study protocol.

All procedures were performed while the patient was sedated, using the following protocol: midazolam 0.5 mg/kg oral for premedication 30 minutes before entering the cath. lab, then midazolam 0.05 - 0.1 mg/kg, fentanyl 0.5  $\mu$ g/kg, propofol 1 - 2mg/kg, and ketamin 0.2 - 0.8 mg/kg administered intravenously for induction, followed by propofol 25 - 75  $\mu$ g/kg/min during the procedure. The coiling was performed using the retrograde approach as previously described (14, 19, 20). In summary, after anesthesia, and ascertainment of hemodynamic stability, an aortogram in the lateral and right anterior oblique views was performed to carefully delineate the shape and diameter of the ductus and Heparin was administered by single bolus (50 - 100 units/kg in pediatrics and 250 - 500 units/kg in adults). In all closures, a single coil (pfm medical, Koln, Germany) was used so that it was at least two times wider than the narrowest PDA diameter depicted on aortography. After coil deployment, a repeat aortogram confirmed its proper positioning. The procedure for ADO deployment has been previously described at length (12, 16, 17, 20-22).

In brief, after proper anesthesia and confirmation of hemodynamic stability, an investigatory aortogram was performed as described earlier for the coiling method. Following the aortogram, a guide wire was placed in the descending aorta by using an end-hole catheter. A long sheath was then introduced over the guidewire in the descending aorta from an intravenous access. The ADO device (Lifetech Scientific Co., Shenzhen, China) size was chosen so that it was at least 2 mm larger than the narrowest diameter of the PDA, as depicted on aortogram. With the sheath already in place, the device was deployed to the descending aorta and firmly pulled against the orifice of the ductus while gently pulling back the delivery sheath. With the sheath still in place, an immediate repeat aortogram was performed to assess the placement of the device into its desired position and, if ascertained, the device was released by counterclockwise rotation of the delivery cable.

After the procedure, the patients were admitted to the pediatric cardiology ward and observed for 72 hours during which the occurrence of major and minor complications was monitored. Major complications included cardiac arrest, displacement and/or embolization of the device and patient needing blood transfusion due to severe hemorrhage. In the event any of the major complications occurred, the patient was immediately transferred to the intensive care unit. Minor complications comprised benign arrhythmia. No prophylactic antibiotic therapy was administered. If infection at the site of sheath insertion was suspected, Keflin (25 - 50 mg/kg) plus gentamycin 1 - 1.5 mg/kg was administered intravenously. After catheterization, dorsal pedis and tibialis posterior artery were palpated hourly. If an acute arterial injury was suspected, as evidence of weak or absent pedal pulse, unfractionated heparin was administered (10 unit/kg/hour). In both methods, the success was defined as no evidence of shunt, or trivial residual shunt (< 1 mm) in the echocardiography performed 30 minutes after the procedure. The patients were followed up by daily echocardiography in the first three days, and

then every six months after discharge. Statistical analyses were done using SPSS software, version 23 (IBM corp., New York, United States). Continuous variables are presented as mean  $\pm$  standard deviation. Mann-Whitney U test was used to compare the differences between the two independent groups. Categorical variables are depicted as proportions and compared across intervention groups using Chi-square with Fisher's exact test where appropriate. In all tests, a P value  $< 0.05$  was deemed necessary to reject the null hypothesis.

#### 4. Results

During the study period, a total of 72 catheter placements were performed in patients with PDA. Baseline demographic and clinical characteristics of enrolled patients are delineated in Table 1. Males comprised the majority of patients ( $n = 49$ , 68.1%). In the ADO group, the number of male patients was lower than the females (45.8% vs. 54.2%), but the difference did not reach statistical significance ( $P = 0.090$ ). Age of the participants ranged from 20 days to 51 years. The median age was 2 years [interquartile range (IQR) 1 - 6.5 years], and there was no statistically significant difference between the two groups ( $P$  value = 0.113). The median weight was 13 kg [interquartile range (IQR) 9 - 21 kg] and again it was similar between the two groups. ( $P$  value = 0.123).

In the coiling method, treatment outcomes according to closure method and related complications are summarized in Table 2. Coiling was successful in 39 (100%) patients without major complication, device embolization and shunt. Minor complications occurred in 19(48.7%) patients, with the most common being arrhythmia (PSVT). We did not observe other minor complications including hemorrhage.

ADO device was successfully placed in all 33 patients although subsequent embolization was not observed in our patients. Similar to the coiling method, the most common benign complication was arrhythmia which was observed in 13 (39.4%) patients. Hemorrhage at the site of sheath insertion was observed in one patient (1.4% totally), but it was not severe enough to necessitate blood transfusion.

A comparison between the frequencies of complications with the two methods is presented in Table 2. The proportion of patients with no complications was comparable between the two groups. Moreover, regarding complications, although one patient undergoing ADO closure experienced hemorrhage, the difference did not

reach statistical significance probably due to larger sheath insertion site. The frequencies of other complications were approximately similar between the two groups. With Chi-Square test, we did not have any relation between device and complication variables. ( $P = 0.428$ ) The most common complication was benign arrhythmia. 40 patients (55.6%) had not any complications. The Mann-Whitney U non-parametric test was used to test for differences in age values by device. No significant differences were found in the mean age by devices (Figure 1).

#### 5. Discussion

In the present study, an excellent success rate of 100% was achieved irrespective of the closure method employed. Similar success rates have also been reported by other research groups for both coiling and ADO closure methods (12-18).

Coil method is an effective technique in closure of small size PDA (Patent Ductus Arteriosus) which is applicable for patients with different sizes. This easy and inexpensive closure technique had a higher rate of significant complications such as hemolysis, residual shunt, embolization and second catheterization in a moderate to large PDA (2.5 mm). In small children with PDA  $\geq 2.5$  mm, the coil moves toward the pulmonary or peripheral systemic arteries and can close it, so its implementation is difficult and unsuitable. The multiple coils approach in large PDA has been shown to increase the risk of failure and left pulmonary stenosis. Although the Amplatzer Duct Occluder (ADO) implementation is easy and has a moderately small delivery sheath (6 - 8 Fr), and provides the opportunity for repositioning and high proportions of closure. The Amplatzer has been demonstrated very adaptable to ductal anatomical variations and can close from moderate to very large PDA with shorter fluoroscopy and procedural time (3.5 kg).

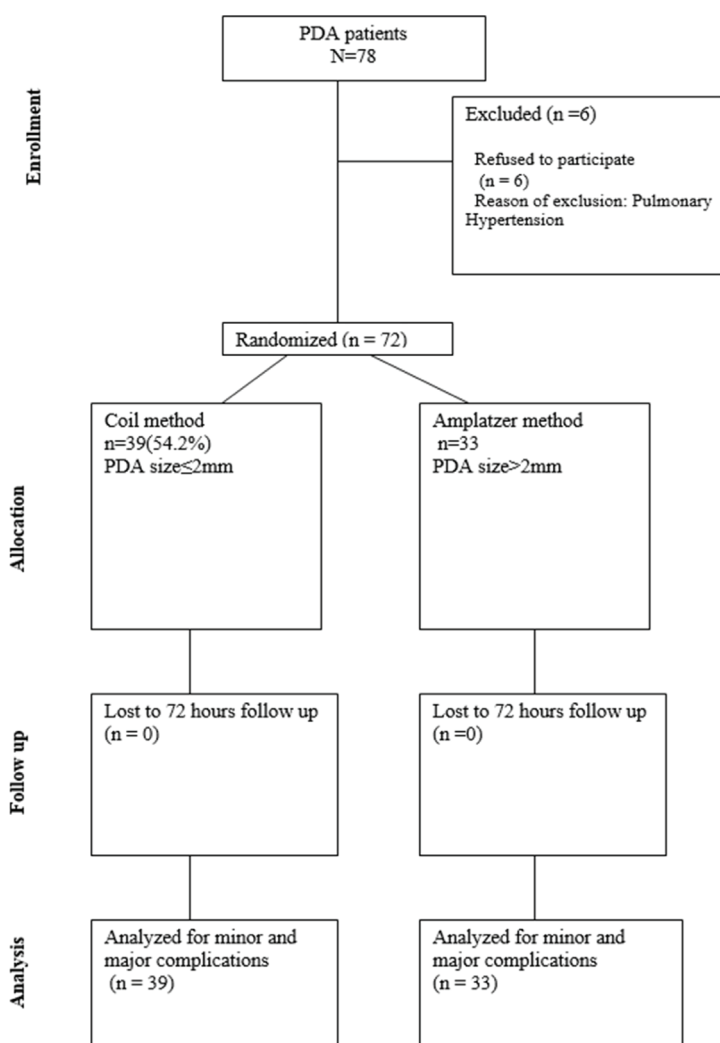
In one of the earliest efforts, Masura and colleagues used the ADO device in an antegrade manner to close moderate to large PDAs in 24 patients aged 0.4 to 48 years (16). Successful implantation was achieved in all but one patient, and no major complications were recorded (16). A large multi-center trial in the United States also yielded comparable results with the ADO method. Of the 428 patients with PDA diameter ranging from 0.9 to 11.2 mm, 98% success rate was reported (17).

**Table 1.** Distribution of Complications in 72 Patients by Gender

Complications	Gender	
	Female	Male
Without complication	14 (%35)	26 (65%)
With complication	9 (28.1%)	23 (71.9%)
Total	23 (31.9%)	49 (68.1%)

**Table 2.** Distribution of Complications in 72 Patients by Device

Complications	Device	
	Coiling Device	Amplatzer Device
Without complication	20 (51.3%)	20 (60.6%)
With complication	19 (48.7%)	13 (39.4%)
Total	39 (54.2%)	33 (45.8%)



**Figure 1.** The Diagram Showing the Flow of Participants through Each Stage of Research

Our experiment did not lead to any life-threatening event. Mehta and colleagues reviewed the records of pediatric patients having undergone cardiac catheterization from 1994 and 2006 in Toronto, Canada (21). There were records of 674 PDA closures, among which 37 (5.4%) complications were observed (21). It is worth noting that only three complications (8%) were considered as major and one (2.7%) resulted in death (21). Device embolization and subsequent bowel ischemia were cited as the cause of death in the aforementioned subject (21). Along the same lines, Bennett and colleagues provided an account of all complications occurring during a 9-year period in pediatric patients undergoing cardiac catheterization, in a center in Birmingham, United Kingdom (23). Overall, 572 cases of PDA/ASD occlusion were recorded and events including both major and minor complications occurred in 24 (4.2%) patients (23). According to their findings, PDA/ASD closure was associated with the lowest rate of complications probably due to the elective nature of the procedure and conserved heart function in the affected individuals (24). Pass and colleagues in their multi-center clinical trial of ADO in the United States reported major and total complications in 2.3% and 7.1% of the patients, respectively (17). Only one case of death occurred in a 15-month old patient five months

after successful implantation and overwhelming sepsis was identified as the cause (17). Moreover, two cases of device embolization occurred; one required open surgery, and in the other, the device was retrieved percutaneously (17). The most common minor complications were hematoma of the groin, and loss of peripheral pulses (17). Like these observations, we report that, compared with routine reports from developed countries, there were no significant higher rate of complications. These complications underscore the fact that multiple factors influence the outcomes of cardiac catheterization and reports from various centers with different levels of care and experience are needed to reach firm conclusions regarding the safety and feasibility of a specific procedure.

Wessel and colleagues have shown that by clear demarcation of the PDA anatomy prior to catheterization, the use of a sedation/anesthesia regimen tailored to the patient's condition, and avoidance of systemic anti-coagulation, it is possible to markedly reduce the incidence of complications in PDA closure (24). By implementing these measures, they were able to perform trans-catheter closure in 23 patients without facing major complications (24). Of note, in 19 patients (82.6%) the procedure was carried out in an outpatient setting and the patients were

discharged the same day, thereby significantly shortening the length of hospital stay (24).

In the present study, success rate and complications of the coiling and ADO closure methods were compared. In our sample of 72 patients, success rate, and also rates for minor complications were not comparable between the two methods. Santoro and colleagues compared coil occlusion method with Cook detachable coils with ADO device for large PDAs in 47 patients with an age range of 4 months - 66 years (25). Congruent with our findings, they found that procedural success rate was comparable between the two methods (89.5% for coiling vs. 96.4% for ADO) (25). On the other hand, the coiling method was found to be significantly more time consuming, albeit cheaper (25). No major complications occurred in either group (25). In another study, Hunag and colleagues compared Gianturco multiple coiling with ADO occlusion for closure of large PDAs (19). According to their findings, although ADO yielded a better success rate immediately after the procedure and was less likely to fail, the 6-month success rates were comparable between the two techniques (100% for coiling vs. 94.5% for ADO) (19). Additionally, although device embolization and also hemolysis occurred more commonly among patients receiving coil occlusion, the difference was not statistically significant (19).

**Conclusion:** Excellent and comparable success rates for both closure techniques were observed with no major complications.

#### Acknowledgements

There is no acknowledgement.

#### Authors' Contribution

Faranak Behnaz and Azita Chegini Conceived of the presented research. Sima Rafieyan performed the catheterization and Faranak Behnaz and Azita Chegini developed the study. Mahboobeh Rasouli verified the analytical methods. Franak Behnaz and Azita Chegini supervised the findings of this work. Azita Chegini took the lead in writing the manuscript. Azita Chegini and Franak Behnaz discussed the results and contributed to the final manuscript.

#### Funding/Support

This research was carried out without funding.

#### Financial Disclosure

The authors declare that there are no conflicts of interest.

#### References

- Schneider DJ, Moore JW. Patent ductus arteriosus. *Circulation*. 2006;**114**(17):1873-82.
- Gournay V. The ductus arteriosus: physiology, regulation, and functional and congenital anomalies. *Archives of cardiovascular diseases*. 2011;**104**(11):578-85.
- Mitchell SC, Korones SB, Berendes HW. Congenital heart disease in 56,109 births. Incidence and natural history. *Circulation*. 1971;**43**(3):323-32.
- Schneider DJ. The patent ductus arteriosus in term infants, children, and adults. *Seminars in perinatology*. 2012;**36**(2):146-53.
- Fisher RG, Moodie DS, Sterba R, Gill CC. Patent ductus arteriosus in adults--long-term follow-up: nonsurgical versus surgical treatment. *Journal of the American College of Cardiology*. 1986;**8**(2):280-4.
- Marquis RM, Miller HC, McCormack RJ, Matthews MB, Kitchin AH. Persistence of ductus arteriosus with left to right shunt in the older patient. *British heart journal*. 1982;**48**(5):469-84.
- Berger M, Ferguson C, Hendry J. Paralysis of the left diaphragm, left vocal cord, and aneurysm of the ductus arteriosus in a 7-week-old infant. *The Journal of pediatrics*. 1960;**56**:800-2.
- Campbell M. Natural history of persistent ductus arteriosus. *British heart journal*. 1968;**30**(1):4-13.
- Dyamenahalli U, Smallhorn JF, Geva T, Fouron JC, Cairns P, Jutras L, et al. Isolated ductus arteriosus aneurysm in the fetus and infant: a multi-institutional experience. *Journal of the American College of Cardiology*. 2000;**36**(1):262-9.
- McCarthy C, Dickson GH, Besterman EM, Bromley LL, Thompson AE. Aortic dissection, with rupture through ductus arteriosus into pulmonary artery. *British heart journal*. 1972;**34**(4):428-30.
- Wyllie J. Treatment of patent ductus arteriosus. *Seminars in neonatology* : SN. 2003;**8**(6):425-32.
- Bilkis AA, Alwi M, Hasri S, Haifa AL, Geetha K, Rehman MA, et al. The Amplatzer duct occluder: experience in 209 patients. *Journal of the American College of Cardiology*. 2001;**37**(1):258-61.
- Hijazi ZM, Geggel RL. Results of antegrade transcatheter closure of patent ductus arteriosus using single or multiple Gianturco coils. *The American journal of cardiology*. 1994;**74**(9):925-9.
- Hijazi ZM, Geggel RL. Transcatheter closure of large patent ductus arteriosus (> or = 4 mm) with multiple Gianturco coils: immediate and mid-term results. *Heart*. 1996;**76**(6):536-40.
- Lloyd TR, Fedderly R, Mendelsohn AM, Sandhu SK, Beekman RH. Transcatheter occlusion of patent ductus arteriosus with Gianturco coils. *Circulation*. 1993;**88**(4):1412-20.
- Masura J, Walsh KP, Thanopoulos B, Chan C, Bass J, Goussous Y, et al. Catheter closure of moderate-to large-sized patent ductus arteriosus using the new Amplatzer duct occluder: immediate and short-term results. *Journal of the American College of Cardiology*. 1998;**31**(4):878-82.
- Pass RH, Hijazi Z, Hsu DT, Lewis V, Hellenbrand WE. Multicenter USA Amplatzer patent ductus arteriosus occlusion device trial: initial and one-year results. *Journal of the American College of Cardiology*. 2004;**44**(3):513-9.
- Patel HT, Cao QL, Rhodes J, Hijazi ZM. Long-term outcome of transcatheter coil closure of small to large patent ductus arteriosus. *Catheterization and Cardiovascular Interventions*. 1999;**47**(4):457-61.
- Huang TC, Chien KJ, Hsieh KS, Lin CC, Lee CL. Comparison of 0.052-inch coils vs amplatzer duct occluder for transcatheter closure of moderate to large patent ductus arteriosus. *Circulation journal* : official journal of the Japanese Circulation Society. 2009;**73**(2):356-60.
- Grifka MR, Jones TK. Transcatheter closure of large PDA using 0.052" gianturco coils: controlled delivery using a biptome catheter through a 4 French sheath. *Catheterization and cardiovascular interventions* : official journal of the Society for Cardiac Angiography & Interventions. 2000;**49**(3):301-6.
- Mehta R, Lee KJ, Chaturvedi R, Benson L. Complications of pediatric cardiac catheterization: a review in the current era. *Catheterization and cardiovascular interventions* : official journal of the Society for Cardiac Angiography & Interventions. 2008;**72**(2):278-85.
- Wang JK, Liau CS, Huang JJ, Hsu KL, Lo PH, Hung JS, et al. Transcatheter closure of patent ductus arteriosus using Gianturco coils in adolescents and adults. *Catheterization and cardiovascular interventions* : official journal of the Society for Cardiac Angiography & Interventions. 2002;**55**(4):513-8.
- Bennett D, Marcus R, Stokes M. Incidents and complications during pediatric cardiac catheterization. *Pediatric Anesthesia*. 2005;**15**(12):1083-8.
- Wessel DL, Keane JF, Parness I, Lock JE. Outpatient closure of the patent ductus arteriosus. *Circulation*. 1988;**77**(5):1068-71.
- Santoro G, Bigazzi MC, Palladino MT, Russo MG, Carrozza M, Calabro R. Comparison of percutaneous closure of large patent ductus arteriosus by multiple coils versus the Amplatzer duct occluder device. *The American Journal of Cardiology*. 2004;**94**(2):252-5.