



Pendulous Heart with Alternating Axis: A Suspicious Clue for Diagnosis of a Rare Disease

Abbas Ali Rafighdoust¹, Hoorak Poorzand¹, Amir Hossein Rafighdoust¹, Reza Jafarzadeh Esfehiani², Milad Hemati¹, Mohammad Vojdanparast^{1,*}

¹ Atherosclerosis Prevention Research Center, Imam Reza Hospital, School of Medicine, Mashhad University of Medical Sciences, Mashhad, IR Iran

² Student Research Committee, Sabzevar University of Medical Sciences, Sabzevar, IR Iran

ARTICLE INFO

Article Type:
Case Report

Article History:
Received: 10 Apr 2014
Accepted: 02 Oct 2014

Keywords:
Pericardium
Chest Pain
Echocardiography

ABSTRACT

Absence of pericardium is a rare type of pericardial disorders. Left sided pericardial absence is more common than the right one. This disorder may present with a variety of signs and symptoms or abnormalities in electrocardiography and echocardiography. In this report, we discussed diagnosis of partial absence of pericardium in a 52-year-old man presented with a dull left-sided chest pain from 4 months ago with special electrocardiographic features. The axis deviations in his serial electrocardiograms led us to further evaluations with possible diagnosis of pericardial absence. His echocardiography and Magnetic Resonance Imaging (MRI) confirmed the suspicion of pericardial absence. Suspicion of potentially life-threatening cardiac abnormalities should remain even while facing atypical chest pain or other non-specific symptoms. In this case, abnormal electrocardiographic and chest X-Ray findings together with echocardiography were all helpful in referring the patient for cardiac MRI as the imaging modality of choice in such cases.

► Implication for health policy/practice/research/medical education:

Paying attention to simple cardiac evaluations, such as electrocardiography, is always the corner stone of diagnosis even in healthy people with atypical chest pain. In our patient, serial electrocardiographies showed axis deviations, bringing the suspicion of absence of pericardium in patients with atypical chest pain.

1. Introduction

Congenital pericardial defects are seen approximately in 1/10000 autopsies and partial left and right pericardial absence is detected in 70% and 17% of such cases, respectively (1). This disorder is usually an incidental finding in cardiothoracic imaging (2). In this report, we are going to discuss a case of partial left absence of pericardium in a 52-year-old man, presenting with chest pain and abnormal electrocardiographic findings.

2. Case Presentation

A 52-year-old man with a history of atypical chest pain from 4 months ago was referred to our cardiology department. In his cardiac examination, apical impulse was displaced laterally and holosystolic murmur was

heard in the left sternal border. Blood laboratory tests were normal. Serial electrocardiograms (ECG) were taken showing changes in counter of QRS in limb leads. In the first ECG, left axis deviation and poor R progression in the precordial leads were prominent (Group figure 1). However, his next ECG showed right axis deviation (Group figure 1-2). Moreover, leftward displacement of the heart with flattening and elongation of the left cardiac border was apparent in his chest X-Ray (CXR). Transthoracic echocardiography was also done in which, abnormal orientation of the heart was evident in parasternal long axis (posteriorly shift of the left ventricle) (Group figure 2a). The apical views could be taken at the extreme left side of the thorax in the axillary line. Besides, cardiac hyper mobility with swinging motion was noted in apical four chamber view. M-mode echocardiography revealed abnormal interventricular septal motion, flat systolic motion, and paradoxical motion in diastole (Group figure 2b). In addition, the left ventricle

*Corresponding author: Mohammad Vojdanparast, Cardiology Department, Imam Reza Hospital, Mashhad, IR Iran, Tel: + 98-5118433015, E-mail: vejdanparast.m@gmail.com

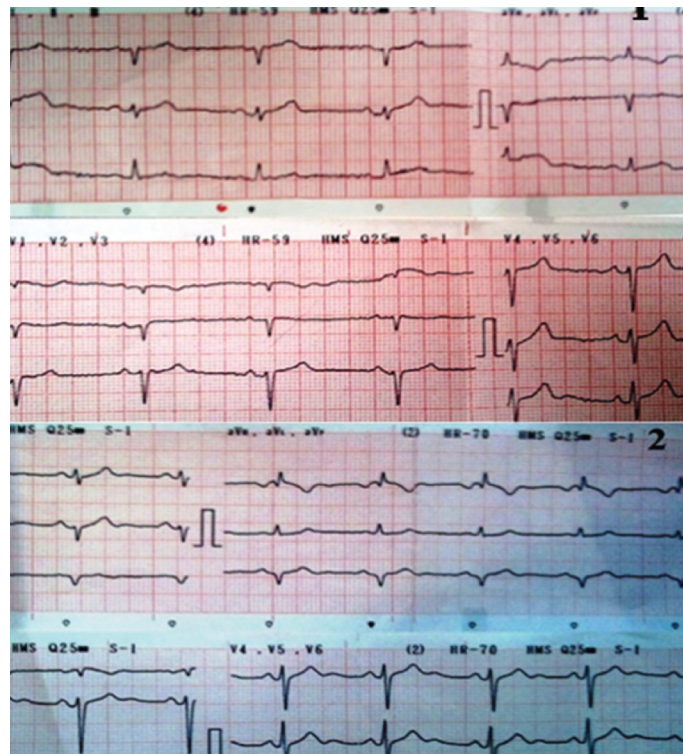


Figure 1. 1-1. The First ECG Showed Normal Sinus Rhythm with Left Axis Deviation; 1-2. In the Second ECG, Axis Changed to Right

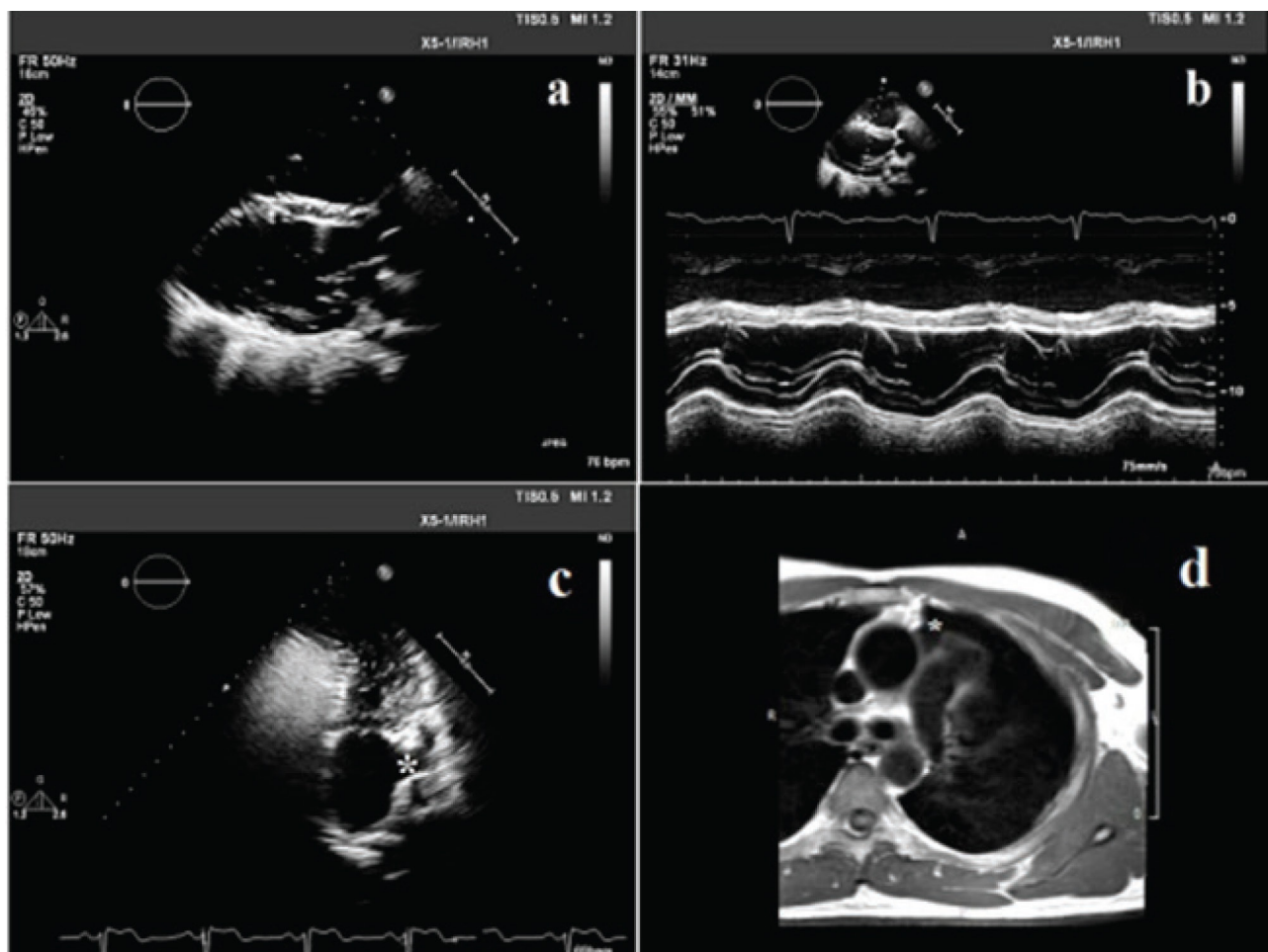


Figure 2. a. Posterior Deviation of the Heart in Parasternal Long Axis View; b. Abnormal Septal Motion in M-mode Echocardiography: Flattening of the Inter-Ventricular Septum in Systole and Paradoxical Motion in Diastole; c. Apical Two Chamber View of the Left Heart, Asterisk Denoting to the Elongated Left Atrium Auricle (the Star); d. Cardiac Magnetic Resonance Imaging Images Revealed Interposition of the Lung between the Aorta and Pulmonary Artery (the Star).

had tear drop appearance. Left atrium auricle was also elongated (Group figure 2c). The right ventricle, on the other hand, appeared prominent and elongated, but had normal function. Selective coronary angiography revealed only a non-significant lesion at the proximal portion of the right coronary artery. In Magnetic Resonance Imaging (MRI), a small part of parietal pericardium was defined (anterior to the right ventricle and over the right atrium). However, the pericardium could not be visualized in other parts. Interposition of the lung tissue between the aorta and pulmonary artery (aortopulmonary space), as a characteristic finding, was also prominent (Group figure 2d). The diagnosis of congenital partial absence of pericardium was confirmed by cardiac MRI.

3. Discussion

Pericardial defects are rare cardiac findings and can be associated with other congenital abnormalities. Patent ductus arteriosus and atrial septal defect are two common defects associated with congenital absence of pericardium which were all absent in our patient (2). Up to 80% of pericardial defects are left sided and partial types are less common compared to complete ones (2). Partial left-sided defects can especially present with shortness of breath, chest pain, or sudden death, while the complete ones are typically asymptomatic (1, 2). Poor R progression, right axis deviation, and right bundle branch block are three common ECG findings in the left sided type (2-4). Although these electrocardiographic patterns are typical for absence of pericardium, our case presented with a rare ECG finding; i.e., changing axis deviation in serial ECG recording. To the best of our knowledge, there is only one other report with this ECG pattern for absence of pericardium (5). Different axis deviation in serial ECGs is often seen in patients with massive pericardial effusion or pericardial rupture (5).

Abnormal septal and cardiac motions are the first echocardiographic clues for the absence of pericardium (5, 6). Paradoxical septal motion or abnormal right heart configuration in the absence of cardiac shunts should raise the suspicion of this disorder and necessitate further evaluation (2, 4). MRI can differentiate complete from partial defects (crucial for taking the desired management strategy) and is a definitive modality for diagnosis (4). Interposition of lung in the aortopulmonary space is the pathognomonic feature of this disease which was also evident in the present case (4). Observation is usually the treatment for pericardial absence (2). As partial defects

have higher risk of herniation, surgical pericardioplasty is considered in partial absences or symptomatic patients (4).

In conclusion, partial absence of pericardium is a rare congenital disease and can be a life-threatening abnormality. In the present case, abnormal ECG and CXR findings together with echocardiography were all considered for referring the patient for cardiac MRI as the imaging modality of choice in such cases.

Acknowledgements

There is no acknowledgement.

Authors' Contribution

Study concept and design: Abbas Ali Rafighdoust, Hoorak Poorzand, and Mohammad Vojdanparast; Acquisition of data: Reza Jafarzadeh Esfahani; Analysis and interpretation of data: Reza Jafarzadeh Esfahani, Milad Hemati; Drafting of the manuscript: Reza Jafarzadeh Esfahani; Critical revision of the manuscript for important intellectual content: Hoorak Poorzand, Mohammad Vojdanparast; Administrative, technical, and material support: Amir Hossein Rafighdoust; Study supervision: Abbas Ali Rafighdoust

Financial disclosure

We have no financial interests related to the material in the manuscript.

Funding/Support

There is no funding/support.

References

1. Maisch B, Seferovic PM, Ristic AD, Erbel R, Rienmuller R, Adler Y, et al. [Guidelines on the diagnosis and management of pericardial diseases. Executive summary]. *Rev Esp Cardiol*. 2004;57(11):1090-114.
2. Verde F, Johnson PT, Jha S, Fishman EK, Zimmerman SL. Congenital absence of the pericardium and its mimics. *J Cardiovasc Comput Tomogr*. 2013;7(1):11-7.
3. Azhar IO, Anas R. Congenital absence of pericardium in babies with patent ductus arteriosus. *Med J Malaysia*. 2013;68(3):259-61.
4. Garnier F, Eicher JC, Philip JL, Lalande A, Bieber H, Voute MF, et al. Congenital complete absence of the left pericardium: a rare cause of chest pain or pseudo-right heart overload. *Clin Cardiol*. 2010;33(2):E52-7.
5. Topilsky Y, Tabatabaei N, Freeman WK, Saleh HK, Villarraga HR, Mulvagh SL. Images in cardiovascular medicine. Pendulum heart in congenital absence of the pericardium. *Circulation*. 2010;121(10):1272-4.
6. Jurko AJ, Minarik M, Cisarikova V, Polacek H, Schusterova I. Congenital complete and partial absence of the left pericardium. *Wien Med Wochenschr*. 2013;163(17-18):426-8.