

# Left Ventricular Noncompaction

SH Ranjit, M Rabi

Department of Cardiology, Shahid Gangalal National Heart Center, Bansbari, Kathmandu, Nepal

LVNC is a genetic cardiac disease of emerging importance with a distinct clinical and pathophysiological presentation. The diagnosis of LVNC, however, is often missed, most often as a consequence of ignorance of the condition. Echocardiography is considered the reference standard for the diagnosis of LVNC. Prognosis remains poor for patients with impaired systolic left ventricular function, as treatment options are very limited. Because of the familial association of LVNC, first-degree relatives should be screened by Echocardiography.

## Introduction

Left ventricular noncompaction (LVNC) is a rare congenital cardiomyopathy, caused by intrauterine arrest of compaction of the myocardial fibers and meshwork, an important process in myocardial development.<sup>1</sup> LVNC characterized by a distinctive (“spongy”) morphological appearance of the LV myocardium. Noncompaction involves predominantly the distal (apical) portion of the LV chamber with deep intertrabecular recesses (sinusoids) in communication with the ventricular cavity, resulting from an arrest in the normal embryogenesis.<sup>2</sup> LVNC may be an isolated finding or may be associated with other congenital heart anomalies such as complex cyanotic congenital heart disease.<sup>3</sup>

## History

LVNC was first described in the case of 33 year old woman in 1984, assessed by two-dimensional echocardiography.<sup>4</sup> In 1985 a 21-

year old female patient who first experienced an episode of acute left heart failure at the age of 15, who had undergone left ventricular angiography showed a honeycomb-like structure of the inner left ventricular wall and diagnosed as LVNC.<sup>5</sup> In 1986 a 21-year-old male student who died of acute left heart failure, an autopsy proved for the first time the diagnosis of persistent sinusoids, today called LVNC.<sup>5</sup>

## Classification Of Cardiomyopathy

The 1995 report of the World Health Organization and of the International Society and Federation of Cardiology Task Force on the Definition and Classification of Cardiomyopathies, LVNC is regarded is included in the category of unclassified cardiomyopathies.<sup>6</sup> Recently published Contemporary Definitions and Classification of the cardiomyopathies, LVNC remains in the category of genetic cardiomyopathy.<sup>7</sup>

## WHO Classification of cardiomyopathies

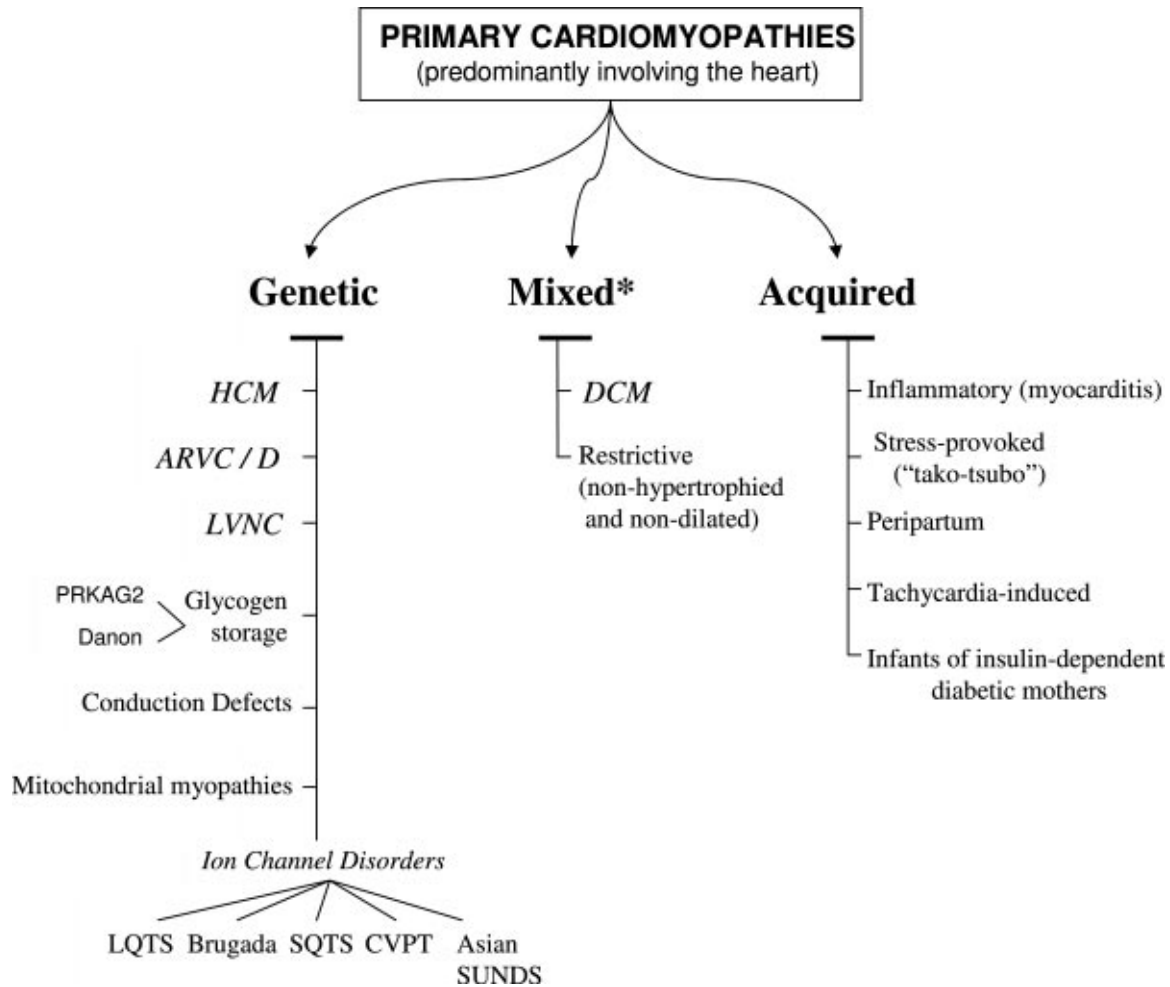
1. Dilated cardiomyopathy
2. Hypertrophic cardiomyopathy
3. Restrictive cardiomyopathy
4. Arrhythmogenic right ventricular cardiomyopathy
5. Unclassified cardiomyopathies.

## Correspondence:

SH Ranjit

Department of Cardiology, Shahid Gangalal National Heart Center, Bansbari, Kathmandu, Nepal  
Email: sharmaranjit100@hotmail.com

## Contemporary Definitions and Classification of the Cardiomyopathies-2006



### Epidemiology

The prevalence of LVNC is not well known and there has been a scarcity of population-based studies of LVNC. In largest series it has been reported from 0.014% to 0.05%. A retrospective cohort study of primary cardiomyopathy in Australian children, LVNC accounted for 9.2% of all cases, identified as the third most frequent cardiomyopathy after dilated and hypertrophic cardiomyopathies and based on this study the prevalence of LVNC among children's 0-10 years of age was 0.12 per 100,000.<sup>8</sup> In the largest series of adult patients with

LVNC, Oechslin et al reported that prevalence was 0.014% in patients referred to the echocardiography laboratory.<sup>9</sup> LVNC can affect any age group and review of the literature shows a slight excess of males with male proportion ranging from 56% to 82%.<sup>10-11</sup>

### Etiology

LVNC is a genetically heterogeneous disorder. Both familial and nonfamilial forms have been described. In the original report of LVNC, which predominantly involved children, familial recurrence was seen in half of patients.<sup>3</sup> Familial

recurrence was seen in 18% in the largest reported adult population with LVNC.<sup>9</sup> In the isolated form of LVNC, ZASP (Z-line) and mitochondrial mutations and X-linked inheritance resulting from mutations in the G4.5 gene encoding tafazzin (including association with Barth syndrome in neonates) have been reported. Noncompaction associated with congenital heart disease has been shown to result from mutations in the  $\alpha$ -dystrobrevin gene and transcription factor NKX2.5.<sup>7</sup>

Neonatal LVNC can be a mutation caused by mutations in the G 4.5 gene located on the X chromosome, associated with Barth syndrome.<sup>12</sup> G 4.5 codes for tafazzin, a protein that has no sequence homology with other known proteins. However, mutations in the G 4.5 gene are not the only underlying cause.

Adult forms of LVNC are genetically distinct from X-linked infantile cases in that mutations in the G 4.5 gene were not found to be the underlying mechanism. They are suggested to be transmitted by an autosomal dominant trait.<sup>13</sup> This is based on the observations that about one half of descendants of patients with LVNC inherit the condition and, furthermore, that cases of male to male transmission occur and that the disorder may occur in females. The adult LVNC population described by Sasse-Klaassen et al,<sup>14</sup> had no typical signs of Barth syndrome. LVNC in adults is a distinct entity without the extracardiac manifestations seen in children. Interestingly, familial recurrence seems to be more common in adult patients with LVNC than in paediatric populations

### **Clinical Manifestations**

The major clinical manifestations in patients with LVNC with reduced systolic left ventricular function are 1. Heart failure 2. Arrhythmias 3. Systemic embolic events.<sup>15</sup>

The diagnosis of LVNC was often delayed; in the cohort presented by Ritter et al,<sup>16</sup> the mean time elapsed from onset of symptoms to correct diagnosis was 3.5 (5.7) years.

In the cohort with LVNC described in the initial report by Chin et al,<sup>3</sup> depressed ventricular systolic function was noted in 63% of patients. In a population of Japanese children with LVNC followed for up to 17 years, left ventricular dysfunction developed in the vast majority, regardless of the presence or absence of symptoms at initial diagnosis.<sup>13</sup>

Arrhythmias are common in patients with LVNC. Atrial fibrillation has been reported in over 25% of adults with LVNC.<sup>9-16</sup> Ventricular tachyarrhythmias have been reported in as many as 47%. Sudden cardiac death accounted for half of the deaths in the larger series of patients with LVNC.<sup>9-17</sup> Although ventricular arrhythmias occurred in nearly 40% of patients in the initial description of LVNC by Chin et al,<sup>3</sup> Ichida<sup>13</sup> et al described no cases of ventricular tachycardia or sudden death in the largest series of pediatric patients with LVNC. Paroxysmal supraventricular tachycardia and complete heart block have also been reported in patients with LVNC<sup>13</sup> Oechslin et al<sup>9</sup> described left bundle branch block in 44% of adult patients with LVNC, but the reported incidence in children was much lower in another study.<sup>13</sup> Electrocardiographic findings of the Wolff-Parkinson-White syndrome have been described

in up to 15% of pediatric patients,<sup>13-18</sup> but it was not observed in the 2 largest series of adults with isolated noncompaction.<sup>9-16</sup>

The occurrence of thromboembolic events, including cerebrovascular accidents, transient ischemic attacks, pulmonary embolism, and mesenteric infarction, ranged from 21% to 38%.<sup>9-16</sup> Embolic complications may be related to development of thrombi in the extensively trabeculated ventricle, depressed systolic function, or the development of atrial fibrillation.<sup>16</sup> An association between noncompaction and neuromuscular disorders has also been described,<sup>19</sup> with as many as 82% of patients having some form of neuromuscular disorder.

In a more recent publication, long-term follow up of 34 adult patients was reported by Oechslin et al,<sup>9</sup> Twenty-five (74%) patients were men, with a mean age at diagnosis of 42 (17) years. The most common reason for referral was heart failure in 21 patients (62%), followed by uncertain echocardiographic findings in 4 (12%) and palpitations in 2 patients (6%). Twenty seven patients (79%) presented with shortness of breath, with 22 patients (65%) being in New York Heart Association class I and II, and 12 patients (35%) being in class III and IV. Left ventricular ejection fraction in this cohort was 33 (13) %. Most patients (94%) had an abnormal ECG, with left bundle branch block being the most common abnormality (in 44% of the patients). Six (18%) patients had familial occurrence.

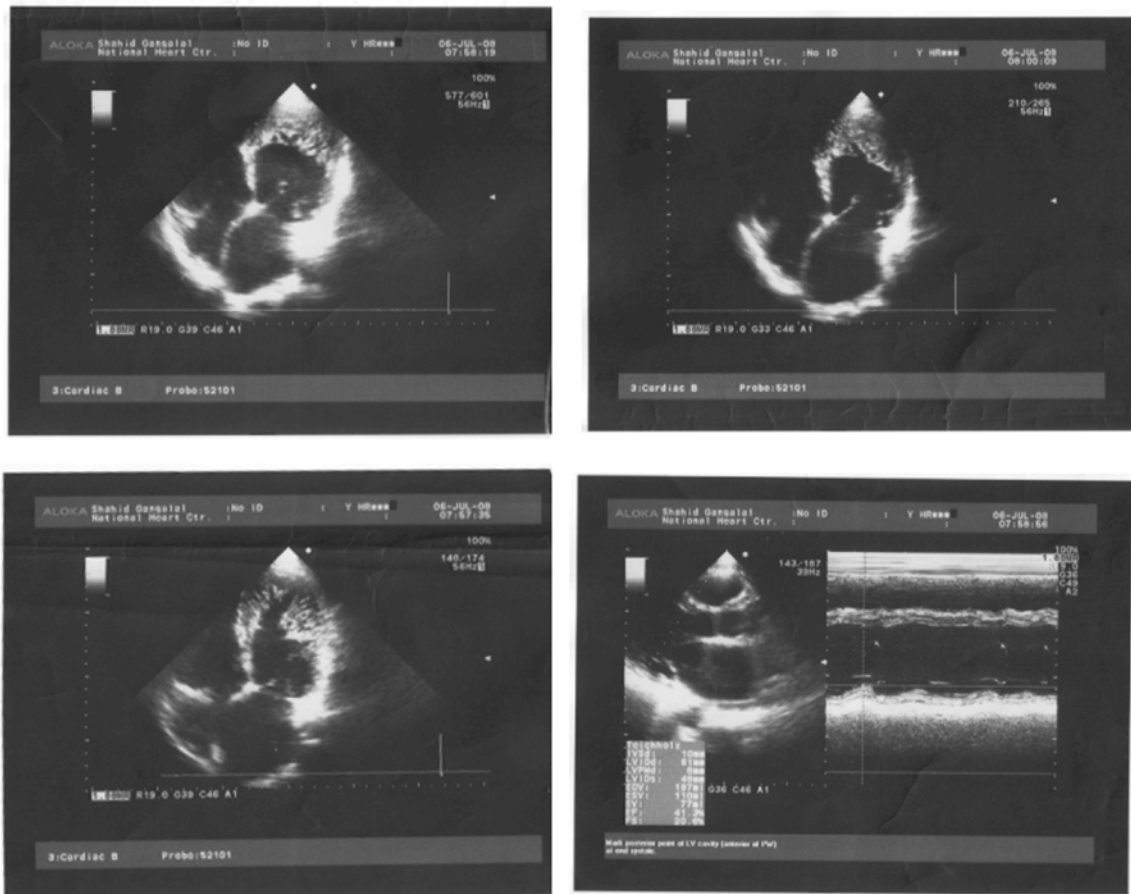
Lofiego et al,<sup>20</sup> studied 65 patients with LVNC and were followed up for 6–193 months (mean 46 (SD 44). In 53 (82%) patients, LVNC was associated with variable degrees of left ventricular (LV) dilatation and hypokinesia, and

in the remaining 12 (18%) LV volumes were normal. Diagnosis was symptom based in 48 (74%) and non-symptom based in 17 (26%) familial referral in 10. The non-symptom-based subgroup was characterised by younger age, lower prevalence of ECG abnormalities, better systolic function and lower left atrial size, whereas the extent of non-compaction was not different. No major cardiovascular events occurred in the non-symptom based group, whereas 15 of 48 (31%) symptomatically diagnosed patients experienced cardiovascular death or heart transplantation ( $p = 0.01$ )

### Diagnosis

Diagnosis is made with 2-dimensional Echocardiography, cardiac magnetic resonance imaging, or LV angiography. Echocardiography is considered the reference standard for the diagnosis of LVNC (Fig 1). Echocardiographic diagnostic criteria for LVNC included.

- 1 Absence of coexisting cardiac abnormalities (other than 2–4) by definition.
- 2 Typical two-layered structure of the myocardium with a thin, compacted outer (epicardial) band and a much thicker, non-compacted inner (endocardial) layer consisting of trabecular meshwork with deep endocardial spaces (the maximum end systolic ratio of the non-compacted endocardial layer to the compacted myocardium of  $>2$  is characteristic).
- 3 Predominant segmental location of the abnormality (that is, noncompacted myocardium is predominantly  $>80\%$  found in the apical and mid-ventricular areas of both the inferior and the lateral wall).
- 4 Color Doppler echocardiographic evidence of deeply perfused intertrabecular recesses



**Figure 1.** TTE of a 49 years old male with LVNC

contrasting with myocardial sinusoids, intertrabecular spaces do not communicate with the coronary circulation.

Cardiac MRI also has a role in the diagnosis, and can provide convincing evidence. MRI clearly has potential, especially in patients for whom good echocardiographic quality cannot be obtained. Another potential advantage of MRI is the possibility of identifying subendocardial perfusion deficits.<sup>22</sup> The CMR diagnostic criteria for LVNC included.<sup>23-24</sup>

- 1 The visual appearance of two distinct myocardial layers; a compacted epicardial layer and a non-compacted endocardial layer.
- 2 The presence of marked trabeculation and

deep intertrabecular recesses within the non-compacted layer.

- 3 A non-compacted to compacted myocardial ratio of  $>2.3$  as measured in end diastole in the long axis views.
- 4 The absence of other associated cardiac abnormalities.

In LV Angiography the typical features of LVNC have also been observed by ventriculography. After injection of contrast medium, a “honeycomb-like” or “loosened” structure of the inner left ventricular myocardium can be identified.<sup>25</sup> However, a left ventricular angiogram and coronary angiography are usually performed to rule out other concomitant cardiac abnormalities



and not for the diagnosis of LVNC.

### Treatment Options

Management of patients with LVNC is similar to that of patients with other cardiomyopathies and should therefore include appropriate treatment for heart failure, management of arrhythmias and oral anticoagulation to prevent systemic emboli in patients with impaired left ventricular function. Standard medical therapy for systolic and diastolic ventricular dysfunction is warranted. The beneficial effects of the  $\beta$ -blocker carvedilol on left ventricular function, mass, and neurohormonal dysfunction in an infant with LVNC have been described.<sup>26</sup> Cardiac transplantation has been used for those with refractory congestive heart failure. Implantation of an internal cardioverter defibrillator system has seriously to be considered. Prevention of embolic complications is also an important management issue, and several authors have recommended long-term prophylactic anticoagulation for all patients with ventricular non-compaction whether or not thrombus has been found.<sup>9-16</sup> Because of the familial association described with noncompaction, screening echocardiography of first degree relatives is recommended. Given the high percentage of associated neuromuscular disorders reported in patients with LVNC, neurological and musculoskeletal evaluations are also recommended.

### References

- 1 Freedom RM, Yoo SJ, Perrin D, et al. The morphological spectrum of ventricular noncompaction. *Cardiol Young* 2005;**15**:345–64. [16014180]
- 2 Sedmera D, Pexieder T, Vuillemin M, et al. Developmental patterning of the myocardium. *Anat Rec* 2000;**258**:319–37. [10737851]
- 3 Chin TK, Perloff JK, Williams RG, et al. Isolated noncompaction of left ventricular myocardium: a study of eight cases. *Circulation* 1990;**82**:507–13. [2372897]

### Prognosis

During the 6 year follow-up period of patients in the study by Ritter et al,<sup>16</sup> 8 of 17 patients died (three of them due to sudden cardiac death) and two underwent heart transplantation. In a larger series of patients, long-term follow up 44 months showed that 35% died, half of them because of sudden cardiac death, and 12% (four patients) had undergone heart transplantation.<sup>9</sup> The high incidence of both thromboembolic events (24%) and ventricular tachycardia (41%) in that series underscores the poor clinical prognosis for patients with impaired left ventricular function.<sup>13</sup> Because of the generally poor prognosis and because of the familial association of LVNC, first-degree relatives should be screened by echocardiography.

LVNC is a genetic cardiac disease of emerging importance with a distinct clinical and pathophysiological presentation. The diagnosis of LVNC, however, is often missed, most often as a consequence of ignorance of the condition. Echocardiography is considered the reference standard for the diagnosis of LVNC. Prognosis remains poor for patients with impaired systolic left ventricular function, as treatment options are very limited. Because of the familial association of LVNC, first-degree relatives should be screened by Echocardiography.

**Conflicts of Interest** no declare.

- 4 Engberding R, Bender F. Identification of a rare congenital anomaly of the myocardium by two-dimensional echocardiography: persistence of isolated myocardial sinusoids. *Am J Cardiol* 1984;**53**:17-33. [6731322]
- 5 Jenni R, Goebel N, Tartini R, et al. Persisting myocardial sinusoids of both ventricles as an isolated anomaly: echocardiographic, angiographic, and pathologic anatomical findings. *Cardiovasc Intervent Radiol*. 1986;**9**:27–31. [3089618]

- 6 Richardson P, McKenna W, Bristow M, et al. Report of the 1995 World Health Organization/ International Society and Federation of Cardiology task Force on the Definition and Classification of Cardiomyopathies. *Circulation* 1996;**93**:841–2. [8598070]
- 7 Barry J, Maron, Jeffrey A, Towbin, Gaetano Thiene et al. Contemporary Definitions and Classification of the Cardiomyopathies: *Circulation* 2006;**113**:1807–16. [16567565]
- 8 Nugent AW, Daubeney PEF, Chondros P, et al. The epidemiology of childhood cardiomyopathy in Australia. *N Engl J Med* 2003;**348**:1639–46. [12711738]
- 9 Oechslin EN, Attenhofer-Jost C, Rojas JR, et al. Long-term follow-up of 34 adults with isolated left ventricular noncompaction: a distinct cardiomyopathy with poor prognosis. *J Am Coll Cardiol* 2000;**36**:493–500. [10933363]
- 10 Pignatelli RH, McMahon CJ, Dreyer WJ, et al. Clinical characterization of left ventricular noncompaction in children. *Circulation* 2003;**108**:2672–8. [14623814]
- 11 Weiford BC, Subbarao VD, Mulhern KM. Noncompaction of the ventricular myocardium. *Circulation* 2004;**109**:2965–71. [15210614]
- 12 Ichida F, Tsubata S, Bowles KR, et al. Novel gene mutations in patients with left ventricular noncompaction or Barth syndrome. *Circulation* 2001;**103**:1256–63. [11238270]
- 13 Ichida F, Hanamichi Y, Miyawaki T, et al. Clinical features of isolated noncompaction of the ventricular myocardium: long-term clinical course, hemodynamic properties, and genetic background. *J Am Coll Cardio*. 1999;**34**:233–40. [10400016]
- 14 Sasse-Klaassen S, Gerull B, Oechslin E, et al. Isolated noncompaction of the left ventricular myocardium in the adult is an autosomal dominant disorder in the majority of patients. *Am J Med Genet* 2003;**119A**:162–7. [12749056]
- 15 Agmon Y, Connolly HM, Olson LJ, et al. Noncompaction of the ventricular myocardium. *J Am Soc Echocardiogr* 1999;**12**:859–863. [10511656]
- 16 Ritter M, Oechslin E, Sutsch G, et al. Isolated noncompaction of the myocardium in adults. *Mayo Clin Proc* 1997;**72**:26–31. [9005281]
- 17 Rigopoulos A, Rizos IK, Aggeli C, et al. Isolated left ventricular noncompaction: an unclassified cardiomyopathy with severe prognosis in adults. *Cardiology* 2002;**98**:25–32. [12373044]
- 18 Yasukawa K, Terai M, Honda A, et al. Isolated noncompaction of ventricular myocardium associated with fatal ventricular fibrillation. *Pediatr Cardiol* 2001;**22**:512–4. [11894157]
- 19 Stollberger C, Finsterer J, Blazek G. Left ventricular hypertrabeculation/noncompaction and association with additional cardiac abnormalities and neuromuscular disorders. *Am J Cardiol* 2002;**90**:899–902. [12372586]
- 20 Lofiego C, Biagini E, Pasquale F, et al. Wide spectrum of presentation and variable outcomes of isolated left ventricular non-compaction. *Heart* 2007;**93**:65–71. [16644854]
- 21 Jenni R, Oechslin EN, Van der Loo B. Isolated ventricular non-compaction of the myocardium in adults. *Heart* 2007;**93**:11–5. [16670098]
- 22 Soler R, Rodriguez E, Monserrat L, et al. MRI of subendocardial perfusion deficits in isolated left ventricular noncompaction. *J Comput Assist Tomogr* 2002; **26**:373–375. [12016366]
- 23 Peterson SE, Selvanayagam JB, Weissman F, et al. Left ventricular non-compaction: insights from cardiovascular magnetic resonance imaging. *J Am Coll Cardiol* 2005;**46**:101–5. [15992642]
- 24 Duncan RF, Brown MA, Worthley SG. Increasing identification of isolated left ventricular non-compaction with cardiovascular magnetic resonance: a mini case series highlighting variable clinical presentation. *Heart Lung Circ*. 2008;**17**:9–13. [17683984]
- 25 Jenni R, Goebel N, Tartini R, et al. Persisting myocardial sinusoids of both ventricles as an isolated anomaly: echocardiographic, angiographic, and pathologic anatomical findings. *Cardiovasc Intervent Radiol* 1986;**9**:127–31. [3089618]
- 26 Toyono M, Kondo C, Nakajima Y, et al. Effects of carvedilol on left ventricular function, mass, and scintigraphic findings in isolated left ventricular non-compaction. *Heart*. 2001;**86**:E4. [11410581]