

## Right coronary artery-to-pulmonary artery fistula, the role of echocardiography

M Esmailzadeh<sup>1</sup>, A Khaledifar<sup>1</sup>, A Usefi<sup>2</sup>, Gh Omrani<sup>3</sup>

1. Department of Echocardiography, 2. General Cardiology, 3. Cardiac Surgery, Shaheed Rajaie Heart Center, Tehran, Iran

Coronary artery fistula is an uncommon but hemodynamically significant anomaly of the coronary arteries, occurring as an incidental finding in 0.1% to 0.2% of coronary angiograms. Although half of the patients with a coronary artery fistula remain asymptomatic, the other half develops CHF, infective endocarditis, myocardial ischemia, or rupture of an aneurysm. This report is illustrative of the right coronary artery fistula to the right pulmonary artery in a 57-year-old male. The definitive diagnosis was made during transesophageal echocardiography and confirmed at operation.

**Keywords:** Coronary artery fistula; Transesophageal echocardiography; Pulmonary artery

### Introduction

Coronary artery fistula is an uncommon but hemodynamically significant anomaly of the coronary arteries occurring as an incidental finding in 0.1% to 0.2% of coronary angiograms<sup>1</sup>. It can be defined as a direct communication between a coronary artery and a cardiac chamber, as well as great vessel, or other vascular structures. The number, origin and course of the coronary arteries are otherwise normal. Several complications, including acute myocardial infarction, congestive heart failure, infective endocarditis and angina pectoris, were reported in patients with coronary artery fistulas. Herein, we describe a case of a fistula between the right coronary artery (RCA) and the right pulmonary artery (RPA). In addition, an overview of the current literature and

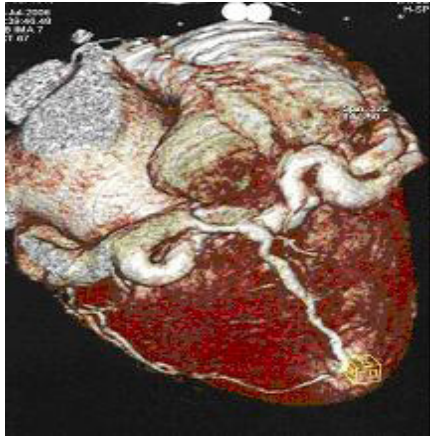
a delineation of the management of the coronary artery fistulas will be given.

### Case Report

A 57-year-old male with a history of hypertension, during the last 3 years was repeatedly admitted for acute coronary syndrome. The ECG showed an atrial fibrillation rhythm, ST segment depression with negative T waves in left precordial, and Q wave in inferior leads. Chest radiography demonstrated cardiomegaly with pulmonary congestion. On clinical examination there was a soft and variable S<sub>1</sub> and S<sub>2</sub>, a holodiastolic murmur at the 2<sup>nd</sup> intercostal space and a continuous cardiac murmur at LSB. Coronary angiography performed on another medical center showed significant lesion of proximal third of the left anterior descending artery (LAD), severe ectasia of RCA and right coronary fistula to an undetermined cavity. The left circumflex artery (LCX) was not visualized.

### Correspondence:

Maryam Esmailzadeh, MD, Shaheed Rajaie Heart Center, Tehran, Iran. Tel: 0098 21 2392524; Fax: 0098 21 22055594; E-mail: meszadeh@rhc.ac.ir,

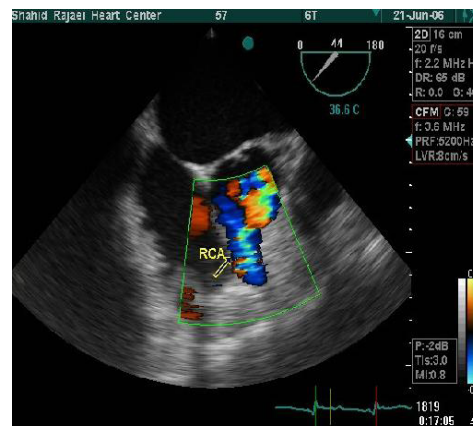


**Figure 1:** CT angiography demonstrating dilated and ectatic right coronary artery.

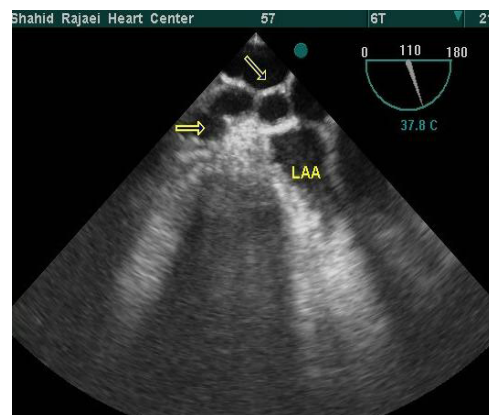
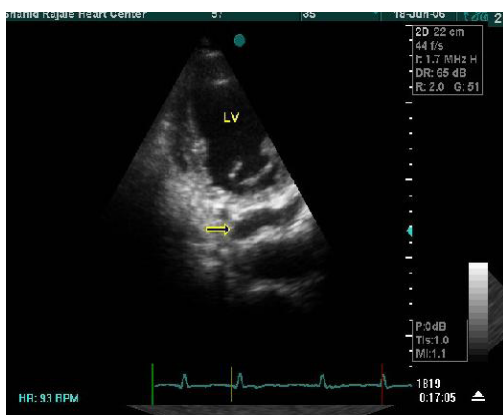CT angiography also showed ectatic RCA but could not be helpful in diagnosis of receiving chamber (Fig. 1).

The left coronary artery ostium and proximal LAD and LCX were normal on transthoracic (TTE) and transesophageal (TEE) echocardiography. The RCA was severely dilated (8-9mm) and tortuous (Fig. 2) and appeared as multiple giant convoluted loops around left atrial appendage and coronary sinus (Fig. 3). There was severe LV dilation with moderate astolic dysfunction (restrictive pattern) and significant regional wall motion abnormality (anterior circulation).

Other findings included moderate mitral regurgitation, partially flail aortic valve with severe aortic regurgitation, mild to moderate tricuspid regurgitation, and moderate to severe pulmonary hypertension (systolic pulmonary artery pressure=67 mmHg). A continuous turbulent flow in the proximal right pulmonary artery (RPA) was suggestive of RCA to RPA fistula (Fig. 4). The patient underwent cardiac surgery for coronary artery bypass grafting, aortic valve replacement and fistula closure. At operation, the fistula was found to drain into the right pulmonary artery and was ligated successfully. The post operative course was uneventful and patient discharged after 2 weeks.



**Figure 3:** Transesophageal view demonstrating severely dilated RCA with turbulent flow by color Doppler flow.



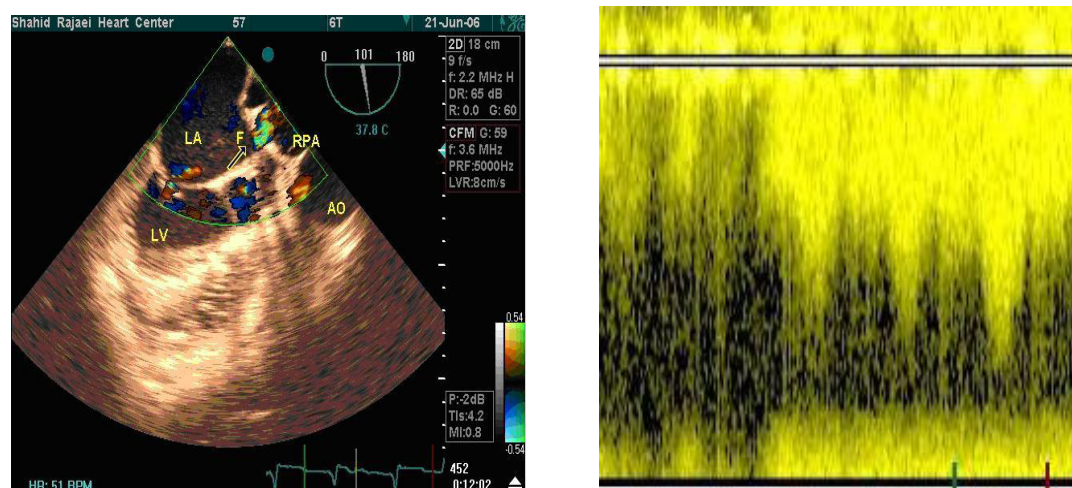
**Figure 2:** Transthoracic (Left) and transesophageal (Right) views revealed dilated and tortuous RCA which appeared as multiple giant convoluted loops around left atrial appendage and coronary sinus (arrows).

## Discussion

The main coronary arteries arise from the base of the truncus arteriosus. Coronary artery fistulas may develop upon enlargement of the capillary network during the embryogenesis or when the main coronary arteries remained attached to the pulmonary trunk at the time of their separation<sup>2</sup>. Fifty-two, 25, and 18 percent of Coronary artery fistula originates from the right coronary artery, left anterior descending artery and circumflex artery respectively<sup>1</sup>. Coronary angiography is the gold standard for the diagnosis of multiple abnormalities found in 5% of cases<sup>1</sup>, but transthoracic and trans-

esophageal echocardiography, and echo-Doppler have also been employed<sup>3,4</sup>. There is a general consensus about performing surgery in symptomatic patients, as in our case, those with heart failure or with angina, and in patients with large shunts greater than 1.5:1.

The prevalence rate of coronary artery fistulas detected during routine diagnostic coronary angiography is very low. Although coronary angiography is the gold standard for the diagnosis but echocardiography is very useful for the diagnosis of draining chamber.



**Figure 4:** Transesophageal view showing continuous turbulent flow of RCA to right pulmonary artery fistula.

**Abbreviation:** RCA; right coronary artery, RPA; right pulmonary artery, LA; left atrium, AO; aorta, LV; left ventricle

## References

- 1 Fernandes ED, Kadivar H, Hallman GL, et al. Congenital malformations of the coronary arteries: the Texas Heart Institute experience. *Ann Thorac Surg* 1992;**54(4)**:732-40.
- 2 O'Connor WN, Cash JB, Cottrill CM, et al. Ventriculocoronary connections in hypoplastic left hearts: an autopsy microscopic study. *Circulation* 1982;**66(5)**:1078-86.
- 3 Reeder GS, Taijk AJ, Smith HC. Visualization of coronary artery fistula by two-dimensional echocardiography. *Mayo Clin Proc* 1980;**55(3)**:185-189.
- 4 Prewitt KC, Smolin MR, Coster TS, Vernalis MN, Bunda M, Wortham DC. Coronary artery fistula diagnosed by transesophageal echocardiography. *Chest* 1994;**105(3)**:959-961.