

Curvularia Keratomycosis after Cataract Surgery

Inam Danish Khan,^{1*} Anuradha Makkar,² Ajay Malik,³ Shazia Khan,⁴ Imran Mehdi,⁵ Samreen Arif,⁶

Durre Aden,⁷ Prarthana Somayaji,⁸ and Khushnood Roomi⁹

¹MBBS, MD, DNB, Assistant Professor (Clinical Microbiology and Infectious Diseases), Army College of Medical Sciences and Base Hospital, Delhi Cantt 110010 India

²Professor and Head Microbiology, Army College of Medical Sciences and Base Hospital, Delhi Cantt 110010 India

³Professor and Head Pathology, Army College of Medical Sciences and Base Hospital, Delhi Cantt 110010 India

⁴MBBS, MS, Specialist Obstetrics and Gynecology, INHS Kalyani, Visakapatnam, India

⁵MBBS, MS, Specialist Ophthalmology, Army Hospital Research and Referral, Delhi, India

⁶MBBS, MS, Specialist Ophthalmology, Bhopal Memorial Hospital and Research Centre, Bhopal, India

⁷MBBS, MD, Specialist Pathology, Jawaharlal Nehru Medical College, Aligarh Muslim University, Aligarh, India

⁸PhD, Botanist, Bengaluru, India

⁹Chemist and Area Manager, Hafele Saudi Arabia, Mecca, Saudi Arabia

*Corresponding author: Dr Inam Danish Khan, MBBS, MD, DNB, Assistant Professor (Clinical Microbiology and Infectious Diseases), Army College of Medical Sciences and Base Hospital, Delhi Cantt 110010 India. Tel: +91-9836569777, Fax: +91-1125693490, E-mail: titan_afmc@yahoo.com

Received 2016 December 05; Revised 2017 February 14; Accepted 2017 March 13.

Abstract

Introduction: *Curvularia* is an emerging dematiaceous/melanized/phaeoid hyphomycete causing ocular curvulariosis including keratomycosis, conjunctivitis, dacryocystitis, sino-orbital cellulitis, and endophthalmitis. *Curvularia* keratomycosis may be associated with satellite stromal infiltrates, immune rings, Descemet's folds, iriditis, and endothelial plaque. Surgical trauma followed by delayed tissue healing may render cornea susceptible to invasion by exogenous air-dispersed conidia from environment.

Cases Presentation: *Curvularia lunata* keratomycosis occurred in 2 military veterans after phacoemulsification and intraocular lens implantation without any history of trauma. Topical 5% natamycin was effective for treatment resulting in minimal residual scar. Complete recovery and uneventful 1-year follow-up period was observed.

Conclusions: Seven out of 30 *Curvularia* species are emerging as opportunistic human pathogens from being primary phytopathogens. With increasing ocular surgeries in the diabetic populace amongst general population including military veterans, a high index of clinical and microbiological suspicion is required for optimal diagnosis of emerging pathogens in post-operative keratomycosis.

Keywords: Keratomycosis, Cataract Surgery, *Curvularia lunata*

1. Introduction

Curvularia is an emerging dematiaceous/melanized/phaeoid hyphomycete causing ocular curvulariosis including keratomycosis, conjunctivitis, dacryocystitis, sino-orbital cellulitis, and endophthalmitis. Seven out of 30 species are emerging as opportunistic human pathogens from being primary phytopathogens. The emergence of *C. lunata* in clinical specimens, frequently from corneal scrapings, makes it a significant ocular pathogen. *Curvularia* keratomycosis may be associated with satellite stromal infiltrates, immune rings, Descemet's folds, iriditis, and endothelial plaque. Exophytic inflammatory fungal sequestration, hypopyon, or perforation are not common (1-3). We report 2 cases of mycotic keratitis due to *Curvularia lunata*.

2. Case Presentation

2.1. Case 1

C. lunata was isolated from corneal scraping from an 80 year old male military veteran presenting with pain, watering, photophobia, and reducing vision 3 months after

phacoemulsification and intraocular lens implantation of the right eye. There was chronic history of diabetes mellitus but no history of ocular trauma. Examination revealed lid oedema, conjunctival congestion, visual acuity of 20/50 (counting fingers) in the right eye, and presence of a corneal opacity with diffuse infiltration covering entire cornea (Figure 1). Anterior chamber was well formed and the pupil was central, circular and sluggishly reacting to light. Posterior chamber examination revealed pseudophakia in situ. Fundus was unremarkable. Intraocular pressure was 14 mm by applanation tonometry. Left eye examination was normal. No suppuration or hypopyon was seen. Direct microscopic examination of corneal scraping revealed hyaline branched septate hyphae without arthroconidia on 10% potassium hydroxide mount. Gram stain and Giemsa stain were not contributory. Cultures on blood and chocolate agar at 37°C revealed growth of effuse grey colonies, which was subcultured on plain Sabouraud's dextrose agar at 25°C (HiMedia Laboratories, India). Microscopically, branched septate, hyaline to brown hyphae, slightly curved conidia with 3 septa, curved swollen large subterminal cell were seen (Figure 2). The identification

was confirmed from local mycology reference centre. Topical therapy with 5% natamycin over 6 weeks led to clinical improvement and recovery, although with minimal residual scarring of cornea. A 1-year follow-up period remained uneventful.

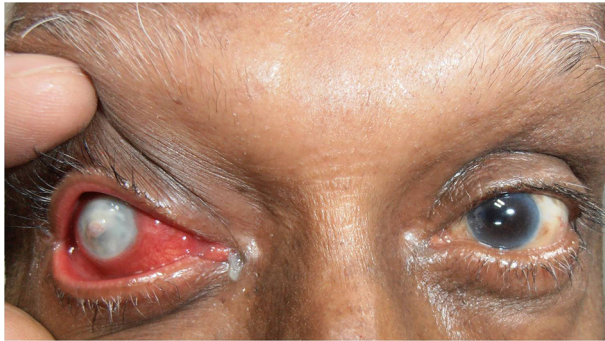

Figure 1. Right Eye Revealing Well Localized Whitish Infiltrate with Surrounding Edema Covering Entire Cornea.

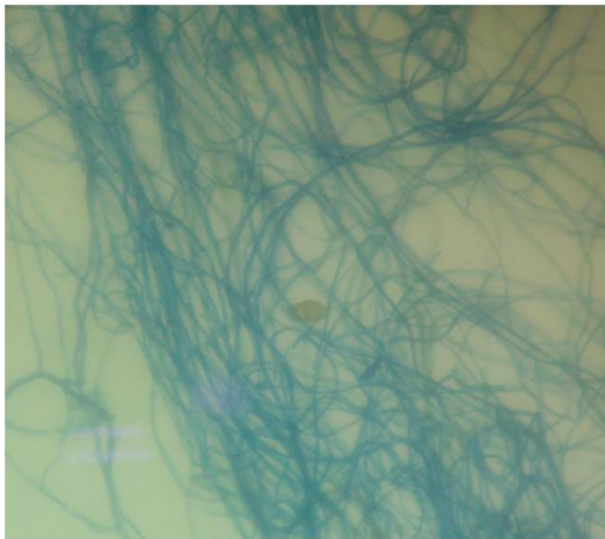


Figure 2. Macroconidia of *Curvularia lunata* Obtained from Culture Isolation on Sabouraud's Dextrose Agar

2.2. Case 2

C. lunata was isolated from culture of corneal scraping from a 64-year-old male military veteran reporting with pain, watering, photophobia, and partial loss of vision in right eye, 2 months after a successful cataract surgery. There was no history of ocular trauma, other eye diseases or diabetes mellitus in the past. Examination revealed conjunctival congestion, visual acuity of 20/30 in the right eye,

and presence of a corneal ulcer with diffuse infiltration covering less than a third of cornea. Slit lamp examination revealed a well-localized white infiltrate of approximately 3×5 mm mainly occupying the inferior part of cornea involving the visual axis with surrounding edema and an overlying epithelial defect of about 4×6 mm. The fungus was identified and managed as in Case 1. Complete recovery and uneventful 1-year follow-up period was observed.

3. Discussion

Keratomycosis caused by *Fusarium*, *Aspergillus*, *Curvularia*, and *Candida* continues to be an important cause of ocular morbidity in tropical and subtropical developing countries. Trauma involving exposure to plants, animals or dust particles, immunological incompetence, allergic conjunctivitis, exposure to corticosteroids, antibacterials, contact lenses, and foreign bodies in conjunctiva predispose to keratitis (1-4). Keratitis occurs through direct implantation of conidia in the corneal stroma or erosion of the epithelium leaving it susceptible to invasion by exogenous fungi from environment. Mycotic keratitis may progress rapidly due to activation of resident corneal cells or polymorphonuclear leucocytes, which release proteinases resulting in extensive degradation of the corneal matrix. Fungal invasiveness is promoted by proteinases, toxins, and formation of intrahyphal hyphae. Melanized fungi such as *Curvularia* contain dihydroxynaphthalene melanin, which acts as a virulence factor while giving dark pigmentation to hyphae and conidia. They are extremely resistant to free radicals, toxic metals, desiccation, and ionizing radiation. Conidia are adapted for aerial dispersal making them components of air mycobiota with worldwide distribution. Telomorphs are included in the ascomycete genus *Cochliobolus* (3, 5).

Curvularia may surpass routine laboratory identification and be discarded as contaminant fungus as it rapidly grows on routine laboratory media along with bacteria (Figure 2). Culture based isolation and micromorphology from scrapings or biopsy of corneal epithelium remain the cornerstone of diagnosis as key diagnostic features are not seen on direct mounts from clinical material. *Curvularia lunata* has 3 large dark transversely cross-walled truly septate, straight, ellipsoidal, fusiform or pyriform symphyoidal geniculate poroconidia, 18 to 27 μm long, and 8 to 11 μm wide at the broadest part, with dark basal protuberant hila. Dematiaceous/melanized/phaeoid hyphae produce brown, geniculate conidiophores. *Curvularia* may produce grey to dark colonies on agar media although fungal elements may appear hyaline to brown with varying morphological features in tissues. Masson's Fontana stain is melanin specific. Cultures on cycloheximide free

media may provide features for correct identification. Exposure to polyene antifungals can distort the shape and color of the isolate. No immunological tests are available; however panfungal polymerase chain reaction and mitochondrial small subunit ribosomal RNA can be used for sequencing of ribosomal genes. Molecular methods are resource intensive and may not be available/feasible/cost effective for single isolates in medium sized laboratories. Temporal and procedural complexity in culture-based and molecular-targeted fungal diagnostics call for opportunities in developing rapid kits and addressing pre- and post analytical variables (6, 7).

Topical 5% natamycin, 0.15% amphotericin B, or 1% itraconazole can be augmented with systemic amphotericin B, fluconazole, itraconazole, voriconazole as there may be limited penetration into corneal tissue. *Curvularia* has higher in vitro MIC₅₀ and MIC₉₀ for fluconazole, voriconazole, and flucytosine compared to natamycin and amphotericin B; however, caspofungin is effective (1, 8, 9). Most isolates are susceptible to natamycin, despite continuous use of the drug. Antifungal resistance is emerging in secondarily transmitted fungi exposed to hospital environments (10-12). Biocides such as polyhexamethylene biguanide and chlorhexidine gluconate also inhibit *Curvularia*.

Topical saturation therapy and around the clock hourly topical therapy can be tapered over a few days for superficial keratitis. Clinical improvement includes reduction of pain, decrease in size of infiltrate, disappearance of satellite lesions, rounding off of feathery margin of the ulcer, and fibrosis of healing lesions. Biomicroscopic prognosis is done by evaluating edge of infiltrate, density of suppuration/hypopyon, stromal cellular infiltrate, and oedema (3, 4). Conjunctival chemosis as well as injection and punctate epithelial keratopathy may indicate toxicity of the antifungal agent. Negative culture from scrapings during treatment may be false negative as active proliferation may continue in the stroma due to poor drug penetration. Therapy should be continued for at least 6 weeks. Infections with multiresistant fungi may lead to delayed healing and/or failure of therapy warranting surgical intervention. Bacterial co-infection needs to be excluded (2, 5).

Curvularia species have been implicated in cases of systemic infections such as endocarditis, peritonitis, urinary, pulmonary, cerebral, and disseminated infections. It can also cause liver, spleen, and brain abscess. Subcutaneous infections include keratitis, allergic or invasive sinusitis, allergic bronchoalveolar disease, phaeohyphomycotic cyst, leg ulcer, and mycetoma. Superficial infections include onychomycosis and dermatomycosis. Outbreaks in silicon breast implants, intraocular lenses, and contact lenses have

been reported. Dialysis related peritonitis, dialysis tube block and postsurgical endocarditis might be healthcare associated infections (3).

The 2 cases of *Curvularia* acquired from environmental sources without obvious trauma represents transmission of the pathogen through air-dispersed conidia, which has been scantily reported in literature. Surgical trauma followed by reduced local immunity and avascular nature of cornea may render it susceptible to invasion by exogenous emerging opportunistic pathogens from environment. Prevention entails reducing exposure to atmospheric pollutants containing fungal elements of *Curvularia* and other pathogenic fungi. Military veterans may need to be sensitized against potential ocular pathogens post ocular surgery. With increasing ocular surgeries in the immunocompromised, a high index of clinical and microbiological suspicion is required for optimal diagnosis of novel pathogens in keratomycosis (13).

Footnotes

Authors' Contribution: The author was the clinical microbiologist investigating the patient.

Conflicts of Interest: No conflicts of interest

Ethical Approval: The institutional committee covered the patient consent and ethical approval.

Funding/Support: None.

References

- Gopinathan U, Garg P, Fernandes M, Sharma S, Athmanathan S, Rao GN. The epidemiological features and laboratory results of fungal keratitis: a 10-year review at a referral eye care center in South India. *Cornea*. 2002;**21**(6):555-9. [PubMed: 12131029].
- Mann SS, Singh J, Kalra D, Parihar J, Gupta N, Kumar P. Medical and Surgical Management of Keratomycosis. *Med J Armed Forces India*. 2008;**64**(1):40-2. doi: 10.1016/S0377-1237(08)80144-X. [PubMed: 27408078].
- Wilhelmus KR, Jones DB. *Curvularia* keratitis. *Trans Am Ophthalmol Soc*. 2001;**99**:111-30. [PubMed: 11797300] discussion 130-2.
- Chowdhary A, Singh K. Spectrum of fungal keratitis in North India. *Cornea*. 2005;**24**(1):8-15. [PubMed: 15604861].
- Ho JW, Fernandez MM, Rebong RA, Carlson AN, Kim T, Afshari NA. Microbiological profiles of fungal keratitis: a 10-year study at a tertiary referral center. *J Ophthalmic Inflamm Infect*. 2016;**6**(1):5. doi: 10.1186/s12348-016-0071-6. [PubMed: 26897131].
- Khan ID, Gupta N, Rangan NM, Singh R, Sharma AK, Khurana A, et al. Evaluation of pre and post analytical variables in clinical microbiology services in multidisciplinary icu of a medical college and tertiary care hospital. *J Basic Clin Med*. 2016;**5**(1).
- Khan ID. Rapid Diagnosis of Dengue Outbreaks in Resource Limited Facilities. Anchor Academic Publishing; 2016.
- Lalitha P, Sun CQ, Prajna NV, Karpagam R, Geetha M, O'Brien KS, et al. In vitro susceptibility of filamentous fungal isolates from a corneal ulcer clinical trial. *Am J Ophthalmol*. 2014;**157**(2):318-26. doi: 10.1016/j.ajo.2013.10.004. [PubMed: 24439440].

9. Guarro J, Akiti T, Horta RA, Morizot Leite-Filho LA, Gene J, Ferreira-Gomes S, et al. Mycotic keratitis due to *Curvularia senegalensis* and in vitro antifungal susceptibilities of *Curvularia* spp. *J Clin Microbiol.* 1999;37(12):4170-3. [PubMed: [10565956](#)].
10. Khan ID, Sahni AK, Bharadwaj R, Lall M, Jindal AK, Sashindran VK. Emerging organisms in a tertiary healthcare set up. *Med J Armed Forces India.* 2014;70(2):120-8. doi: [10.1016/j.mjafi.2013.09.005](#). [PubMed: [24843199](#)].
11. Khan ID, Sahni AK, Basu A, Haleem S. Trichosporon asahii urinary tract infection in immunocompetent patients. *Med J Armed Forces India.* 2015;71(4):373-6. doi: [10.1016/j.mjafi.2014.08.013](#). [PubMed: [26663967](#)].
12. Jindal AK, Pandya K, Khan ID. Antimicrobial resistance: A public health challenge. *Med J Armed Forces India.* 2015;71(2):178-81. doi: [10.1016/j.mjafi.2014.04.011](#). [PubMed: [25859082](#)].
13. Khan ID, Sati A, Arif S, Mehdi I, Bhatt P, Jain V, et al. Streptococcus Mitis/Oralis Corneal Ulcer After Corneal Transplantation. *J Basic Clin Med.* 2016;5(1).