

Brief Communication

Extensive Hematoma in a Patient with Hereditary Hypersegmentation of Neutrophils

Akbar Dorgalaleh^{1*}, Behnaz Tavasoli¹, Shadi Tabibian¹, Golbahar Majid¹, Shahrzad Souri¹, Mahmood Shams¹, Jamal Rashidpanah², Fereshteh Firoozkahi²

Abstract

Hypercoagulable states are a group of conditions associated with an enhanced tendency toward blood clotting. Although usual clinical manifestations of hypercoagulable states are thrombotic events such as deep venous thrombosis, hematoma can also occur as a result of hypercoagulability in some patients. Several inherited or acquired conditions may lead to hypercoagulable states. Some of them include myeloproliferative syndromes, over activity of coagulation factors and methyl tetrahydrofolate reductase (MTHFR) polymorphisms. MTHFR is required for converting the amino acid homocysteine to methionine. Another significant role of an aptly functioning MTHFR enzyme is nucleic acid biosynthesis. Therefore MTHFR polymorphisms are expected to be associated with hypersegmentation of neutrophils because of a defect in DNA metabolism. Neutrophil hypersegmentation is one of the most sensitive hematological features of cobalamin or folate deficiency with normal serum vitamin B12-folic acid and iron levels. Hypersegmentation of neutrophils and hematoma or both of them suspected to be due to gene variations of MTHFR.

Here we report a 37-years old female who simultaneously affected by hereditary hypersegmentation and extensive hematoma. Laboratory analysis revealed normal serum vitamin B12, folic acid and iron levels. Routine and specific coagulation tests were normal in except of factor VIIIc that was high. Results of complete blood cell count (CBC) test were normal. Although this is just an idea, but simultaneous presentations of these two conditions can have a common origin.

Keywords: Hematoma, Neutrophil hypersegmentation, Hypercoagulability

Please cite this article as: Dorgalaleh A, Tavasoli B, Tabibian S, Majid G, Souri S, Shams M, Rashidpanah J, Firoozkahi F. Extensive Hematoma in a Patient with Hereditary Hypersegmentation of Neutrophils. *J Cell Mol Anesth.* 2016;1(3):109-14.

1. Department of Hematology and Blood Transfusion, School of Allied Medical Sciences, Iran University of Medical Sciences, Tehran, Iran
2. Tehran Heart Center (THC), Tehran University of Medical Sciences, Tehran, Iran

Corresponding Author:

Akbar Dorgalaleh. Department of Hematology and Blood Transfusion, School of Allied Medical Sciences, Iran University of Medical Sciences, Tehran, Iran.

Email: dorgalaleha@gmail.com

Received: April 4, 2016

Accepted: July 17, 2016

Introduction

Hypercoagulable states can be defined as a group of conditions associated with an enhanced tendency toward blood clotting in the veins

or arteries. Hypercoagulability, also known as thrombophilia, can result from several inherited and acquired conditions such as deficiencies in protein C, protein S, or antithrombin III, overactivity of

coagulation factors, antiphospholipid syndrome, inflammation and obesity (1-3). Polymorphisms of methylene tetrahydrofolate reductase (MTHFR) gene are also associated with an increased risk of heritable thrombophilia (4, 5). MTHFR gene produces the enzyme that plays an important role in amino acids processing, particularly the conversion of homocysteine to methionine. Two common polymorphisms in MTHFR gene including C677T and A1298C, lead to decreased enzyme activity and therefore elevation of homocysteine level. C677T exists in the MTHFR gene that encodes the catalytic domain of the MTHFR enzyme, in which a C>T substitution at position 677 results in a substitution of alanine to valine. The single amino acid substitution results in impaired folate binding and reduced activity of the MTHFR enzyme (6-8). Heterozygotes carrying this thermolabile variant have a reduced enzyme activity to 65% of normal, while homozygotes have only 30% of normal activity (9). It is found in homozygous state in 10% of the population and both forms of homozygotes and heterozygotes, cause elevated levels of plasma homocysteine (10). However usual clinical manifestations of hypercoagulable states are thrombotic events such as deep venous thrombosis (DVT) which are reported in associated with MTHFR polymorphisms (11), hematoma is also mentioned as a result of hypercoagulability in some patients. It is suggested that the presence of a hematoma may be the first

indicator of an underlying thrombophilia (12). MTHFR plays a central role in folate metabolism via converting 5,10-methylenetetrahydrofolate to 5-methylenetetrahydrofolate that is the primary circulating form of folate and is vital for DNA synthesis. Polymorphism in MTHFR and other genes which play a role in folate metabolism may lead to deficient DNA synthesis and probably to neutrophil hypersegmentation (13). Coexistence of MTHFR polymorphism and hypersegmented neutrophils was reported in patients with hemolysis and cobalamin deficiency (14).

Brief Report

A 37-years old female was refer with extensive hematoma of both forearms. Initially routine and a number of specific coagulation tests including prothrombin time (PT) and activated partial thromboplastin time (aPTT), protein C and protein S as well as antithrombin III (ATIII) activity were performed. Factor VIII activity (FVIII:C) also was measured. All of these tests were performed by ACL top 300-autoanalyzer (Instrumentation Laboratory, Milan, Italy) (Table 1).

Discussion

NPC is caused by mutations in one of the two genes called NPC1 or NPC2. 95% of cases have NPC1 mutation which encodes a large glycoprotein in

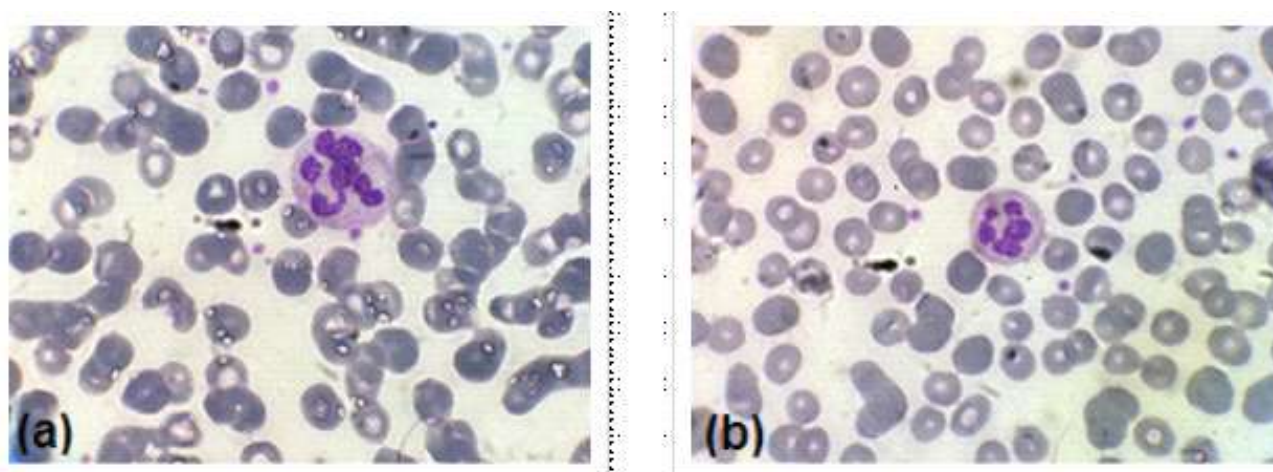


Fig. 1.Hypersegmented neutrophils in peripheral smear. (a) Patient blood smear. (b) Patient's mother blood film Examination of peripheral blood films of patient and her mother reveals 4% neutrophils with more than five nuclear lobes and 12% neutrophils, having five nuclear lobes in patient and 6% neutrophil with five nuclear lobes in patient's mother.

Table 1:Results of Routine and specific coagulation tests.

Test	Result	Normal range
PT	10.5	9.5-12.5 sec
aPTT	27.2	24.9-29.1 sec
FVIII:C	162	60-150 (%)
ATIII	100	80-120 (%)
PC	84%	70-140 (%)
PS	103	60-135.5 (%)
Fibrinogen	345	220-496

PT: Prothrombin time, aPTT: activated partial thromboplastin time, PS: **Protein S**, PC: **Protein C**, ATIII:Antithrombin III activity , FVIII:C: Factor VIII activity, Sec: seconds

late endosomal location. This gene mapped to chromosome 18q11-q12, spans 56 kbp and contains

25 exons. NPC2 encodes a small soluble lysosomal protein which binds cholesterol with high affinity (8). NPC2 mapped to chromosome 14q24.3, spans 13.5 Kbp and contains 5 exons. Deficiency in both types causes impairment in processing and utilization of endocytosed cholesterol (1, 8). The cellular hall mark of this disease is inability of cholesterol to transport from late endosomes to plasma membrane or reticulum endoplasmic therefore accumulation of cholesterol and products will occur (Figure 1) (1).

Therefore cholesterol storage is impeded and resulted in a different pattern of accumulation in neuronal and extra-neuronal tissues. These changes cause sphingomyelin metabolism alteration in extra neuronal tissues. Unesterified cholesterol, sphingomyelin, bisphosphate, glycolipids, and free sphingosine and sphinganine will accumulate in liver and spleen (1). In neurons, accumulation of Glycosphingolipids including GM2 and GM3 gangliosides occurs and cause meganeurite formation, growth of ectopic dendrites, neurofibrillary tangles

Table 2: Complete blood cell count (CBC) results of patients with extensive hematoma and heredity neutrophil hypersegmentation.

Index	Result	Unite	Interpretation
WBC	7000	/ul	Normal
RBC	3760000	/ul	Low
Hemoglobin	11.8	g/dl	Low
Hematocrit	33.6	%	Normal
MCV	89.4	fl	Normal
MCH	31.4	Pg	Normal
MCHC	35.1	g/dl	Normal
Platelet	192000	/ul	Normal
Neutrophil%	55%	%	Normal
Lymphocyte%	37%	%	Normal
Monocyte%	2%	%	Normal
Eosinophil%	3%	%	Normal

formation, neuroinflammation, and neuroaxonal dystrophy (8). On the other hand, some proteins like Rab9 or mannose-6-phosphate receptors transfer to cell membrane by late lysosomal system. Cholesterol accumulation could also impair this trafficking (1). Unexplainably neural death occurs mostly in Purkinje cells of the cerebellum. The function of these proteins are not defined yet so the exact mechanism and pathophysiology remains a mystery (1).

The only approved therapy for NPC so far is Miglustat (N-butyl-deoxynojirimycin). It is an iminosugar inhibitor of glucosylceramide synthase (1). This drug can stabilize the neurological manifestations including dysphagia (6). Miglustat by inhibiting glucosylceramide synthase reduce the synthesis of glucosylceramide-based glycosphingolipid in CNS (6). But long term clinical outcomes are still unclear (6). Other drugs used for symptom therapy including antiepileptic drugs (treatment of seizure), clomipramine, protriptyline, or modafinil (treatment of Cataplexy), anticholinergic agents (treatment of dystonia and tremor), Melatonin (treatment of insomnia). Physiotherapy for management of muscle spasticity and contracture is useful. As the major cause of mortality in these patients is aspiration pneumonia, the most important part of managing this disease is handling feeding abnormalities (1, 6). Current researches in the field of treating this disease is based on animal models mostly transgenic mice and cats and also testing various compounds like imatinib, curcumin, NSAIDs, neurosteroids (allopregnone) and 2-HP- β -cyclodextrin. The last compound showed significant improvement in disease natural history in animal models but needs further investigations (1).

The exact function of NPC genes are unknown therefore the pathophysiology of this disease is still a mystery (4). So the target metabolite in brain causing the neuroinflammatory responses remains unknown. These results are in lack of a biochemical blood test for evaluating prognosis or diagnosis (1, 4). Currently the gold standard for diagnosis is skin biopsy however recent advances suggest oxysterol profile as a biomarker for NPC. Although more researches are needed to define it as an indicator, these findings could change the future treatment and research developments (1, 4).

As mentioned above, NPC is a disease which involves multiple organs including central nervous system, respiratory system and gastrointestinal system (hepatosplenomegaly). Therefore this disease could interfere with routine anesthetic plans (3, 5). Restrictive lung disease arise from recurrent aspirations demand specific consideration in ventilator setup, so lower tidal volumes and increase in respiratory rate could be helpful for these patients. Another problem is the liver damage caused by storage of lipids, which needs careful selection of anesthetic drugs (5). Also hepatomegaly could accompany ascites which leads to decreased Functional Residual Capacity (3). there are some reports indicating the association between NPC and difficult airway therefore considering options for intubation would be wise (1). on the other hand, thrombocytopenia accompanied by this disease, could potentiate the risk of bleeding (1). Due to vigorous secretions anticholinergic drugs prior to anesthesia could improve the outcome of the procedure (3). It is demonstrated that hyperventilation plus high concentrations of Sevoflurane could induce seizures. Therefore to avoid this phenomenon continuing antiepileptic agents in perioperative period and use of TIVA instead of volatiles is recommended (3). The technique of choice is the one in which satisfactory condition for procedure is established rapidly and safely and also the recovery should be safe and predicted with minimal sequel for the patient (5).

Then a complete blood cell count (CBC) was performed using an automated counting device (Sysmex KX-21, SYSMEX, Japan). All blood cell indices were normal in except of a mild anemia with decreased red blood cell (RBC) count (Table 2).

All blood cell indices were normal except red blood cell (RBC) count and hemoglobin concentration. Both are less than the normal range. Patient was treated with folic acid and iron supplement for more than 3 months before laboratory analyses. The patient's serum vitamin B12, folic acid and homocysteine concentrations were 24.8pg/ml, 12.02ng/ml and 13 μ mol/l, respectively. All of them were in normal range according to age and sex. Serum iron was also measured in order to determine possible cause of neutrophil hypersegmentation. The serum iron was 80 μ g/dL, it was normal.

Conclusion

Neutrophil hypersegmentation is an expected finding in folate and vitamin B12 deficiency (15, 16). There are several reports about present of neutrophil hypersegmentation in patients with iron deficiency (17, 18). This female had neutrophil hypersegmentation with normal serum iron and folate as well as vitamin B12.

Normal gene variations in MTHFR gene can alter folate metabolism and subsequently defective DNA synthesis (13). In the other hand this common gene variations have a strong relationship with hypercoagulability and several studies showed various signs of hypercoagulable states in different patients (19, 20). Although hematoma is a common presentation in patients with bleeding but in hypercoagulable states hematoma was also reported (12, 21). A hematoma is a collection of blood, usually clotted, outside of a blood veins that may occur because of an injury to the wall of a blood veins allowing blood to leak out into tissues where it does not belong. The damaged blood vessel may be an artery, vein, or capillary (22-24).

In this patient only FVIII: C is moderately increased and other signs of hypercoagulability are absent but gene variations of MTHFR also can be accompanied by normal level of homocysteine in vascular events (25). In the current case, presence of heredity hypersegmentation can be suggestive of a defect in DNA metabolism. This defect in DNA synthesis can also provokes coagulation activity and therefore hypercoagulability associated presentations (26-28). Neutrophil hypersegmentation may also be accompanied by other conditions such as thrombocytosis that was reported with normal folate and vitamin B12 serum levels (17). Neutrophil hypersegmentation with folic acid deficiency was reported in pregnancy but this situation is transient and is solved several weeks after delivery (29). This case was not pregnant and her neutrophil hypersegmentation was not transient. Since neutrophil hypersegmentation is an autosomal dominant disorder (30) we assessed patient's mother for presence of hypersegmented neutrophils and we found 6% neutrophil with five nuclear lobes in her blood film (Figure 1). Neutrophil hypersegmentation is defined

as any neutrophil having six or more nuclear lobes or more than 3% of neutrophils having five nuclear lobes, when 100 neutrophils are examined (ICSH recommendations for the standardization of nomenclature and grading). This case emphasized that neutrophil hypersegmentation can be accompanied by hypercoagulability. This situation can be a genetically disorder or acquired state, but according to this case, this situation seems to be due to a gene defect in folate metabolism but further studies are required.

Acknowledgment

The authors would like to acknowledge the kind help of authorities and personnel in Department of Hematology and Blood Transfusion, School of Allied Medical Sciences, Iran University of Medical Sciences, Tehran, Iran and also, authorities, physicians and health care personnel in Tehran Heart Center (THC), Tehran University of Medical Sciences, Tehran, Iran for their kind help and support.

Conflicts of Interest

The authors declare that there are no conflicts of interest.

References

1. Ali N, Ayyub M, Khan SA. High prevalence of protein C, protein S, antithrombin deficiency, and Factor V Leiden mutation as a cause of hereditary thrombophilia in patients of venous thromboembolism and cerebrovascular accident. *Pakistan journal of medical sciences*. 2014;30(6):1323.
2. Samad F, Ruf W. Inflammation, obesity, and thrombosis. *Blood*. 2013;122(20):3415-22.
3. Martinelli I, Passamonti S, Bucciarelli P. Thrombophilic states. *Handbook of clinical neurology*. 2013;120:1061-71.
4. Gibson CS, MacLennan AH, Janssen NG, Kist WJ, Hague WM, Haan EA, et al. Associations between fetal inherited thrombophilia and adverse pregnancy outcomes. *American journal of obstetrics and gynecology*. 2006;194(4):947.
5. Den Heijer M, Lewington S, Clarke R. Homocysteine, MTHFR and risk of venous thrombosis: a meta-analysis of published epidemiological studies. *Journal of Thrombosis and Haemostasis*. 2005;3(2):292-9.
6. Fung MM, Salem RM, Lipkowitz MS, Bhatnagar V, Pandey B, Schork NJ, et al. Methylenetetrahydrofolate reductase (MTHFR) polymorphism A1298C (Glu429Ala) predicts decline in renal function over time in the African-American Study of Kidney Disease and Hypertension (AASK) Trial and Veterans Affairs Hypertension Cohort (VAHC). *Nephrology Dialysis Transplantation*. 2012;27(1):197-205.

7. Nazki FH, Sameer AS, Ganaie BA. Folate: metabolism, genes, polymorphisms and the associated diseases. *Gene*. 2014;533(1):11-20.
8. Yan J, Yin M, Dreyer ZE, Scheurer ME, Kamdar K, Wei Q, et al. A meta-analysis of MTHFR C677T and A1298C polymorphisms and risk of acute lymphoblastic leukemia in children. *Pediatric blood & cancer*. 2012;58(4):513-8.
9. Khaleghparast A, Khaleghparast S, Khaleghparast H. Evaluation of the Association between the C677T Polymorphism of Methylene tetrahydrofolate Reductase Gene and Recurrent Spontaneous Abortion. *Iranian Journal of Neonatology IJN*. 2014;5(1):7-11.
10. Garilli B, editor MTHFR mutation: A missing piece in the chronic disease puzzle. Summer; 2012.
11. Hosseini S, Kalantar E, Hosseini MS, Tabibian S, Shamsizadeh M, Dorgalaleh A. Genetic risk factors in patients with deep venous thrombosis, a retrospective case control study on Iranian population. *Thrombosis journal*. 2015;13(1):1.
12. Heller DS, Rush D, Baergen RN. Subchorionic hematoma associated with thrombophilia: report of three cases. *Pediatric and Developmental Pathology*. 2003;6(3):261-4.
13. Sharp L, Little J. Polymorphisms in genes involved in folate metabolism and colorectal neoplasia: a HuGE review. *American Journal of Epidemiology*. 2004;159(5):423-43.
14. Acharya U, Gau J-T, Horvath W, Ventura P, Hsueh C-T, Carlsen W. Hemolysis and hyperhomocysteinemia caused by cobalamin deficiency: three case reports and review of the literature. *J Hematol Oncol*. 2008;1:26.
15. Briani C, DallaTorre C, Citton V, Manara R, Pompanin S, Binotto G, et al. Cobalamin deficiency: clinical picture and radiological findings. *Nutrients*. 2013;5(11):4521-39.
16. Kaferle J, Strzoda CE. Evaluation of macrocytosis. *American family physician*. 2009;79.(*)
17. Duzgun S, Yildirmak Y, Çetinkaya F. Neutrophil hypersegmentation and thrombocytosis in children with iron deficiency anemia. *TURKISH JOURNAL OF PEDIATRICS*. 2005;47(3):251.
18. Westerman D, Evans D, Metz J. Neutrophil hypersegmentation in iron deficiency anaemia: a case-control study. *British journal of haematology*. 1999;107(3):512-5.
19. Ozkurt S, Temiz G, Saylisoy S, Soydan M. Cerebral sinovenous thrombosis associated with factor V Leiden and methylenetetrahydrofolate reductase A1298C mutation in adult membranous glomerulonephritis. *Renal failure*. 2011;33(5):524-7.
20. Kreidy R. Influence of acquired and genetic risk factors on the prevention, management, and treatment of thromboembolic disease. *International journal of vascular medicine*. 2014;2014.
21. Anno M, Yamazaki T, Hara N, Hayakawa K. Recurrent Postoperative Spinal Epidural Hematoma in a Patient with Protein S Deficiency. *Case reports in orthopedics*. 2015;2015.
22. Szolnoky G, Nagy N, Kovács R, Dósa-Rácz E, Szabó A, Bárony K, et al. Complex decongestive physiotherapy decreases capillary fragility in lipedema. *Lymphology*. 2008;41(4):161.
23. Dharsono F, Phatouros CC. Arterial origin subdural hematoma and associated pial pseudoaneurysm following minor head trauma. *Clinical imaging*. 2013;37(4):750-2.
24. Kahraman S, Kayali H, Atabey C, Acar F, Gocmen S. The accuracy of near-infrared spectroscopy in detection of subdural and epidural hematomas. *Journal of Trauma and Acute Care Surgery*. 2006;61(6):1480-3.
25. Gadiyaram V, Khan M, Hogan T, Altaha R, Crowell E, Hobbs G, et al. Significance of MTHFR gene mutation with normal homocysteine level in vascular events. *ASCO Annual Meeting Proceedings*; 2009.
26. Cappellini MD, Poggiali E. Hypercoagulability and thrombosis. *Thalassemia Reports*. 2013;3(1s):10.
27. Smalberg JH, Kruij MJ, Janssen HL, Rijken DC, Leebeek FW, de Maat MP. Hypercoagulability and Hypofibrinolysis and Risk of Deep Vein Thrombosis and Splanchnic Vein Thrombosis Similarities and Differences. Arteriosclerosis, thrombosis, and vascular biology. 2011;31(3):485-93.
28. Chan MY, Andreotti F, Becker RC. Hypercoagulable states in cardiovascular disease. *Circulation*. 2008;118(22):2286-97.
29. Hibbard BM, Hibbard ED. Neutrophil hypersegmentation and defective folate metabolism in pregnancy. *BJOG: An International Journal of Obstetrics & Gynaecology*. 1971;78(9):776-80.
30. Leclair SJ. Morphologic and Distributive Leukocyte Disorders. *Hematology: Clinical Principles and Applications*. 2007:373.