

## Brief Communication

## Heparin- Induced Thrombocytopenia (HIT): a Case Report of CABG Patient

Alireza Jahangirifard<sup>1</sup>, Majid Golestani-Eraghi<sup>2\*</sup>, Mohammad Ali Saghafi<sup>3</sup>

### Abstract

Heparin- induced thrombocytopenia (HIT) is an antibody mediated adverse effect of heparin therapy, which is classified into two subtypes, HIT<sub>I</sub> which is non-immune, spontaneously reversible thrombocytopenia and; HIT<sub>II</sub> which is an autoimmune-mediated adverse effect of heparin therapy. In this case report, we described a 65-year old male patient with HIT<sub>II</sub> after coronary artery bypass grafting.

**Keywords:** Heparin- induced thrombocytopenia, Heparin- induced thrombosis, coronary artery bypass grafting

**Please cite this article as:** Jahangirifard A, Golestani Eraghi M, Saghafi A. Heparin-Induced Thrombocytopenia (HIT): a Case Report of CABG Patient. *J Cell Mol Anesth.* 2016;1(4):175-9.

1. Tracheal Diseases Research Center, Shahid Beheshti University of Medical Science, Tehran, Iran

2. Chronic Respiratory Diseases Research Center, Shahid Beheshti University of Medical Science, Tehran, Iran

3. Anesthesiology Research Center, Cardiac Anesthesiology Department, Shahid Beheshti University of Medical Sciences, Tehran, Iran

**Corresponding Author:**

Majid Golestani Eraghi, MD; Anesthesiologist, Fellowship in intensive care, Chronic Respiratory Diseases Research Center, Shahid Beheshti University of Medical Science, Tehran, Iran Tel: 00982121172525; Fax: 00982127122537; Address: Masih Daneshvari Hospital, Darabad Ave, Tehran, Iran.

Email: [Dr.golestani@sbmu.ac.ir](mailto:Dr.golestani@sbmu.ac.ir)

Received: August 8, 2016

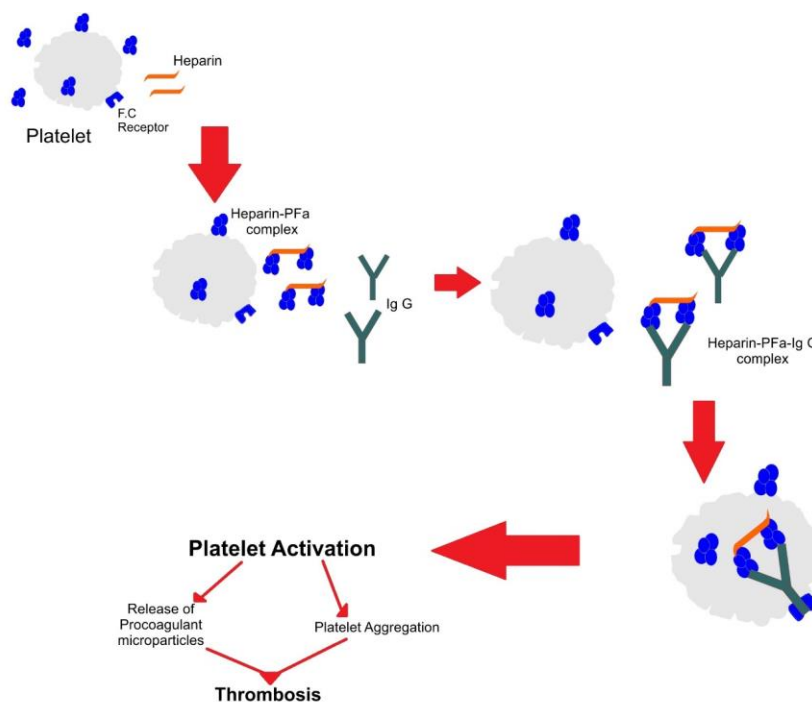
Accepted: September 10, 2016

### Introduction

Heparin- induced thrombocytopenia (HIT) is an antibody mediated adverse effect of heparin therapy, which can be a fatal complication of cardiac surgeries (1). As shown in Figure 1, this situation is due to antibody formation against heparin-platelet factor 4 complex (PF4) which activates platelets and vascular endothelial cells followed by platelet adhesion to vascular wall and white clot formation (2). HIT is a procoagulant state with significantly high potential thrombosis formation in deep vein and sometimes arteries (3). The incidence of HIT varies depending on the study population. The overall risk of HIT is about 0.2% in all heparin- exposed patients (4).

### Brief Report

A 65 year-old male with a history of hypertension and myocardial infarction (MI) was admitted to the emergency center with chest pain. He was referred to the cardiologist for angiography and then became a candidate for emergent coronary artery bypass grafting (CABG). While on cardiopulmonary bypass, he received 35,000 units of heparin. Surgery was done with routine technique and was finished without any complication. He extubated 12hrs after surgery in the intensive care unit (ICU). In postoperative day, he received heparin again because of the atrial fibrillation rhythm (AF). On the thirtieth day, he underwent surgical pericardial drainage due to reported pericardial effusion in echocardiographic evaluation.



**Fig. 1.** Mechanism of HIT.

Five days later, right lower extremity cyanosis was noted which spread to four extremities 24 hours after first cyanotic changes (Figure 2). Platelet count on admission day was 176,000/ $\mu$ l but dropped to 108,000/ $\mu$ l in the fifth postoperative day.

Hematology consultation was requested. Heparin-induced thrombocytopenia (HIT<sub>II</sub>) was the first differential diagnosis, therefore heparin and warfarin were held and Paradoxa (110 mg Tablet, twice daily) was administered. PF4 antibody was measured. Doppler evaluation of four extremities showed no significant sign of arterial ischemia. PF4 Antibody antibody reported 0.675 OD. Two days after discontinuation of heparin, the platelet has dropped to 75000/ $\mu$ l but in the next days, its count increases to within normal range.

Patient in ICU developed respiratory distress. Chest X ray (CXR) and spiral CT- scan showed patchy infiltration in the upper lobe of both lungs and left plural effusion controlled by chest tube insertion.

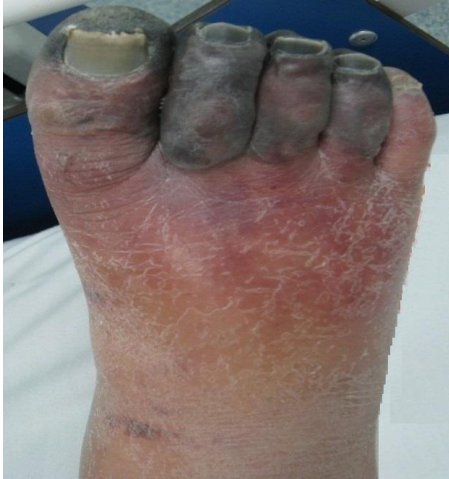Cyanosis in fingers in the four extremities developed to complete gangrene (Figure 3), which, according to the vascular surgeon’s consultation, elective amputation was suggested.

Blood urea nitrogen (BUN) and creatinine (Cr) increased in the second week of hospitalization, and

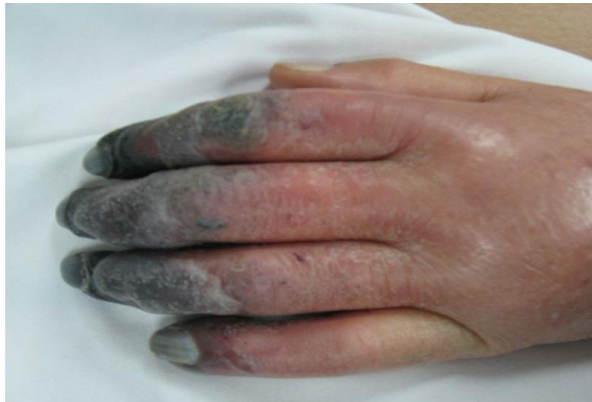the patient developed oliguria. He received necessary treatment based on the nephrologist’s order. Urinary output improved to normal range, but BUN and Cr did not return to normal range.

On the nineteenth day of hospitalization, loss of consciousness occurred but gradually increased. The patient was intubated and received mechanical ventilation; the next day, gastrointestinal (GI) bleeding occurred with an increase in liver function test to more than 2 times the normal range. The patient was to consult with a Gastroenterology sub specialist, but loss of consciousness got deeper to deep coma (with non-responsive dilated pupils). Twenty four days after hospitalization, the patient died due to bradycardia and cardiac arrest.

Due to the increasing severity of edema and dyspnea, the medical care team decided for prophylactic intubation of the patient. Since the upper airway anatomy demonstrated huge distortion accompanied by increasing edema of the tongue and lips, we decided to intubate the patient in a sitting position using fiberoptic bronchoscope. After primary explanation, assurance and taking informed consent, the upper airway was locally anesthetized using 2% lidocaine spray, but oral intubation using fiberoptic bronchoscopy failed. Due to severe edema of the right



**Fig. 2.** Right lower extremity cyanosis was noted which spread to four extremities 24 hours after first cyanotic changes.



**Fig. 3.** Cyanosis in fingers in four extremities developed to complete gangrene.

nasal passage, nasal cavity and nasopharynx (Figure 3) the left nasal passage was chosen for nasal intubation. The left nasal cavity was first anesthetized; but there was difficulty for administration of lidocaine spray since the patient was under treatment with a maintenance dose of anticoagulant. A combination of lidocaine plus phenylephrine on cotton swab was administered in the anterior nares area, the anterior ethmoidal nerves; and sphenopalatine ganglion. A number 7 cuffed tracheal tube was passed through the nasal cavity to the trachea over the fiberoptic bronchoscope; its passage was preceded by direct visualization and approval of the vocal cords and then, the trachea; due to patient dyspnea, bronchoscopy was done in sitting position (Figure 4). The vocal cords had changed from their normal status to severely enlarged and edematous

objects partially occluding the upper airway at the entrance of the trachea in concordance with the CT scan assessment (Figures 1 to 3). The tube was checked regarding ventilation; it was now that the patient was relieved of dyspnea. Pulse oxymeter demonstrated a saturation of 96% and the hemodynamic status was normal.

After about 30 minutes, the saturation gradually started falling down, which reached to about 80%, while the patient was receiving supplementary oxygen through the tracheal tube and then, was mechanically ventilated; meanwhile, the left side of the face started swelling, creating subcutaneous emphysema accompanied with decreased pulmonary sounds. An emergency chest X ray was performed which showed bilateral pneumothorax (Figure 5). Left side chest tube was inserted in a few minutes by the standby surgeons that revealed the respiratory problems immediately. The pulse oxymeter showed a saturation of 98% under mechanical ventilation, but due to suspicious air in the right side, the right side chest tube was also inserted. For both the chest tubes, a sudden “hiss” sound of air leaking out of the chest was heard immediately.

A series of lab exams were done to check IgE and serum complements which showed that serum levels of IgE were highly increased during the first hours after the event; while serum levels of complement were normal during the aftermath and did not increase during the next days.

During the next 48 hours, the patient recovered gradually; the right sided edema was decreased and the left sided subcutaneous emphysema faded. The patient tolerated the respiratory weaning process having a spontaneous breathing being aided with 5 cmH<sub>2</sub>O positive end expiratory pressure (PEEP) leading to total disconnection from mechanical ventilation. At the end of the 48-hour period, after total separation from mechanical ventilation, the pilot cuff of the tracheal tube was emptied; leaving the patient on spontaneous respiration for another 24 hours while having the tube. Per patient need, the local sterile lidocaine solution was administered into the tracheal tube to make it tolerable for the patient while his pain scores never raised more than 3 of 10 on a visual analog pain scale.

The patient was examined after 24 hours, which showed positive and free air leakage test around the tracheal tube. The respiratory status was normal and the patient was extubated; in a situation that he did not have any edema, swelling, or subcutaneous emphysema.

He tolerated the next day without any problem while after 48 hours dyspnea started which was associated with a ground glass appearance of the chest. He was again intubated after 24 hours, but this time, intubation was accompanied with normal anatomy and was done orally. 48 hours of supportive mechanical ventilation helped the lungs improve and the patient was extubated. He was under intensive support for another 24 hours and was transferred to the ordinary ward (which lasted for one week of supportive care). Finally, after 2 more days, he was discharged with no residual defects leaving hospital for his home.

## Discussion

Heparin-induced thrombocytopenia is classified into two subtype: HIT<sub>I</sub> which is non-immune, spontaneously reversible thrombocytopenia and HIT<sub>II</sub> is an autoimmune-mediated adverse effect of heparin therapy (1). Discontinuation of heparin exposure (including catheter flushes) is essential in control and treatment of both subtypes (5).

Frequency of HIT varies based on the population studied. Frequency of HIT in Smythe's study was reported to be about 0.76% with therapeutic doses of intravenous unfractionated heparin (4). Other studies have estimated the incidence of HIT to be about 1-5% (6). The most common pattern of HIT is early onset, which is 4-10 days after initial exposure to heparin with platelet count dropping to more than 50 percent (2).

Deep vein thrombosis (DVT) and pulmonary embolism (PE) are common and the major manifestations of HIT. Limb gangrene, cerebral sinus thrombosis, upper limb DVT, stroke, MI, acute limb ischemia, kidney infarction, skin necrosis on fat-rich areas are other clinical manifestation of HIT<sub>II</sub> (2).

ELISA test to detect antibodies against PF4/heparin complex, sensitive test for HIT diagnosis are most common, whereas a negative test, can strongly can roll rule out the diagnosis. However, the gold

standard test is the 14 C-serotonin release assay, where a positive test is strongly associated with thrombocytopenia in 5 or more days after heparin exposure (6).

Seigerman, in his observational study reported that HIT is associated with a 50% increase in early mortality in patients undergoing cardiac surgeries and most of them experience major postoperative mortality and functional deficits (7).

Platelet count in our case dropped 5 days after heparin exposure and developed two days after discontinuation of heparin (more than 50% drop in platelet count until Day 7) and other HIT manifestation occurred in sequence.

## Conclusion

Despite the low frequency of HIT<sub>II</sub>, its thrombotic complications could cause severe morbidity and high mortality rate. Due to the increasing number of on-pump cardiac surgeries with heparin administration, the risk of HIT is increasing in surgical centers therefore a high index of suspicion for HIT is essential for correct clinical or laboratory diagnosis and in time management.

## Acknowledgment

The authors would like to acknowledge the kind efforts of personnel of Tracheal Diseases Research Center, Chronic Respiratory Diseases Research Center, and Anesthesiology Research Center, Shahid Beheshti University of Medical Sciences, Tehran, Iran for their kind help and cooperation.

## Conflicts of Interest

The authors declare that there are no conflicts of interest.

## References

1. Kramer R, Oberg-Higgins P, Russo L, Braxton JH. Heparin-induced thrombocytopenia with thrombosis syndrome managed with plasmapheresis. *Interact Cardiovasc Thorac Surg.* 2009;8(4):439-41.
2. Cohen RA, Castellani M, Garcia CA. Heparin induced thrombocytopenia: case presentation and review. *J Clin Med Res.*

- 2011;4(1):68-72.
- 3.Solomon CG. Heparin-induced thrombocytopenia. *NEJM*. 2015;373:252-261.
- 4.Smythe MA, Koerber JM, Mattson JC. The incidence of recognized heparin-induced thrombocytopenia in a large, tertiary care teaching hospital. *Chest*. 2007;131(6):1644-9.
- 5.Linkins LA. Heparin induced thrombocytopenia. *BMJ*. 2015;350:g7566.
- 6.Napolitano LM, Warkentin TE, Almahameed A, Nasraway SA. Heparin-induced thrombocytopenia in the critical care setting: diagnosis and management. *Crit Care Med*. 2006;34(12):2898-911.
7. Seigerman M, Cavallaro P, Itagaki S, Chung I, Chikwe J. Incidence and outcomes of heparin-induced thrombocytopenia in patients undergoing cardiac surgery in North America: an analysis of the nationwide inpatient sample. *Journal of Cardiothoracic and Vascular Anesthesia*.