

Case report

Anesthetic Management of Rapid Ventricular Response Atrial Fibrillation in an Elderly Woman Using Remifentanyl; A Case Report

Fatemeh Roodneshin¹ , Fereshteh Kimia¹ , Mahtab Poor Zamany Nejat Kermany^{1*} 

Abstract

Atrial fibrillation (AF) is the most common cardiac arrhythmia in all clinical settings. In the setting of atrial fibrillation with the rapid ventricular response (AFib with RVR), early rate control (with or without restoration of the sinus rhythm) is the center of management. Several drugs are used to manage rapid ventricular response AF, but the optimal one is unknown yet. This case report presents an elderly woman undergoing urgent ophthalmic surgery whose rapid Remifentanyl controlled ventricular response AF.

Keywords: Atrial Fibrillation; Ophthalmic Surgery; Remifentanyl; Cardiac Arrhythmia

1. Department of Anesthesiology, Labbafinejad Hospital, Shahid Beheshti University of Medical Sciences, Tehran, Iran

Corresponding Author:

Mahtab Poor Zamany Nejat Kermany, Associate Professor of Anesthesiology, Department, Anesthesiology, Labbafinejad Hospital, Shahid Beheshti University of Medical Sciences, Tehran, Iran.

Email: drpoorzamany@yahoo.com

Please cite this article as: Roodneshin F, Kimia F, Poor Zamany Nejat Kermany M. Anesthetic Management of Rapid Ventricular Response Atrial Fibrillation in an Elderly Woman Using Remifentanyl; A Case Report. *J Cell Mol Anesth.* 2022;7(1):70-3. DOI: <https://doi.org/10.22037/jcma.v6i4.33514>

Introduction

Atrial fibrillation (AF) is the most common cardiac Arrhythmia in all clinical settings. Advanced age is the most significant risk factor for the development of AF with Rapid Ventilator Response (1, 2). For the management of rapid ventricular response AF, the rate must be decreased with or without restoration of sinus rhythm (1).

Remifentanyl is an ultrashort-acting opioid, metabolized rapidly by blood and tissue esterase (3). Remifentanyl seems to produce cardioprotective and antiarrhythmic effects through opioid receptors Since naloxone could suppress it (4). Another possible mechanism for antiarrhythmic effects of Remifentanyl could be related to changes in the ionic channel's

activity of the myocardium. In addition, the increased vagal tone by Remifentanyl might be involved in reverting supraventricular Arrhythmia to normal sinus rhythm (4). In this report, we described the administration of Remifentanyl for the management of rapid ventricular response AF in an elderly patient undergoing emergent ophthalmic surgery.

Case Report

Because of a perforated corneal ulcer, a 93-year-old lady (weight: 45 kg) was referred to Labbafinejad Hospital (Tehran, capital city of Iran). Ophthalmologists recommended tectonic corneal graft surgery. Past medical history included AF and

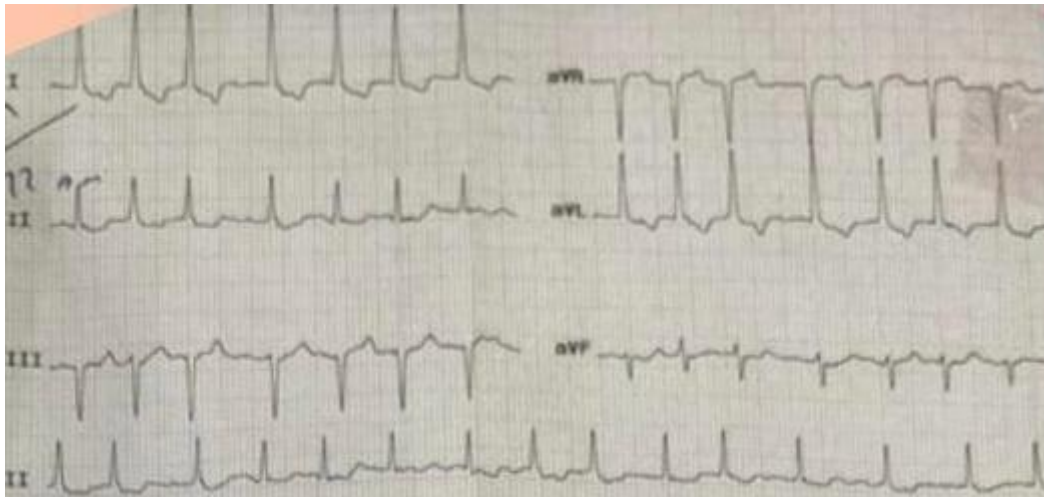


Figure 1. Preoperative ECG.

hypertension. Medication history included metoprolol and Rivaroxaban, which was discontinued 3 days prior due to recurrent epistaxis. In the emergency department, cardiac monitoring showed rapid ventricular response AF. The average heart rate (HR) was 112/min. Other hemodynamic parameters were in the normal range

The cardiologist recommended a delay in surgery, further workups, and attempting to control HR, which the surgeon accepted. Echocardiography showed a left ventricular ejection fraction of 50% and moderate-to-severe aortic stenosis. In the cardiac care unit (CCU), the patient’s HR was adequately

controlled by a single dose of 0.5 mg digoxin. After 48 hours of admission to the CCU, an ophthalmologist deemed surgery emergent. Blood Pressure (BP) was 100/70 mmHg on preoperative examination, and cardiac monitoring showed atrial fibrillation with rapid ventricular response and Oxygen Saturation (SPO2) of 93%. Upon arrival to the operating room (OR), HR had increased again. (Figure 1) but, because of the emergency of eye surgery, the decision was made to go ahead with the surgery.

We induced anesthesia using 100 microgram fentanyl (over 3 minutes), 10 mg etomidate (iv infusion over the 60s), 20 mg atracurium. A laryngeal mask was

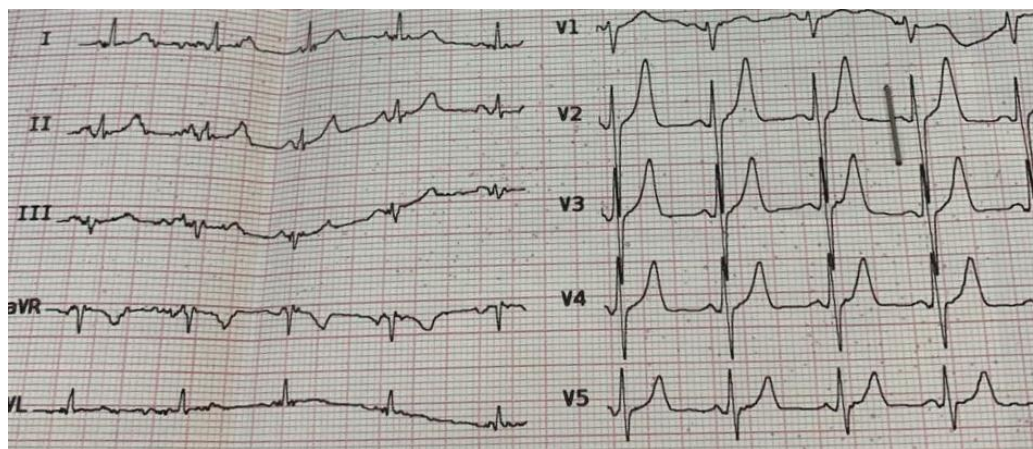


Figure 2. Postoperative ECG.

inserted, and 0.5-1% isoflurane was chosen to maintain anesthesia. Cardiac monitoring showed AF with RVR and HR in the range of 120s bpm. Therefore, we administered a bolus of Remifentanil (25 micrograms over 60 seconds) followed by a 0.1 microgram/kg/min maintenance dose. After about 2 minutes, HR was successfully decreased to 83 bpm, and BP improved to 130/80 mmHg. So, we could proceed with the rest of the anesthesia with the same range of isoflurane concentration with minimal changes in systemic blood pressure. During surgery, systolic BP was between 100 to 140 mmHg. The remainder of the surgery was uneventful, and in the end, we reversed the neuromuscular blocking agent with 2.5 mg neostigmine and 1mg atropine. When patients' spontaneous breaths became acceptable, LMA was removed, and the patient was sent to PACU. After one hour, she was sent back to CCU with adequate HR control (figure 2) and hemodynamics: BP of 120/70 mmHg, HR of 82 bpm, SPO2 97%. She was closely monitored for the next 48 hours, including continuous cardiac monitoring. The clinical course was uneventful, and she was discharged from the hospital in good condition.

Discussion

This article described the remifentanil effect on HR control in an elderly patient with rapid ventricular response AF undergoing emergent surgery. Remifentanil seems to exert a cardioprotective and antiarrhythmic effect. There is currently no definite consensus about the exact mechanism that enables opioids to increase the resistance to arrhythmogenic factors (4). In some studies, this effect is assumed to be done through opioid receptors since naloxone could suppress it (4). Myocardial opioid receptors activation inhibits adenylyl cyclase activity which will cause a decrease in cAMP production. This would lead to a negative effect on cardiac inotropic and chronotropic effects (5).

On the other hand, the activation makes a stimulatory effect on the production of nitric oxide, which could stabilize the electrical possession and activities of the heart using acting on the coronary arteries endothelium and augmentation of blood supply to the myocardium (4). Another possible mechanism

for antiarrhythmic effects of Remifentanil could be related to changes in the ionic channel's activity. It's been shown that Remifentanil suppressed the calcium and potassium ion channels. So due to an increase in the inwardly rectifying potassium current duration of action potential will rise, and hyperpolarization of the membrane resting potential happens, implying a direct antiarrhythmic activity. In addition, increased vagal tone by Remifentanil might also be involved in reverting supraventricular Arrhythmia to normal sinus rhythm (5). Choi reported three cases of supraventricular Arrhythmia converted to normal sinus rate during general anesthesia using propofol and Remifentanil. They concluded that propofol and/or Remifentanil might play a role in reverting atrial fibrillation to normal sinus rhythm (5).

Luna Ortiz et al. demonstrated the antiarrhythmic effect of Remifentanil in digitalis intoxication induced Arrhythmia in anesthetized dogs. They contributed the antiarrhythmic effect of Remifentanil to the opioidergic system, which causes the opening of the sarcolemmal and mitochondrial ATP-sensitive potassium channel, which plays an essential role in suppressing re-entry phenomena (4). Another study reported successful management of supraventricular tachyarrhythmia using Remifentanil in a patient during cesarean delivery (6). Hatipoğlu designed a study to compare the cardio-protective effects of Remifentanil and dexmedetomidine in cardiac surgery. In this study, CKMB and lactate levels were lower in the dexmedetomidine group. However, no differences were seen between the groups for the length of ICU stay and extubation time (7). Wong et al. showed that some cardiac biomarkers (cTnI, creatine kinase, etc.) decreased in cardiac patients using Remifentanil (8).

Conclusion

This article described anesthetic management in an old patient with rapid response AF during an emergent ophthalmic surgery. Remifentanil did the HR control. Based on this report, Remifentanil may be considered for rate control in rapid AF patients; however, further studies are needed to determine definitive results.

Acknowledgment

None.

Conflicts of Interest

The authors declare that there are no conflicts of interest.

References

1. Bouida W, Beltaief K, Msolli MA, Azaiez N, Ben Soltane H, Sekma A, et al. Low-dose Magnesium Sulfate Versus High Dose in the Early Management of Rapid Atrial Fibrillation: Randomized Controlled Double-blind Study (LOMAGHI Study). *Academic emergency medicine : official journal of the Society for Academic Emergency Medicine*. 2019;26(2):183-91.
2. Kornej J, Börschel CS, Benjamin EJ, Schnabel RB. Epidemiology of Atrial Fibrillation in the 21st Century: Novel Methods and New Insights. *Circ Res*. 2020;127(1):4-20.
3. Bayındır S, Gökmen N, Erbayraktar S, Küçükçüçlü S, Yılmaz O, Şahin Ö, et al. Cardioprotective Effects of Remifentanyl in a Sympathetic Hyperactivity Model in Rabbits. *Turk J Anaesthesiol Reanim*. 2015;43(4):225-31.
4. Luna-Ortiz P, Zarco-Olvera G, Ramírez-Ortega M, Tenorio-López FA, Gutiérrez A, Martínez-Rosas M, et al. Antiarrhythmic and cardioprotective effects of remifentanyl in anesthetized dogs. *Arch Cardiol Mex*. 2009;79(3):182-8.
5. Choi EK, Jee DL. Conversion of supraventricular arrhythmia to normal rhythm by propofol and remifentanyl: three cases report. *Korean J Anesthesiol*. 2014;66(3):244-7.
6. Chhabria R, Kaushik PS. Wolff-Parkinson White syndrome in a parturient with rheumatic heart disease for caesarean section - Anaesthesia management. *Indian J Anaesth*. 2018;62(8):641-3.
7. Türktan M, Güneş Y, Yalınz H, Matyar S, Hatipoğlu Z, Güleç E, et al. Comparison of the cardioprotective effects of dexmedetomidine and remifentanyl in cardiac surgery. *Turk J Med Sci*. 2017;47(5):1403-9.
8. Wong GT, Huang Z, Ji S, Irwin MG. Remifentanyl reduces the release of biochemical markers of myocardial damage after coronary artery bypass surgery: a randomized trial. *J Cardiothorac Vasc Anesth*. 2010;24(5):790-6.