



Electroencephalogram Abnormalities in Very Young Children with Acute Hepatitis A Infection: A Cross-Sectional Study

Iraj Shahramian¹, Mohammad Hassan Mohammadi¹, Alireza Akbari², Alireza Sargazi², Mojtaba Delaramnasab³ and Ali Bazi^{3,*}

¹Pediatric Ward, Amir-Al-Momenin Hospital, Zabol University of Medical Sciences, Zabol, Iran

²Student Research Committee, Zabol University of Medical Sciences, Zabol, Iran

³Faculty of Allied Medical Sciences, Zabol University of Medical Sciences, Zabol, Iran

*Corresponding author: Faculty of Allied Medical Sciences, Zabol University of Medical Sciences, Zabol, Iran. Email: m.baziali@gmail.com

Received 2018 August 30; Revised 2019 June 08; Accepted 2019 July 03.

Abstract

Background: There is a shortage on studies concerned with electroencephalogram (EEG) abnormalities in neurologically asymptomatic children with acute hepatitis A virus (HAV) infection.

Objectives: In the present study, we evaluated EEG patterns in HAV infected children who had no symptoms of overt or minimal hepatic encephalopathy (HE).

Methods: Forty-five children infected with HAV infection along with 45 healthy children were studied. EEG was acquired in resting condition with closed eyes. Statistical analysis was performed in SPSS V. 19 software.

Results: Abnormal EEG patterns were recorded in 16 (35.6%) children with HAV infection while no subject showed EEG abnormality in healthy subjects ($P = 0.02$). Irregular spike along with alpha wave was the most frequent pattern (13 out of 16, 81.2%). One patient (6.3%) showed delta wave, and two patients (12.5%) represented tri-phasic wave. The mean age of the patients with irregular EEG was significantly higher (89.6 ± 35.2 months) than patients with normal EEG (60.7 ± 36.2 months, $P = 0.01$). Although a considerable number of patients with abnormal EEG had abnormally high AST (15/16), and ALT (14/16) levels, the means of neither AST nor ALT were significantly different when comparing patients with normal (535.9 ± 571.8 and 660.1 ± 649.8 IU/L, respectively) and abnormal (666.4 ± 834.7 and 982.1 ± 1230.7 IU/L, respectively) EEG patterns.

Conclusions: Abnormal EEG is a relatively common finding in children with acute HAV infection representing no signs of HE. Higher age and elevated hepatic enzymes levels may predict abnormal EEG patterns in these patients.

Keywords: Hepatitis A, Electroencephalography, Hepatic Encephalopathy

1. Background

Hepatic encephalopathy (HE) is a relatively common sequela complicating the clinical course of patients with end stage liver diseases (1, 2). HE is clinically characterized with a wide range of neurological and psychological dysfunctions encompassing changes in attitude, impaired speech abilities, sleep disorders, and locomotor dysfunction (2, 3). Overt HE generally represents a distinct condition, which is easily identifiable based on clinical presentations (4, 5). However, silent or minimal HE may raise a diagnostic challenge for physicians.

HE has been described in association with various hepatitis viruses including hepatitis C (HCV), hepatitis B (HBV), hepatitis E (HEV), and hepatitis A (HAV) (6-11). Thus, overt HE has been noted in 7.4% of patients with HAV infection (11). Beside overt HE, the incidence of minimal HE in pa-

tients with acute viral hepatitis has been associated with a variety of complications (12). The subclinical HE remains undiagnosed in a considerable ratio of patients depriving them from appropriate treatments. On the other hand, undiagnosed HE may progress to overt HE and endanger patients' lives (13).

Electroencephalography (EEG) is a sensitive and rapid method to identify cerebral disorders by recording brain electrical signals. This method provides a sensitive and reliable procedure for screening neurophysiological disorders (14). Abnormal EEG has been noted as an early diagnostic sign for brain dysfunction in the absence of overt or minimal HE (15, 16). There is a shortage on studies concerned with EEG abnormalities in neurologically asymptomatic children with HAV infection.

2. Objectives

In the present study, we evaluated EEG patterns in 45 HAV infected and 45 healthy children admitted to our hospital during a 12-month period.

3. Methods

3.1. Patients

Forty-five HAV infected children admitted to our hospital, along with 45 age and sex matched healthy children, were included in the study. Healthy subjects were selected from children showing no signs of any systemic disorder and representing normal results for basic laboratory tests (i.e. complete blood count, liver enzymes, fasting blood sugar, and thyroid hormones). This study was performed in the pediatric ward of Amir-Al-Momenin Hospital of Zabol city, Sistan and Baluchestan province of Iran. The patients and healthy controls were recruited during a 12-month period from June 2016 to June 2017. After a comprehensive interview for investigating any history of mental disorders in the family, which was the main exclusion criterion, an informed consent was acquired from the children's parents. Ten milliliter blood samples were taken for biochemical and hepatic enzymes studies.

3.2. Exclusion Criteria

Those children with any sign of coagulopathies, history of brain disorders in the family, systemic disorders, history of receiving neurotoxic drugs, and presenting with neurological or psychological symptoms were excluded.

3.3. EEG Assessment

EEG was performed in rest condition while the patients were awake and closed-eyes using Neurofax EEG-4518 (Nihon Kohden, Tokyo, Japan), as previously described (17). The 10 - 20 international system was applied. Five electrodes were attached to the skin surface at T3, T4, O1, O2, and Cz locations. The assessment was carried out in 0.53 - 35 Hz frequency for 100 seconds.

3.4. Statistical Analysis

Data was analyzed by SPSS V. 19 software. Data distribution was checked by Kolmogorov-Smirnov test. Chi-square test and Independent Sample Student *t*-test were used for univariate analyses. Significance level was considered at $P < 0.05$.

4. Results

Out of 45 patients, males and females comprised of 18 (40%) and 27 (60%), respectively. In healthy controls, 16 (35.5%) and 29 (64.5%) subjects were males and females, respectively. The mean ages in HAV infected and healthy children were obtained 71 ± 38.1 and 92.2 ± 32 months, respectively ($P = 0.1$). Hemoglobin, prothrombin time (PT), partial thromboplastin time (PTT), hepatic enzyme levels, total and direct bilirubin levels, and erythrocyte sedimentation rate (ESR) were significantly different between infected and healthy children (Table 1).

Abnormal encephalogram pattern was recorded in 16 (35.6%) HAV infected patients (Figure 1). EEG abnormality was not detected in any healthy child ($P = 0.02$). Irregular spikes along with alpha waves were the most frequent patterns (13 out of 16, 81.2%). One patient (6.3%) showed delta wave, and two patients (12.5%) represented with triphasic waves.

Most of our patients had abnormally high (i.e. > 40 IU/L (18)) hepatic enzymes levels (41/45, 91.1% for aspartate amino transferase (AST), and 37/45, 82.2% for alanine amino transferase (ALT)). Also, 10 patients (22.2%) had abnormally high alkaline phosphatase (ALP) levels. Serum albumin, total protein, total bilirubin, and direct bilirubin measurements showed abnormally high levels in 3 (6.7%), 9 (20%), and 30 (66.7%) patients, respectively.

There was no significant difference between males and females regarding irregular EEG patterns. However, the mean age of patients with irregular EEG was significantly higher (89.6 ± 35.2 months) than the patients with normal EEG (60.7 ± 36.2 months, $P = 0.01$). Although a considerable number of patients with abnormal EEG pattern had abnormally high AST (15/16) and ALT (14/16), the means of neither AST nor ALT were significantly different comparing patients with normal (535.9 ± 571.8 IU/L and 660.1 ± 649.8 IU/L, respectively) or abnormal (666.4 ± 834.7 IU/L and 982.1 ± 1230.7 IU/L, respectively) EEG pattern (Table 2).

5. Discussion

HE is a significant complication in patients with hepatic disorders. This phenomenon may complicate the course of acute hepatitis in a considerable ratio of patients (11). In our study, we assessed EEG patterns in children with HAV infection without any sign of HE. Actually, HE is a relatively uncommon feature in HAV infection. In a previous study, Sharma et al., reported an incidence of 25% for minimal HE in young-adult patients with acute viral hepatitis (19). From the 20 patients enrolled in the recent study, two

Table 1. Baseline and Demographic Characteristics of 45 Children with Hepatitis A Infection and Their Controls

Parameters	HAV- Infected Children (N = 45)		Healthy Children (N = 45)		P Value
	Minimum - Maximum	Mean (SD)	Minimum - Maximum	Mean (SD)	
Age (mon)	2 - 156	71 (38.1)	5 - 144	92.2 (32)	0.1
Weight (kg)	6 - 42	19.2 (7.6)	10 - 40	20.7 (7.6)	0.2
White blood cell count ($\times 10^3/\mu\text{L}$)	4 - 18.5	8.8 (2.9)	5.8 - 12.9	8.8 (2.6)	0.6
Hemoglobin (g/dL)	7 - 14.6	11.3 (1.3)	9.9 - 14.1	12.3 (1.04)	0.003
Platelet ($\times 10^3/\mu\text{L}$)	173 - 721	344.2 (145)	143 - 540	296.7 (114.1)	0.5
Prothrombin time (s)	13 - 17	13.5 (1.1)	10 - 14	12.6 (1.07)	0.04
Partial thromboplastin time (s)	29 - 48	37.4 (5.6)	30 - 45	33.7 (4.9)	0.01
Aspartate amino transferase (IU/L)	20 - 3350	582.3 (670.5)	20 - 45	32.4 (9.6)	0.001
Alanine amino transferase (IU/L)	10 - 4350	774.6 (899.6)	12 - 38	23.6 (7.5)	< 0.001
Alkaline phosphatase (IU/L)	240 - 6360	1027.9 (929.8)	211 - 575	389 (123.8)	< 0.001
Albumin (g/dL)	1.8 - 6.8	4.1 (1)	3.2 - 5	4.4 (0.5)	0.8
Total protein (g/dL)	5 - 9.6	7.4 (0.9)	5.8 - 8.2	7 (0.8)	0.4
Total bilirubin (mg/dL)	0.5 - 10.7	3.5 (2.9)	0.5 - 2	0.9 (0.4)	< 0.001
Direct bilirubin (mg/dL)	0.2 - 4.1	1.2 (1)	0.1 - 1	0.29 (0.25)	< 0.001
Erythrocyte sedimentation rate (mm/h)	4 - 61	24.6 (14)	1 - 20	8.4 (6.7)	< 0.001

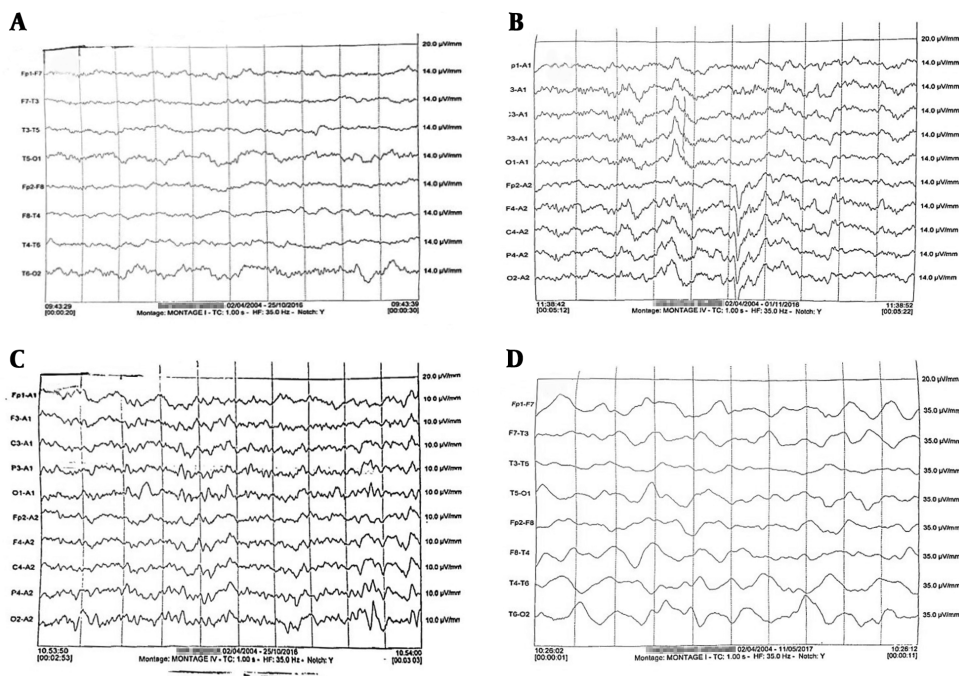


Figure 1. Electroencephalography results related to children with hepatitis A infection. A, normal regular alpha waves observed in 29/45 patients; B, spike and alpha waves pattern which was seen in 13 out of 16 patients with abnormal EEG; C, tri-phasic waves observed in two cases; and D, delta wave which was detected in one 4-year old female child.

of them had an acute HAV infection, two had HEV, while 16 had been diagnosed with HBV infection (19). In a study in Japan on 164 patients with acute hepatitis, 27 individuals were diagnosed with HAV infection, from whom, two (7.4%)

cases developed HE during the course of the disease (11).

Abnormal EEG was recorded in 16/45 (35.6%) of our patients. These abnormalities included irregular spikes along with alpha (13 out of 16, 81.2%), triphasic (2 out of 16,

Table 2. A Comparison of Different Clinical Parameters Between Hepatitis A Children with Normal and Abnormal EEG Profiles

Parameters	Electroencephalography		Normal Range	P Value
	Normal (N = 29)	Abnormal (N = 16)		
Age (years)			-	0.04
< 7	23	8		
> 7	6	8		
Sex			-	0.3 ^a
Male	13	5		
Female	16	11		
Aspartate amino transferase (IU/L)			5 - 40	0.5 ^a
Normal	3	1		
Abnormal	26	15		
Alanine amino transferase (IU/L)			5 - 40	0.4 ^a
Normal	6	2		
Abnormal	23	14		
Alkaline phosphatase (IU/L)			180 - 1200	0.4 ^a
Normal	22	13		
Abnormal	7	3		
Albumin (g/dL)			3.5 - 5.5	0.7 ^a
Normal	27	15		
Abnormal	2	1		
Total protein (g/dL)			6 - 8	0.6 ^a
Normal	23	13		
Abnormal	6	3		
Total bilirubin (mg/dL)			0.2 - 1.2	0.2 ^a
Normal	11	4		
Abnormal	18	12		
Direct bilirubin (mg/dL)			0 - 0.4	0.2 ^a
Normal	11	4		
Abnormal	18	12		

^a Fisher exact test.

12.5%), and delta (1 out of 16, 6.3%) waves. To our knowledge, this is the first report on EEG alternations in HAV infected children without overt HE. In these conditions, abnormal EEG patterns may precede minimal and subsequently overt HE. EEG abnormalities have been associated with neuropsychiatric status in patients with HE (18, 19). EEG pattern with high continuous low-frequency waves has been associated with temporary lesions at posterior splenium in an adult with HAV infection (20). Generally, substitution of normal alpha waves (8 - 12 Hz) with the slow 5 - 7 Hz theta waves and subsequently with 1 - 3 Hz delta waves denotes a progressive neurological impairment. On the other hand, triphasic waves can be seen at the late theta wave activity (16).

We found no significant association between EEG patterns and demographic or clinical parameters (i.e. AST, ALT, serum protein and albumin levels). However, patients with irregular EEG patterns were significantly older (89.6 ± 35.2

months) than the patients with normal EEG (60.7 ± 36.2 months, $P = 0.01$). In previous reports, major risk factors for HE have been described as higher age, higher total bilirubin, prolonged PT, and non-A-E viral etiologies of hepatitis (11). Likewise, age and disease severity have been associated with EEG abnormalities in HCV infected patients (21, 22). In line with our observation, no associations were detected between HE development and AST, ALT, and serum albumin levels, as well as WBC and platelet counts in the study of Takikawa et al. (11). Neurological function in viral hepatitis can be influenced by the clinical phase of the viral disease as lower neuro-psychological and cognitive functions have been reported in patients in non-icteric (19) and fibrotic (23) phases.

The risk of HE can be modified by some extrahepatic factors as well. Decreased cerebral neurotransmitter function may contribute to the development of neurological symptoms and HE in patients with viral hepatitis (24). Risk

of HE may be further manipulated by nutritional factors as daily protein absorption has been negatively associated with HE progression in patients with alcoholic hepatitis (25). Cerebral dysfunction in hepatitis can be attributed to the high circulating levels of neurotoxic substances resulted from hepatocytes degradation (2, 4). From these toxicants, a special role has been dedicated to the high levels of circulating ammonium (19). Furthermore, HE development is suggested to be related to impaired connectivity between various brain regions (26). Roles have been proposed for inflammatory cytokines; IL-1, TNF- α , and IL-6 (6, 27), concomitant *Helicobacter pylori* infection (28), hyponatremia (7), and high serum hyaluronic acid levels (29) as factors triggering the development and progression of HE.

As many patients are asymptomatic, the diagnosis of subclinical HE, as a potentially debilitating condition, may be masked in children with HAV infection. In these cases, detecting some degrees of cerebral irregular function can help physicians to detect those patients at risk of overt HE. Abnormal EEG patterns even in the absence of overt HE are of crucial importance as they may herald clinical encephalopathy.

Acknowledgments

We would like to thank the patients and their families.

Footnotes

Authors' Contribution: Concept and design: Iraj Shahramian; EEG performance and interpretation: Mohammad Hassan Mohamadi; data collection: Alireza Akbari and Alireza Sargazi; data analysis: Mojtaba Delaramnasab; drafting the manuscript: Ali Bazi.

Conflict of Interests: The authors declare that they have no conflict of interest.

Ethical Approval: Our study was approved by the Ethical Committee of Research of Zabol University of Medical Sciences (Code: Zbmu.1.Rec.1396.145).

Funding/Support: Deputy of Research, Zabol University of Medical Sciences.

Patient Consent: Informed consent was obtained from the children's parents.

References

- Guan R, Lui HF. Treatment of hepatitis B in decompensated liver cirrhosis. *Int J Hepatol*. 2011;2011:918017. doi: [10.4061/2011/918017](https://doi.org/10.4061/2011/918017). [PubMed: [21994876](https://pubmed.ncbi.nlm.nih.gov/21994876/)]. [PubMed Central: [PMC3170850](https://pubmed.ncbi.nlm.nih.gov/PMC3170850/)].
- Moriwaki H, Shiraki M, Iwasa J, Terakura Y. Hepatic encephalopathy as a complication of liver cirrhosis: An Asian perspective. *J Gastroenterol Hepatol*. 2010;25(5):858-63. doi: [10.1111/j.1440-1746.2010.06242.x](https://doi.org/10.1111/j.1440-1746.2010.06242.x). [PubMed: [20546438](https://pubmed.ncbi.nlm.nih.gov/20546438/)].
- El-Khoury M, Naoushi H, Sawaya R, Aoun E, Nassar NT, Sharara AI. Reversible encephalopathy secondary to paratyphoid infection and concomitant acute Hepatitis A. *South Med J*. 2005;98(7):723-5. doi: [10.1097/01.smj.0000168134.80038.25](https://doi.org/10.1097/01.smj.0000168134.80038.25). [PubMed: [16108242](https://pubmed.ncbi.nlm.nih.gov/16108242/)].
- Cordoba J. New assessment of hepatic encephalopathy. *J Hepatol*. 2011;54(5):1030-40. doi: [10.1016/j.jhep.2010.11.015](https://doi.org/10.1016/j.jhep.2010.11.015). [PubMed: [21145874](https://pubmed.ncbi.nlm.nih.gov/21145874/)].
- Barboza KC, Salinas LM, Sahebjam F, Jesudian AB, Weisberg IL, Sigal SH. Impact of depressive symptoms and hepatic encephalopathy on health-related quality of life in cirrhotic hepatitis C patients. *Metab Brain Dis*. 2016;31(4):869-80. doi: [10.1007/s11011-016-9817-y](https://doi.org/10.1007/s11011-016-9817-y). [PubMed: [27032930](https://pubmed.ncbi.nlm.nih.gov/27032930/)].
- Tsai CF, Chu CJ, Huang YH, Wang YP, Liu PY, Lin HC, et al. Detecting minimal hepatic encephalopathy in an endemic country for hepatitis B: The role of psychometrics and serum IL-6. *PLoS One*. 2015;10(6):e0128437. doi: [10.1371/journal.pone.0128437](https://doi.org/10.1371/journal.pone.0128437). [PubMed: [26039496](https://pubmed.ncbi.nlm.nih.gov/26039496/)]. [PubMed Central: [PMC4454579](https://pubmed.ncbi.nlm.nih.gov/PMC4454579/)].
- Lin ZN, Zuo YQ, Hu P. Association of proton pump inhibitor therapy with hepatic encephalopathy in hepatitis B virus-related acute-on-chronic liver failure. *Hepat Mon*. 2014;14(4):e16258. doi: [10.5812/hepatmon.16258](https://doi.org/10.5812/hepatmon.16258). [PubMed: [24748895](https://pubmed.ncbi.nlm.nih.gov/24748895/)]. [PubMed Central: [PMC3989600](https://pubmed.ncbi.nlm.nih.gov/PMC3989600/)].
- Marinescu P, Manolescu LSC. Association of hepatitis B infection in patients with HIV Encephalopathy. *Rom Biotech Lett*. 2012;17(6):7817-24.
- Peron JM, Bureau C, Poirson H, Mansuy JM, Alric L, Selves J, et al. Fulminant liver failure from acute autochthonous hepatitis E in France: Description of seven patients with acute hepatitis E and encephalopathy. *J Viral Hepat*. 2007;14(5):298-303. doi: [10.1111/j.1365-2893.2007.00858.x](https://doi.org/10.1111/j.1365-2893.2007.00858.x). [PubMed: [17439518](https://pubmed.ncbi.nlm.nih.gov/17439518/)].
- Peron JM, Poirson H, Bureau C, Mansuy JM, Selves J, Alric L, et al. 153 Acute hepato-cellular failure with encephalopathy in French patients with autochthonous acute sporadic hepatitis E. *Journal of Hepatology*. 2006;44: S65.
- Takikawa Y, Endo R, Suzuki K, Fujiwara K, Omata M; Fulminant Hepatitis Study Group of Japan. Prediction of hepatic encephalopathy development in patients with severe acute hepatitis. *Dig Dis Sci*. 2006;51(2):359-64. doi: [10.1007/s10620-006-3138-7](https://doi.org/10.1007/s10620-006-3138-7). [PubMed: [16534681](https://pubmed.ncbi.nlm.nih.gov/16534681/)].
- Uriu K, Kaizu K, Matuo N, Soejima M, Hashimoto O, Komine N, et al. Acute renal failure prior to the onset of hepatic encephalopathy in fulminant hepatitis. *Nephrology*. 1996;2(4):257-61. doi: [10.1111/j.1440-1797.1996.tb00097.x](https://doi.org/10.1111/j.1440-1797.1996.tb00097.x).
- Montagnese S, Amodio P, Morgan MY. Methods for diagnosing hepatic encephalopathy in patients with cirrhosis: A multidimensional approach. *Metab Brain Dis*. 2004;19(3-4):281-312. [PubMed: [15554423](https://pubmed.ncbi.nlm.nih.gov/15554423/)].
- Solomou E, Velissaris D, Polychronopoulos P, Kalogeropoulos A, Kiriakopoulou M, Mpadra F, et al. Quantitative evaluation of magnetic resonance imaging (MRI) abnormalities in subclinical hepatic encephalopathy. *Hepatogastroenterology*. 2005;52(61):203-7.
- Morgan MY, Amodio P, Cook NA, Jackson CD, Kircheis G, Lauridsen MM, et al. Qualifying and quantifying minimal hepatic encephalopathy. *Metab Brain Dis*. 2016;31(6):1217-29. doi: [10.1007/s11011-015-9726-5](https://doi.org/10.1007/s11011-015-9726-5). [PubMed: [26412229](https://pubmed.ncbi.nlm.nih.gov/26412229/)].
- Direkze S, Jalan R. Diagnosis and treatment of low-grade hepatic encephalopathy. *Dig Dis*. 2015;33(4):562-9. doi: [10.1159/000375350](https://doi.org/10.1159/000375350). [PubMed: [26159274](https://pubmed.ncbi.nlm.nih.gov/26159274/)].
- Malaguarnera M, Gargante MP, Cristaldi E, Vacante M, Risino C, Cammalleri L, et al. Acetyl-L-carnitine treatment in minimal hepatic encephalopathy. *Dig Dis Sci*. 2008;53(11):3018-25. doi: [10.1007/s10620-008-0238-6](https://doi.org/10.1007/s10620-008-0238-6). [PubMed: [18357530](https://pubmed.ncbi.nlm.nih.gov/18357530/)].
- Roberts I. Nelson's textbook of pediatrics (20th edn.), by R. Kliegman, B. Stanton, J. St. Geme, N. Schor (eds). *Pediatr Radiol*. 2017;47(10):1364-5. doi: [10.1007/s00247-017-3907-9](https://doi.org/10.1007/s00247-017-3907-9).

19. Sharma P, Sharma BC, Tyagi P, Kumar M, Sarin SK. Neuropsychological impairment in severe acute viral hepatitis is due to minimal hepatic encephalopathy. *Liver Int.* 2009;**29**(2):260–4. doi: [10.1111/j.1478-3231.2008.01856.x](https://doi.org/10.1111/j.1478-3231.2008.01856.x). [PubMed: [18710429](https://pubmed.ncbi.nlm.nih.gov/18710429/)].
20. Ko SY, Kim BK, Kim DW, Kim JH, Choe WH, Seo HY, et al. Reversible splenial lesion on the corpus callosum in nonfulminant hepatitis A presenting as encephalopathy. *Clin Mol Hepatol.* 2014;**20**(4):398–401. doi: [10.3350/cmh.2014.20.4.398](https://doi.org/10.3350/cmh.2014.20.4.398). [PubMed: [25548747](https://pubmed.ncbi.nlm.nih.gov/25548747/)]. [PubMed Central: [PMC4278072](https://pubmed.ncbi.nlm.nih.gov/PMC4278072/)].
21. Morita A. Quantitative electroencephalographic analysis in patients with chronic hepatitis C treated with interferon-alpha: A review article. *Neuropsychobiology.* 2015;**71**(1):42–8. doi: [10.1159/000369025](https://doi.org/10.1159/000369025). [PubMed: [25765063](https://pubmed.ncbi.nlm.nih.gov/25765063/)].
22. Kamei S, Oga K, Matsuura M, Tanaka N, Kojima T, Arakawa Y, et al. Correlation between quantitative-EEG alterations and age in patients with interferon-alpha-treated hepatitis C. *J Clin Neurophysiol.* 2005;**22**(1):49–52. [PubMed: [15689713](https://pubmed.ncbi.nlm.nih.gov/15689713/)].
23. Karaivazoglou K, Messinis L, Assimakopoulos K, Sakellaropoulos GC, Theocharis G, Karatza C. Cognitive deficits in Greek patients with chronic hepatitis C in the absence of hepatic encephalopathy. *J Hepatol.* 2006;**44**. S200. doi: [10.1016/S0168-8278\(06\)80537-4](https://doi.org/10.1016/S0168-8278(06)80537-4).
24. Heeren M, Weissenborn K, Arvanitis D, Bokemeyer M, Goldbecker A, Tountopoulou A, et al. Cerebral glucose utilisation in hepatitis C virus infection-associated encephalopathy. *J Cereb Blood Flow Metab.* 2011;**31**(11):2199–208. doi: [10.1038/jcbfm.2011.82](https://doi.org/10.1038/jcbfm.2011.82). [PubMed: [21629258](https://pubmed.ncbi.nlm.nih.gov/21629258/)]. [PubMed Central: [PMC3210344](https://pubmed.ncbi.nlm.nih.gov/PMC3210344/)].
25. Morgan TR, Moritz TE, Mendenhall CL, Haas R. Protein consumption and hepatic encephalopathy in alcoholic hepatitis. VA Cooperative Study Group #275. *J Am Coll Nutr.* 1995;**14**(2):152–8. [PubMed: [7790689](https://pubmed.ncbi.nlm.nih.gov/7790689/)].
26. Lv XF, Liu K, Qiu YW, Cai PQ, Li J, Jiang GH, et al. Anomalous gray matter structural networks in patients with hepatitis B virus-related cirrhosis without overt hepatic encephalopathy. *PLoS One.* 2015;**10**(3). e0119339. doi: [10.1371/journal.pone.0119339](https://doi.org/10.1371/journal.pone.0119339). [PubMed: [25786256](https://pubmed.ncbi.nlm.nih.gov/25786256/)]. [PubMed Central: [PMC4364769](https://pubmed.ncbi.nlm.nih.gov/PMC4364769/)].
27. Hida S, Hirasawa H, Oda S, Matsuda K, Endoh H. Proinflammatory cytokines correlate with the development of encephalopathy in patients with fulminant hepatitis. *Acta Med Biol (Niigata).* 2004;**52**(4):141–8.
28. Gubbins GP, Moritz TE, Marsano LS, Talwalkar R, McClain CJ, Mendenhall CL. *Helicobacter pylori* is a risk factor for hepatic encephalopathy in acute alcoholic hepatitis: The ammonia hypothesis revisited. The Veterans Administration Cooperative Study Group No. 275. *Am J Gastroenterol.* 1993;**88**(11):1906–10. [PubMed: [8237940](https://pubmed.ncbi.nlm.nih.gov/8237940/)].
29. Peters L, Mocroft A, Soriano V, Rockstroh J, Rauch A, Karlsson A, et al. Hyaluronic acid levels predict risk of hepatic encephalopathy and liver-related death in HIV/viral hepatitis coinfecting patients. *PLoS One.* 2013;**8**(5). e64283. doi: [10.1371/journal.pone.0064283](https://doi.org/10.1371/journal.pone.0064283). [PubMed: [23724041](https://pubmed.ncbi.nlm.nih.gov/23724041/)]. [PubMed Central: [PMC3664579](https://pubmed.ncbi.nlm.nih.gov/PMC3664579/)].