



Retracted Article: Diagnostic Accuracy of Acute Appendicitis by Ultrasound in Hospital Emergency

Mohamad Ghasem Hanafi^{1,*} and Afshin Shiri¹

¹Ahvaz Jundishapur University of Medical Sciences, Ahvaz, Iran

*Corresponding author: Department of Radiology, Ahvaz Jundishapur University of Medical Sciences, Ahvaz, Iran. Email: katbeh7610@gmail.com

Received 2018 July 27; Accepted 2018 August 12.

Abstract

Objectives: Acute appendicitis is the most common medical condition requiring an immediate abdominal surgery. Medical ultrasound is a non-intrusive, non-expensive, and available diagnostic method. In this paper, the accuracy of this method was evaluated.

Methods: This retrospective cohort study was performed at Ahvaz Imam Khomeini Hospital with 2,100 emergency department visits per year. The records of outpatients and inpatients of this hospital were studied to extract demographic information about the patients and radiological reports indicating the occurrence or exclusion of acute appendicitis and post-appendectomy report to allow for results comparison.

Results: A total of 163 study subjects met the inclusion criteria, with the age range of 1 to 80 years. The accuracy, sensitivity, and specificity were 98.1, 96, and 100%, respectively. The positive predictive value was 100% while the negative predictive value was 82.35%. Diagnostic accuracy was 100% for the under-15 age group and 94.06% for the above-15 age group.

Conclusions: The results showed that the medical ultrasound reports could be considered more credible in diagnosing acute appendicitis in under-15 male subjects, which paves the way for the more accurate planning of treatment and presenting patients with abdominal pains for surgery. In addition, non-surgical procedures could be administered for both genders and age groups with stronger certainty and confidence in negative medical ultrasound reports.

Keywords: Ultrasound, Appendicitis, Diagnosis, Accuracy

1. Background

Acute appendicitis is the most common medical condition requiring immediate abdominal surgery (1). In most institutions, ultrasound has become the first-line imaging modality for the evaluation of appendix in the pediatric population (2). Although clinical symptoms of acute appendicitis are characterized by pains that begin in the region of the umbilicus and then “localizes” into the right lower quadrant known as the McBurney’s point, there is also a need to see elevation of neutrophilic white blood cells that are well defined in more than 70% of the cases (3). The clinical symptoms of appendicitis may considerably overlap with other causes of abdominal pains (4). This necessitates the use of other diagnostic treatments, especially fast and available methods (5). Therefore, in 30% of the cases, it is impossible to have a definitive diagnosis before performing the surgery (6). Among the various imaging techniques, medical ultrasound as an available, non-intrusive technique is the first-line diagnostic imaging for the examination of most patients suspected of developing appendicitis with ambiguous clinical evidence (7).

Almost 10% of the population develops acute appendicitis (8). Despite having access to newer diagnostic methods, the number of misdiagnosed cases of appendicitis remained fixed between 1987 and 1997 (15.3%) (9, 10). The rate of negative appendectomy in females was even higher than this value and was 23.2% during their fertile years. The highest rate of negative appendectomy was recorded in females over 80 years (11).

Computed tomography (CT) with a sensitivity of 96% and specificity of 97% used to be the first-line method for the examination of acute abdominal pain (12, 13). However, considering the tendencies of patients to avoid exposure to X-ray and the increased risk of developing cancer as a result of using this method (13), efforts have been made to reduce the exposure to X-ray while undergoing diagnostic tests, particularly in children. Acute appendicitis is an important disease requiring immediate abdominal surgery (14) and its timely and correct diagnosis could considerably reduce its severe and unpleasant complications. Despite the existence of advanced diagnostic treatments, a significant number of patients initially diagnosed with

acute appendicitis show negative laparotomy. Since medical ultrasound is a non-intrusive, non-expensive, and available diagnostic method, we attempted to study the accuracy of this method.

2. Methods

2.1. Design and Setting

This retrospective cohort study was performed at Ahvaz Imam Khomeini Hospital with 2,160 emergency department visits per year.

2.2. Inclusion Criteria of the Study

The study population included patients between 5 and 70 years of age who presented with symptoms indicative of acute appendicitis. Consecutive emergency department patients between May 10, 2014, and April 31, 2015, were registered.

2.3. Exclusion Criteria of the Study

Patients were excluded if they left before being officially discharged, if they had a previous appendectomy, or if the ultrasound order was not placed by an emergency physician.

2.4. Methods and Measurements

Since this research was informed by the hospital and the clinical information, the records of the patients were collected from the archives of the hospital. The records of outpatients and inpatients of this hospital were studied to get the necessary information about the patients such as their gender, age, the initial radiological reports indicating the occurrence or non-occurrence of acute appendicitis, and post-appendectomy reports to allow for the comparison of results.

2.5. Analysis

The Chi-squared and *t*-tests were administered using SPSS to compare, assess, and measure the sensitivity, specificity, PPV, and NPV from the collected data. The level of significance for the above-mentioned tests was set at $P < 0.05$.

3. Results

A total of 163 study subjects met the inclusion criteria (Figure 1) that 61.34% ($N = 100$) of the study subjects were female. The age of the subjects ranged from 6 to 63 years (Table 1). For better analyses of the study population, the subjects were categorized into two groups of under 15 and over 15 years of age. A total of 93 participants were under

15 years comprising 57.05% of the whole population while 70% of the participants were over 15 years of age comprising 42.95% of the population. The accuracy, sensitivity, and specificity were 98.1, 96, and 100%, respectively. The positive predictive value was 100% and the negative predictive value was 82.35% (diagnostic accuracy in Table 2). The following results were obtained for all the patients based on the initial medical ultrasound and by comparing it with the post-surgery diagnoses of the surgeons.

Table 1. Patient Characteristics (n = 163)

Patients	n (%)
Gender	
Male	63 (38.66)
Female	100 (61.34)
Age	
15 > years	93 (57.05)
15 < years	70 (42.94)
Age range (year)	6 - 63

3.1. Results in the Studied Female Subjects

Of the 100 assessed female individuals, 85 subjects had a positive medical ultrasound and consequently underwent surgery during which, evidence of appendicitis was observed. In 15 cases in which the evidence of appendicitis ultra-sonography evidence was not observed, we had six misdiagnoses (diagnostic accuracy in Table 2). These patients were relieved of their pains after administering medical abdominal treatments and released later while four cases were false-negative.

3.2. Results in the Studied Male Subjects

Of the 63 assessed male individuals, 44 individuals had a positive medical ultrasound, which was compatible with in-surgery diagnoses. In the remaining 19 cases, which were negative based on medical ultrasound examinations, there were two cases of incorrect medical ultrasound results (Table 2 diagnostic accuracy).

3.3. Results in the Studied Under 15-Year-Old Subjects

This category covered 93 patients, for which the medical ultrasound results and post-surgery diagnoses were compatible (diagnostic accuracy in Table 2).

3.4. Results in the Studied Over 15-Year-Old Subjects

This category covered 70 patients with 50 cases of positive medical ultrasound results that were compatible with

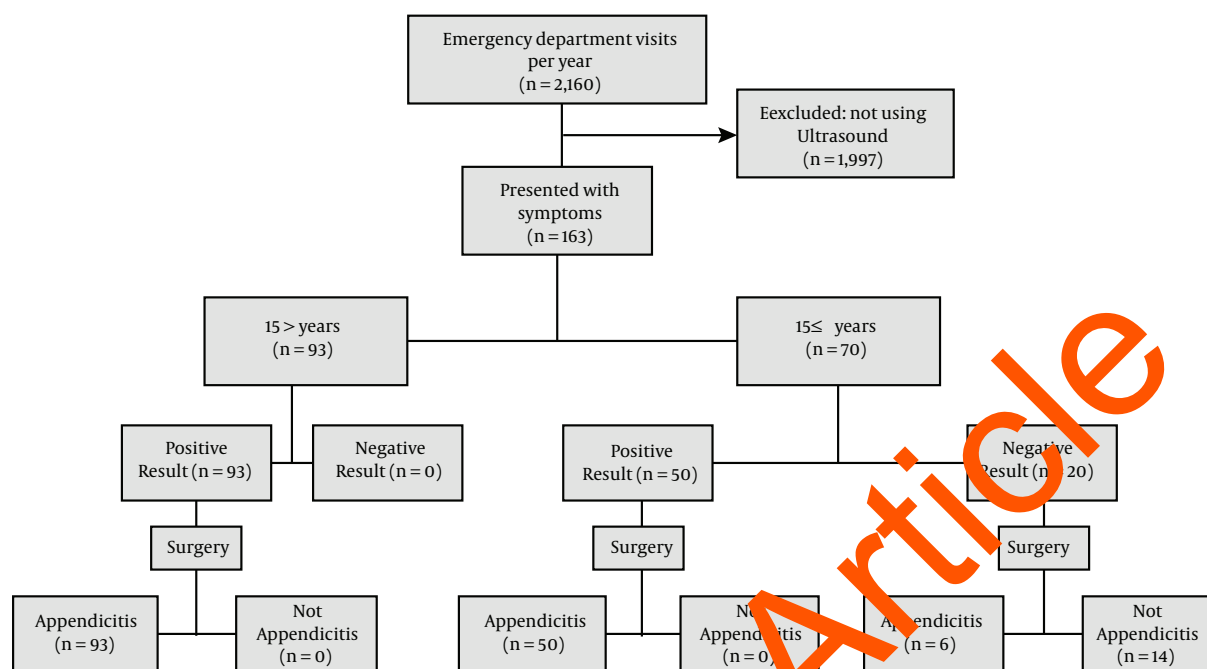


Figure 1. STARD flow diagram

Table 2. Sensitivity and Specificity Values for Age and Gender with the Use of Ultrasound for the Diagnosis of Acute Appendicitis

Patients	Number of Patients	Sensitivity (%)	Specificity (%)	PPV (%)	NPV (%)	Diagnostic Accuracy (%)
Female	100	89.4	100	100	73.33	94.7
Male	63	95.6	100	100	89.4	97.8
15 > years	93	100	100	100	100	100
15 ≤ years	70	89.2	100	100	70	94.06
Total	163	92.3	100	100	82.35	98.1

in-surgery diagnoses. The remaining 20 medical ultrasound results were negative for acute appendicitis, six of which were misdiagnosed (false negative) (Diagnostic accuracy in Table 2).

4. Discussion

Patients with abdominal pain in the emergency department require imaging to determine the need for surgery. This study showed that the highest sensitivity was observed in under-15 male subjects considering the results obtained from different age groups, studying the genders and the applied study objectives, which were in the position of trust on the part of surgeons in medical ultrasound reports. Specificity and PPV were 100% for both age and gender groups. However, NPV and diagnostic accuracy were higher in under-15 male subjects.

A previous study reported that in children, ultrasound helps to reduce negative appendectomy and perforation rate (15). The results obtained from a study showed that the sensitivity and specificity of ultrasound are 92.3% and 94.7% (16), respectively. Another study showed that ultrasonography had a high accuracy in diagnosing acute appendicitis and it reduces negative appendectomies (17). However, D'Souza et al. said that ultrasonography commonly does not visualize the appendix and it has a low sensitivity for appendicitis (18). The diagnosis of a normal appendix on ultrasound seems sufficiently accurate to deprive appendicitis with trust, while positive ultrasound should be expounded in continuity with the clinical aspect in impressing the decision to operate (19).

Using ultrasound and CT scan should normally be done to detect acute appendicitis. However, in terms of its benefits, ultrasound should be the first step (20) in the

care of patients with lower abdominal pain after physical examination (21). It also plays an important role in assessing appendicitis in pregnant women, especially in the first trimester, and often contributes to a definite situation (22).

Although the use of ultrasound as the first method of imaging for the diagnosis of appendicitis in children has increased over the past 5 years, more than 40% of children still undergo CT scan during their pre-operation assessment (23). Ultrasound may be a useful tool for examining children suspected of appendicitis, regardless of age and sex (24). In children with suspected acute appendicitis, a radiation-free diagnostic imaging of ultrasonography selectively followed by MRI is feasible and comparable to CT (25). Ultrasound sensitivity improves appendicitis with a longer duration of abdominal pain, while CT shows a high sensitivity regardless of the duration of pain (26). MRI can be compared with ultrasonography with the use of CT in detecting perforated appendicitis. However, both strategies incorrectly categorize up to half of the patients with perforated appendicitis as having simple appendicitis (27). To minimize the exposure to radiation in children, improvement should be made in the operation and acceptance of ultrasound as the main method of imaging of abdominal pain in community hospitals (28). Point-of-care ultrasonography, when performed in an emergency for the diagnosis of acute appendicitis, recorded a high sensitivity of 92.3% and specificity of 95.8% and had a positive impact on the clinical decision making of emergency physicians (29). This study showed that ultrasonography and CT have first-line diagnostic tool for acute appendicitis and CT should be performed for patients with unresponsive ultrasound findings (30). In a systematic review and meta-analysis, the susceptibility of the United States to the diagnosis of acute appendicitis was 69% (95% CI, 67-79%) and 81% (95% CI, 88-73%) (31). Another meta-analysis showed that CT and MRI have a high risk of diagnosing clinical acute appendicitis in children, which is generally significant (32). Comparing the diagnostic accuracy, the difference between clinical examinations and ultrasound was not significant. The difference between the diagnostic accuracy of clinical and laboratory findings and between ultrasonography and laboratory tests were statistically significant (33). Primary ultrasound can be as effective as CT in patients with acute appendicitis when the results are definite (34). Ultrasound is an accurate, safe, and reliable method with a sensitivity of 92.7%, specificity of 94.5%, and accuracy of 93%, in detecting suspected cases of acute appendicitis that can help to minimize appendectomies and negative percutaneous rates (35).

4.1. Conclusion

The results showed that the medical ultrasound reports could be considered more credible in diagnosing acute appendicitis in under-15 male subjects, which paves the way for the more accurate planning of treatment and presenting patients with abdominal pains for surgery. In addition, non-surgical procedures could be administered for both genders and age groups with stronger certainty and confidence in negative medical ultrasound reports.

Footnotes

Financial Disclosure: No financial interests related to the material in the manuscript.

Ethical Consideration: The study was retrospective.

References

- Rothrock SG, Crane J. Acute appendicitis in children: emergency department diagnosis and management. *Ann Emerg Med.* 2000;**36**(1):39-51. doi: [10.1067/mem.2000.105658](https://doi.org/10.1067/mem.2000.105658). [PubMed: [10874234](https://pubmed.ncbi.nlm.nih.gov/10874234/)].
- Doria AS, Moineddin R, Kellenberger CJ, Epelman M, Beyene J, Schuh S, et al. Ultrasound or CT for diagnosis of appendicitis in children and adults? A meta-analysis. *Radiology.* 2006;**241**(1):83-94. doi: [10.1148/radiol.2411050913](https://doi.org/10.1148/radiol.2411050913). [PubMed: [16928974](https://pubmed.ncbi.nlm.nih.gov/16928974/)].
- Cover CA, Sternbach G, Charles McBurney: McBurney's point. *J Emerg Med.* 2012;**42**(5):578-81. doi: [10.1016/j.jemermed.2011.06.039](https://doi.org/10.1016/j.jemermed.2011.06.039). [PubMed: [21982626](https://pubmed.ncbi.nlm.nih.gov/21982626/)].
- Kwan KY, Nager AL. Diagnosing pediatric appendicitis: usefulness of laboratory markers. *Am J Emerg Med.* 2010;**28**(9):1009-15. doi: [10.1016/j.ajem.2009.06.004](https://doi.org/10.1016/j.ajem.2009.06.004). [PubMed: [20825931](https://pubmed.ncbi.nlm.nih.gov/20825931/)].
- Birnbaum BA, Wilson SR. Appendicitis at the millennium. *Radiology.* 2000;**215**(2):337-48. doi: [10.1148/radiology.215.2.ro0ma24337](https://doi.org/10.1148/radiology.215.2.ro0ma24337). [PubMed: [10796905](https://pubmed.ncbi.nlm.nih.gov/10796905/)].
- Jones PF. Suspected acute appendicitis: trends in management over 30 years. *Br J Surg.* 2001;**88**(12):1570-7. doi: [10.1046/j.0007-1323.2001.01910.x](https://doi.org/10.1046/j.0007-1323.2001.01910.x). [PubMed: [11736966](https://pubmed.ncbi.nlm.nih.gov/11736966/)].
- Chan I, Bicknell SG, Graham M. Utility and diagnostic accuracy of sonography in detecting appendicitis in a community hospital. *AJR Am J Roentgenol.* 2005;**184**(6):1809-12. doi: [10.2214/ajr.184.6.01841809](https://doi.org/10.2214/ajr.184.6.01841809). [PubMed: [15908535](https://pubmed.ncbi.nlm.nih.gov/15908535/)].
- Sutton D. *A textbook of radiology and imaging.* Churchill Livingstone; 1987.
- Mock K, Lu Y, Friedlander S, Kim DY, Lee SL. Misdiagnosing adult appendicitis: clinical, cost, and socioeconomic implications of negative appendectomy. *Am J Surg.* 2016;**212**(6):1076-82. doi: [10.1016/j.amjsurg.2016.09.005](https://doi.org/10.1016/j.amjsurg.2016.09.005). [PubMed: [27836098](https://pubmed.ncbi.nlm.nih.gov/27836098/)].
- Ahmed ST, Ranjan R, Saha SB, Singh B. Traumatic appendicitis misdiagnosed as a case of haemoperitoneum. *BMJ Case Rep.* 2014;**2014**. doi: [10.1136/bcr-2013-202082](https://doi.org/10.1136/bcr-2013-202082). [PubMed: [24759158](https://pubmed.ncbi.nlm.nih.gov/24759158/)]. [PubMed Central: [PMC4009847](https://pubmed.ncbi.nlm.nih.gov/PMC4009847/)].
- Brunicaardi F, Andersen D, Billiar T, Dunn D, Hunter J, Matthews J, et al. *Schwartz's principles of surgery.* 10th ed. McGraw-Hill; 2014.
- Yacoe ME, Jeffrey RB Jr. Sonography of appendicitis and diverticulitis. *Radiol Clin North Am.* 1994;**32**(5):899-912. [PubMed: [8085003](https://pubmed.ncbi.nlm.nih.gov/8085003/)].
- Fujii Y, Hata J, Futagami K, Hamada T, Mitsuoka H, Teramen K, et al. Ultrasonography improves diagnostic accuracy of acute appendicitis and provides cost savings to hospitals in Japan. *J Ultrasound Med.* 2000;**19**(6):409-14. [PubMed: [10841063](https://pubmed.ncbi.nlm.nih.gov/10841063/)].

14. Townsend CM, Beauchamp RD, Evers BM, Mattox KL. *Sabiston textbook of surgery E-book*. Elsevier Health Sciences; 2016.
15. Pastore V, Cocomazzi R, Basile A, Pastore M, Bartoli F. Limits and advantages of abdominal ultrasonography in children with acute appendicitis syndrome. *Afr J Paediatr Surg*. 2014;**11**(4):293-6. doi: [10.4103/0189-6725.143130](https://doi.org/10.4103/0189-6725.143130). [PubMed: 25323176].
16. Saucier A, Huang EY, Emeremni CA, Pershad J. Prospective evaluation of a clinical pathway for suspected appendicitis. *Pediatrics*. 2014;**133**(1):e88-95. doi: [10.1542/peds.2013-2208](https://doi.org/10.1542/peds.2013-2208). [PubMed: 24379237].
17. Hussain S, Rahman A, Abbasi T, Aziz T. Diagnostic accuracy of ultrasonography in acute appendicitis. *J Ayub Med Coll Abbottabad*. 2014;**26**(1):12-7. [PubMed: 25358207].
18. D'Souza N, D'Souza C, Grant D, Royston E, Farouk M. The value of ultrasonography in the diagnosis of appendicitis. *Int J Surg*. 2015;**13**:165-9. doi: [10.1016/j.ijsu.2014.11.039](https://doi.org/10.1016/j.ijsu.2014.11.039). [PubMed: 25499245].
19. Scrimgeour DS, Driver CP, Stoner RS, King SK, Beasley SW. When does ultrasonography influence management in suspected appendicitis? *ANZ J Surg*. 2014;**84**(5):331-4. doi: [10.1111/ans.12415](https://doi.org/10.1111/ans.12415). [PubMed: 24405944].
20. Park JS, Jeong JH, Lee JI, Lee JH, Park JK, Moon HJ. Accuracies of diagnostic methods for acute appendicitis. *Am Surg*. 2013;**79**(1):101-6. [PubMed: 23317620].
21. Sezer TO, Gulece B, Zalluhoglu N, Gorgun M, Dogan S. Diagnostic value of ultrasonography in appendicitis. *Adv Clin Exp Med*. 2012;**21**(5):633-6. [PubMed: 23356200].
22. Drake FT, Kotagal M, Simmons LE, Parr Z, Dighe MK, Flum DR. Single institution and statewide performance of ultrasound in diagnosing appendicitis in pregnancy. *J Matern Fetal Neonatal Med*. 2015;**28**(6):727-33. doi: [10.3109/14767058.2014.932344](https://doi.org/10.3109/14767058.2014.932344). [PubMed: 24913357]. [PubMed Central: PMC4282618].
23. Kotagal M, Richards MK, Chapman T, Finch L, McCann B, Ormazabal A, et al. Improving ultrasound quality to reduce computed tomography use in pediatric appendicitis: the Safe and Sound campaign. *Am J Surg*. 2015;**209**(5):896-900. discussion 900. doi: [10.1016/j.amjsurg.2014.12.029](https://doi.org/10.1016/j.amjsurg.2014.12.029). [PubMed: 25771132]. [PubMed Central: PMC4426027].
24. Lofvenberg F, Salo M. Ultrasound for appendicitis: Performance and integration with clinical parameters. *Comed Res Int*. 2016;**2016**:5697692. doi: [10.1155/2016/5697692](https://doi.org/10.1155/2016/5697692). [PubMed: 28046133]. [PubMed Central: PMC5156797].
25. Aspelund G, Fingeret A, Gross E, Kessler D, Leung A, Thirumoorthi A, et al. Ultrasonography/MRI versus CT for diagnosis of appendicitis. *Pediatrics*. 2014;**133**(4):586-93. doi: [10.1542/peds.2013-2128](https://doi.org/10.1542/peds.2013-2128). [PubMed: 24590746].
26. Bachur RG, Dayan PS, Bajaj L, Macias CG, Mittal MK, Stevenson MD, et al. The effect of abdominal pain duration on the accuracy of diagnostic imaging for pediatric appendicitis. *Ann Emerg Med*. 2012;**60**(5):582-590 e3. doi: [10.1016/j.annemergmed.2012.05.034](https://doi.org/10.1016/j.annemergmed.2012.05.034). [PubMed: 22841176].
27. Leeuwenburgh MM, Wiezer MJ, Wiarda BM, Bouma WH, Phoa SS, Stockmann HB, et al. Accuracy of MRI compared with ultrasound imaging and selective use of CT to discriminate simple from perforated appendicitis. *Br J Surg*. 2014;**101**(1):e147-55. doi: [10.1002/bjs.9350](https://doi.org/10.1002/bjs.9350). [PubMed: 24272981].
28. Alter SM, Walsh B, Lenehan PJ, Shih RD. Ultrasound for diagnosis of appendicitis in a community hospital emergency department has a high rate of nondiagnostic studies. *J Emerg Med*. 2017;**53**(5):833-8. doi: [10.1016/j.jemermed.2017.01.003](https://doi.org/10.1016/j.jemermed.2017.01.003). [PubMed: 28254811].
29. Gungor F, Kilic T, Akyol KC, Ayaz G, Cakir S, Aksoy M, et al. Diagnostic value and effect of bedside ultrasound on acute appendicitis in the emergency department. *Acad Emerg Med*. 2017;**24**(5):578-86. doi: [10.1111/acem.13169](https://doi.org/10.1111/acem.13169). [PubMed: 28171641].
30. Hwang ME. Sonography and computed tomography in diagnosing acute appendicitis. *Sonol Technol*. 2018;**89**(3):224-37. [PubMed: 29298941].
31. Giljaca V, Nadarevic V, Poropat M, Nadarevic VS, Stimac D. Diagnostic accuracy of abdominal ultrasound for diagnosis of acute appendicitis: Systematic review and meta-analysis. *World J Surg*. 2017;**41**(3):693-700. doi: [10.1007/s12018-016-3792-7](https://doi.org/10.1007/s12018-016-3792-7). [PubMed: 27864617].
32. Zhang H, Li H, Chen J, Zhu D, Byanju S. Ultrasound, computed tomography or magnetic resonance imaging - which is preferred for acute appendicitis in children? A Meta-analysis. *Pediatr Radiol*. 2017;**47**(2):186-96. doi: [10.1007/s00247-016-3727-3](https://doi.org/10.1007/s00247-016-3727-3). [PubMed: 27815615].
33. Ferrarise A, Falcone A, Solej M, Bono D, Moretto P, Dervishi N, et al. Surgeon's clinical valuation and accuracy of ultrasound in the diagnosis of acute appendicitis: A comparison with intraoperative evaluation. Five years experience. *Int J Surg*. 2016;**33** Suppl 1:S45-50. doi: [10.1016/j.ijsu.2016.05.052](https://doi.org/10.1016/j.ijsu.2016.05.052). [PubMed: 27255128].
34. Koo HS, Kim HC, Yang DM, Kim SW, Park SJ, Ryu JK. Does computed tomography have any additional value after sonography in patients with suspected acute appendicitis? *J Ultrasound Med*. 2013;**32**(8):1397-403. doi: [10.7863/ultra.32.8.1397](https://doi.org/10.7863/ultra.32.8.1397). [PubMed: 23887949].
35. Shirazi AS, Sametzadeh M, Kamankesh R, Rahim F. Accuracy of sonography in diagnosis of acute appendicitis running. *Pak J Biol Sci*. 2010;**13**(4):190-3. [PubMed: 20437687].