

## Case report

### **A first case of tinea imbricata from Iran**

**Seyyed Amin Ayatollahi Mousavi<sup>1</sup>, Samira Salari Sardoi<sup>1,2</sup>, Sadollah Shamsadini<sup>3</sup>**

<sup>1</sup>Department of Medical Mycology and Parasitology, School of Medicine, Medical University of Kerman, Kerman, Iran

<sup>2</sup>Medical Mycology Research Centre, Faculty of Veterinary Medicine, University of Tehran, Tehran, Iran

<sup>3</sup>Department of Dermatology, School of Medicine, Medical University of Kerman, Kerman, Iran

**Received:** April 2009

**Accepted:** May 2009

#### **Abstract**

**Tinea imbricata is an uncommon dermatophytosis caused by the anthropophilic dermatophyte *Trichophyton concentricum* in endemic regions. In the present study, a 10-year-old girl was examined for tinea imbricata. Microscopic examination revealed the presence of hyaline, septate, branching hyphae and its cultures on Sabouraud dextrose agar yielded *T. concentricum*. The patient responded to treatment with oral terbinafine 250mg/day topical clotrimazole (1% ointment), topical miconazole (2% cream) two times daily and potassium permanganate for daily washing for four weeks. In the present study, we reported the first case of tinea imbricate from Iran.**

**Keywords:** Tinea imbricata, Dermatophyte, *Trichophyton concentricum*, Kerman, Iran

#### **Case history**

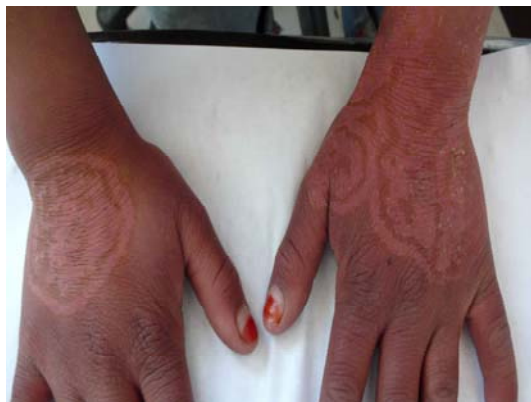A 10-year-old shepherd girl referred to medical mycology laboratory of Kerman, Iran in March 2008. Tavakkol Abad village (patient's habitat) located in eastern of Kerman with warm and dry climate and low annual rainfall. The village inhabitants are living in unhealthy condition. They have poor hygiene, diseases widespread in environment and malaria is reported from the region. She had several itchy hypo pigmentation circles on her wrists and the backside of hands within a short distance of each other; but the other parts of her body were normal (Fig. 1). First lesions appeared approximately 20 days ago. Skin scrapings were microscopically examined in KOH 10% and numerous irregular, branch and

septate hyaline hyphae were observed (Fig. 2). In addition, skin specimens were inoculated on Sabouraud dextrose agar, SDA (Merck, Darmstadt, Germany), Mycosel agar (Difco, USA) and incubated at 28°C for three to four weeks.

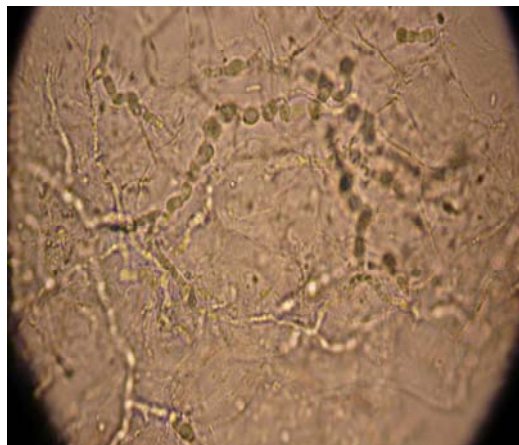
The resulting isolate was identified by using macroscopic and microscopic features [1]. In SDA, the colonies with restricted growth, white to cream colored with yellow-brown reverse, were observed, which became velvety while aging with verrucous to cerebriform aspect (Fig. 3). Microscopic characterizes of *Trichophyton concentricum* showed broad, much branched, irregular hyphae, and both macroconidia and microconidia are absent. In addition, favic chandeliers, which may have "antler" tips

resembling *T. schoenleinii* were seen [2]. In this study, the patient was successfully treated with oral terbinafine 250mg/day, topical clotrimazole (1% ointment), topical miconazole (2% cream) two times daily and

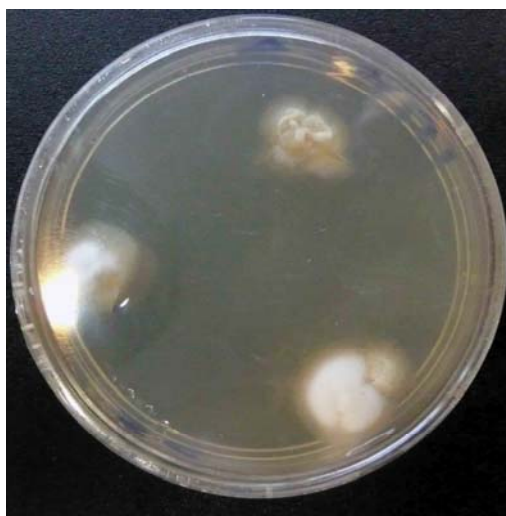potassium permanganate for daily washing for four weeks. To date (after 13 months) any complaint has not been reported about infection relapse from the patient.



**Fig. 1:** Polycyclic and scaly cutaneous lesions backside hands and wrist



**Fig. 2:** Septate, branching fungal hyphae in KOH mount (x400)



**Fig. 3:** Culture of *T. concentricum* on SDA after four weeks incubation, the velvety cream colonies become verrucous to cerebriform with aged

### Discussion

*Tinea imbricata* is an unusual form of tinea corporis caused by the strictly anthropophilic dermatophyte *T. concentricum* [3]. The social consequences of *T. concentricum* infections in Melanesia and Polynesia merit special attention. *Tinea imbricata* is well established in many islands in the southern part of the Pacific Ocean. Infection rates of 18% have been observed

in some villages of Papua and New Guinea [4]. Individual lesions appear on the skin as itchy, non inflammatory, concentric rings that may fuse upon enlargement to form scaly polycyclic or serpiginous plaques [5]. Disease was seen most commonly in rural and tropical regions. *Tinea imbricata* usually affects people living in primitive and isolated conditions [6].

The first case of tinea imbricata was reported in 1789 by Williams Dampier from the island Mindanao a Philippines [7]. Logan and Kobza-Black [8] reported a case of localized tinea imbricata in 23-year-old British nurse in 1998. The patient cure was achieved after a four weeks course of griseofulvin one gram/day. Meites *et al.* [9] reported one case of tinea imbricata in 35-year-old Papua New Guinean man with extensive figurate lesions on skin. The disease is found in both sexes, and some authors have reported predominance in females [10]. Tinea imbricata is observed in all ages, from babies (six months old) to the elderly, and more frequently in farmers and land workers [7,11].

Transmission is usually by direct personal contact between family members sharing household items or from parent to child soon after birth. High humidity and warmth are likely environmental factors in the incidence of infection [12]. Autosomal recessive inheritance has been implicated to play a role in the high susceptibility rates in some regions [13]. Serjeantson and Lawrence [14] suggested that susceptibility to chronic *T. concentricum* infection is recessively inherited and controlled by genes at a single autosomal locus.

Some risk factors can be identified, such as humidity, poor hygiene, as well as genetic and immunological factors [6]. Dietary influences, iron deficiency, and malnutrition have been cited as associated factors, but their precise role has not been determined, as most patients live in conditions of poverty [15]. Tinea imbricata is best example for correlation of series of environmental, genetic immunologic and therapeutic conditions. Despite the distinctive appearance of the lesions, tinea imbricata is most frequently confused with ritual scarification.

This is a significant case of tinea imbricata, which was found in outside of endemic areas. Therefore, because of the existence of tinea imbricata in Kerman, more surveys are required to identify

correctly this uncommon dermatophytosis in other Iran's regions.

### Acknowledgement

We are grateful of the department of medical mycoparasitology, Kerman Afzalipour University of Medical Sciences for their help.

### References

- 1) www.doctorfungus.org/2003/imageban/index.htm.
- 2) www.doctorfungus.org@2005.
- 3) Summerbell RC, Murray PR, Baron EJ, Jorgenson JH. *Trichophyton, Microsporum, Epidermophyton*, and agents of superficial mycoses. In: *Manual of clinical microbiology*, Vol. 2, 8ed. Washington, DC, ASM Press, 2003:1798-1819.
- 4) MacLennan R, O'Keefe MF. Superficial fungal infections in an area of low land New Guinea; clinical and mycological observations. *Australian Journal of Dermatology* 1966; 8: 157-163.
- 5) Hay RJ. Tinea imbricata. *Current Topics in Medical Mycology* 1988; 2: 55-72.
- 6) Bonifaz A, Archer-Dubon C, Sau' A. Tinea imbricata or Tokelau. *International Journal of Dermatology* 2004; 43:506-510.
- 7) Hay RJ, Reid S, Talwat E, Macnamara K. Endemic tinea imbricata. A study on Goodenough, Papua New Guinea. *Transactions of the Royal Society of the Tropical Medicine and Hygiene* 1984; 78: 246-251.
- 8) Logan RA, Kobza-Black. Tinea imbricata in 23-years-old British nurse. *Clinical and Experimental Dermatology* 1998; 13: 232-233.
- 9) Meites Elissa, McClenny Nancy B, Baron Ellen J. A 35-year-old Papua New Guinean man with extensive figurate lesions on skin. *Clinical Infectious Diseases* 2004; 39: 582-583.
- 10) Caire P. 14 cas de tinea imbricata decouverts dans la region tojolabal de l'etat de Chiapas (Sud-ouest du Mexique) caracteristiques mycologyques et remarques sur le traitement par la griseofulvine et le ketoconazole. *Bull Soc Mycol Med* 1984; 13: 73-78.
- 11) Schofield FD, Parkinson AD, Jeffrey D. Observations on the epidemiology, effects

- 
- and treatment of tinea imbricata. *Transactions of the Royal Society of the Tropical Medicine and Hygiene* 1963; 57: 214-227.
- 12) Kwon-Chung KJ, Bennett JE. Dermatophytoses. In: *Medical mycology*. Philadelphia: Lea & Febiger, 1992: 105-161.
- 13) Ravine D, Turner KJ, Alpers MP. Genetic inheritance of susceptibility to tinea imbricata. *Journal of Medical Genetics* 1980; 17:342-348.
- 14) Serjeantson S, Lawrence G. Autosomal recessive inheritance of susceptibility to tinea imbricata. *Lancet* 1977; 1: 13-15.
- 15) Hay RJ, Reid S, Talwat T, Macnamara K. Immune responses of patients with tinea imbricata. *British Journal of Dermatology* 1983; 108: 581-586.

*Address for correspondence:*

Seyyed Amin Ayatollahi Mousavi, Department of Medical Mycology and Parasitology, School of Medicine, Medical University of Kerman, Kerman, Iran

Telfax: +98 341 2480680

Email: aminayatollahi@kmu.ac.ir