

## **Case report**

### **Miliary tuberculosis with empyema, a case report**

**Mohammad Javad Hosseini, Abbas Ali Imani Fooladi**

*Research Center of Molecular Biology, Baqiyatallah University of Medical Sciences, Tehran, Iran*

#### **How to cite this article:**

Hosseini MJ, Imani Fooladi AA. Miliary tuberculosis with empyema, a case report. Jundishapur J Microbiol. 2010; 3(3): 129-32.

**Received:** February 2010

**Accepted:** April 2010

#### **Abstract**

We report a 39 year-old patient who presented with chest pain, malaise, lassitude, anorexia, weight loss, fever, chills, productive coughs, pleural pain in the left thorax area and septic empyema without hemoptysis. Laboratory investigations' including tuberculosis (TB) skin test by PPD, HIV, HBV and HCV serologic tests were negative. The CBC showed anemia and leucocytosis. The ESR was elevated and he had hypoalbuminaemia. Both chest radiograph and high-resolution CT scan showed miliary infiltrates and diffused reticulonodular lung lesions. He was diagnosed with miliary tuberculosis (MTB) via direct staining, PCR and culture from open window region washing sample but not from bronco-alveolar lavage. He was treated with antituberculosis drugs.

**Keywords:** Miliary Tuberculosis, Empyema, *Mycobacterium tuberculosis*

#### **Introduction**

Miliary tuberculosis (MTB) is a type of disseminated and active tuberculosis (TB) that presents radiopathologic signs of TB micronodules as well as microbiologic findings [1]. MTB counts for 1 to 2% of all TB cases and about 8% of all forms of extrapulmonary tuberculosis in immunocompetent individuals [2]. Also, MTB is often under-diagnosed in the elderly, resulting in diagnosis of disseminated TB upon autopsy [3]. The chest radiograph plays an important role in the initial detection and final diagnosis of MTB. Positive sputum smear is found in about one-third of MTB patients [4].

Histological demonstration of granulomas in tissues (e.g. in lung, liver, and bone marrow) is usually required to make a rapid diagnosis. The molecular detection of *Mycobacterium tuberculosis* DNA by polymerase chain reaction is useful. IS6110-specific primer, which can amplify all *M. tuberculosis* complex strains, was used for amplification [5]. The main advantages of PCR are its rapidity, sensitivity and specificity [6].

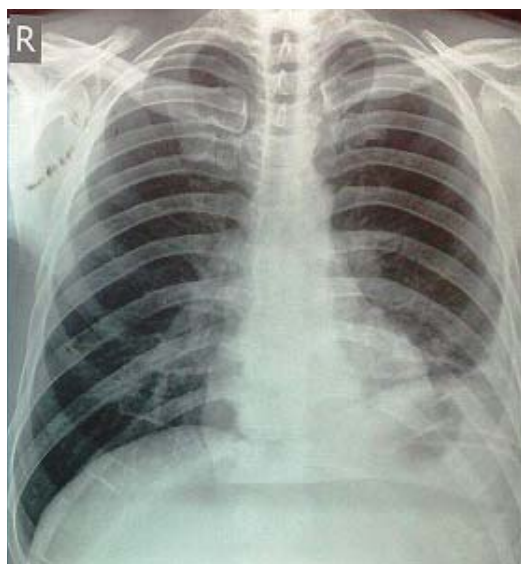#### **Case history**

A 39 year-old smoking man from a middle-class family with a rural background presented with chest pain, malaise,

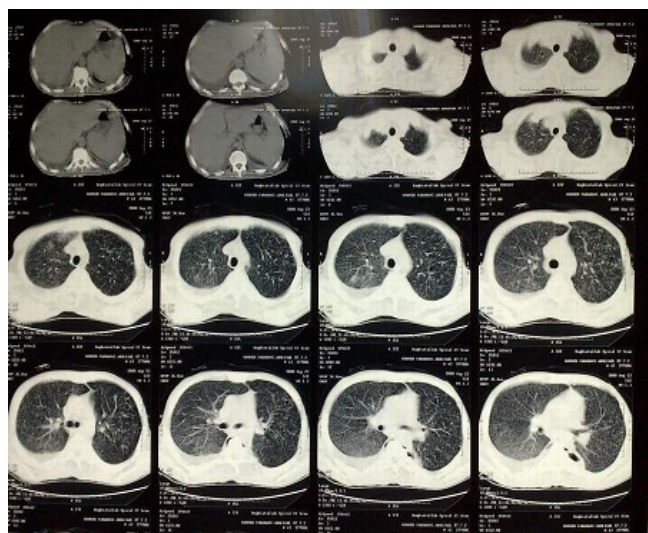
lassitude, anorexia, weight loss, fever, chills, productive coughs, pleural pain in the left thorax area and septic empyema without hemoptysis. He used to live in Japan from 1990 to 2008. He came back to Iran in May 2008. His disease started in Japan and continued here in Iran. He had chest wall pain due to a left pleural effusion that was treated with antibiotics and a chest tube one year ago.

A bacteriologic examination of pleural fluid performed after chest tube showed the presence of methicillin-resistant *Staphylococcus aureus* and the patient

received antibiotics according to the antibiogram. But he returned to our hospital with chest pain and the afore-mentioned signs and symptoms. TB skin test with PPD was negative. There were no laboratory findings indicating immunodeficiency or HIV. The HIV, HBV and HCV serologic tests were negative. The CBC showed anemia and leucocytosis. The ESR was elevated (82mm/hr Wintrobe's method) and he had hypoalbuminaemia. Both chest radiograph and high-resolution CT scan showed miliary infiltrates and diffused reticulonodular lung lesions (Figs. 1, 2).



**Fig.1:** Chest radiograph (X-ray) showing empyema in left lower lobe

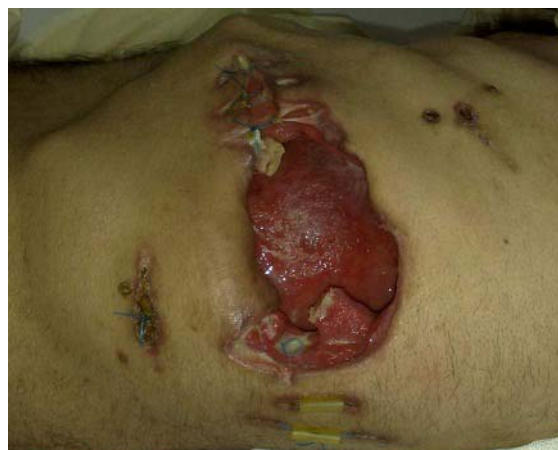

**Fig. 2:** High-resolution computed tomographic scan of the chest showing military infiltrates and diffuse reticulonodular lung lesions

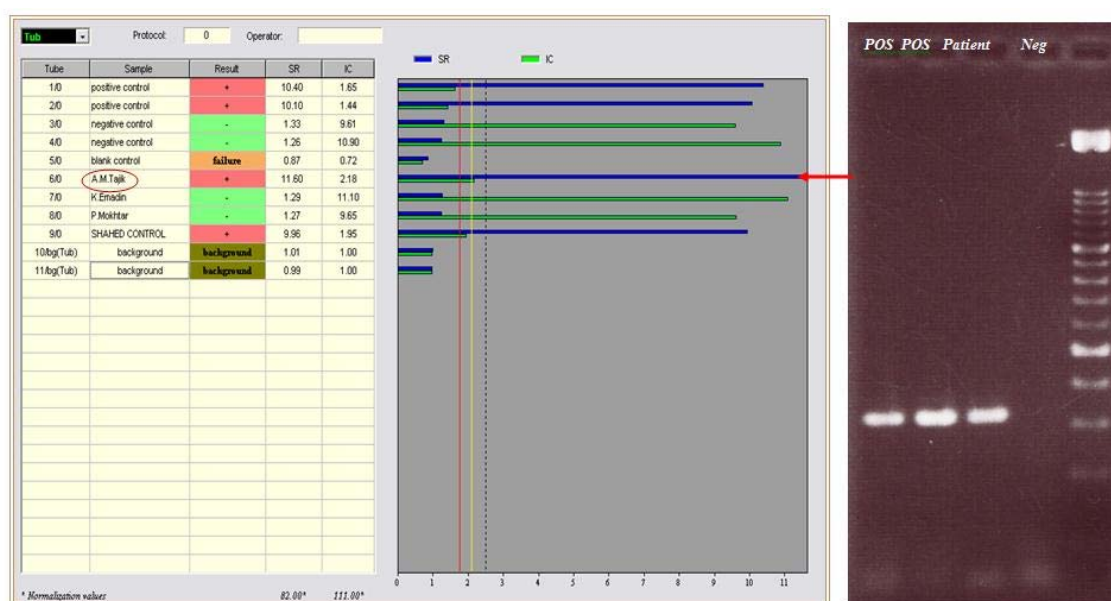
On abdominal CT scans hepatosplenomegaly was confirmed. Pleural effusions necessitated surgical drainage. Bronchoalveolar lavage (BAL) was carried out. BAL and washing samples from open window (Fig. 3) were processed for *M. tuberculosis* and polymerase chain reaction to rule out the possibility of mycobacterial infection. The direct smears were stained by standard Zeil Nelson staining technique. BAL samples staining in were negative for acid-fast bacilli. However, washing samples from open window were positive. The

samples were subjected to the standard phenol chloroform DNA extraction process and were cultured on Lowen-Stein medium [6]. The extracted DNA was then amplified. PCR was carried out on open window region washing sample (OPWS) using IS 6110 insertion sequence-based primers yielding a 390 base pair (bp) product (Fig. 3) [6]. The PCR result from related washing samples from open window indicated the existence of *M. tuberculosis* infection. *M. tuberculosis* was grown after 40 days in Lowensten-Jensen medium. Immediately

after diagnosis of TB, oral antituberculous treatment with four drugs was started (isoniazide: 300mg/daily, rifampin 600mg/daily, pirazinamide 1.5g/daily, ethambutol 1g/daily) for two months and then continued with two drugs (isoniazide: 300 mg/daily, Rifampin 600mg/daily) for four months. Finally, in order to prevent bone tuberculosis, we continued treatment with two drugs (isoniazide: 300mg/daily, rifampin 600mg/daily) for two more months. The patient was treated completely.



**Fig. 3:** Open window region in chest of patient



**Fig. 4:** FLASH-PCR was carried out using using IS 6110 insertion sequence based primers giving 390 base pair(bp) product specific for Mycobacterium tuberculosis. Tub No1= Positive Control, Tub No 2= positive control, Tub No3= Negative control, Tub No 6= patient's sample

## Discussion

Extrapulmonary tuberculosis accounts for up to one third of all cases of tuberculosis [7]. The clinical manifestations and laboratory findings of MTB may be insidious and non-specific. [1,8,9]. In the current case, he had no specific clinical manifestations or laboratory findings. In miliary TB, hematologic abnormalities such as anaemia, leukopenia, leukocytosis, monocytosis, leukemoid reactions, thrombocytopenia, agranulocytosis and pancytopenia are well

recognized but their significance is controversial. Erythrocyte sedimentation rate is usually elevated but albumin is frequently decreased in MTB [10].

In the present study, elevated ESR and hypoalbuminaemia were observed. These findings disappeared with treatment. Miliary infiltrates and radiologic features were present in our patient; these radiologic features have been reported in 40-100% of patients with miliary TB [8,10]. Preliminary diagnosis of TB is based on AFB in

suspicious samples. Acid-fast bacilli have been seen in TB granulomas in 0-44% in previous studies [10]. Advances in molecular techniques have provided a new approach to the rapid diagnosis of TB by PCR. Depending on the clinical material, sample preparation method and target nucleic acid, the sensitivity of *M. tuberculosis* detection by PCR varies between 42% and 100% [11,12]. TB for our patient in this study was diagnosed through OPWS which is an exceptional and rare specimen in the world. Our patient had AFB staining confirmed by PCR study and culture in Lowenstein Jensen medium.

### References

- 1) Al-Jahdali H, Al-Zahrani K, Amene P, *et al.* Clinical aspects of miliary tuberculosis in Saudi adults. *Int J Tuberc Lung Dis.* 2000; 4(3): 252-5.
- 2) Miliary tuberculosis: new insights into an old disease. *Lancet Infect Dis.* 2005; 5(7): 415-30.
- 3) McElvanna K, Skelly RT, O'Neill C, Spence GM. Miliary tuberculosis causing multiple intestinal perforations in an immigrant worker. *Ulster Med J.* 2008; 77(3): 206-8.
- 4) Kwong JS, Carignan S, Kang EY, Muller NL, Fitz Gerald M. Miliary tuberculosis diagnostic accuracy of chest radiography. *Chest.* 1996; 110: 339-42.
- 5) Honoré-Bouakline S, Vincensini JP, Giacuzzo V, *et al.* Rapid diagnosis of extrapulmonary tuberculosis by PCR: impact of sample preparation and DNA extraction. *J Clin Microbiol.* 2003; 41(6): 2323-9.
- 6) Imani Fooladi AA, Hosseini MJ, Azizi T. Splenic tuberculosis: a case report. *Int J Infect Dis.* 2009; 13: e273-5.
- 7) Tinsa F, Essaddam L, Fitouri Z, *et al.* Extra-pulmonary tuberculosis in children: a study of 41 cases. *Tunis Med.* 2009; 87(10): 693-8.
- 8) Acera T, Karnaka I, Ekincia S, Talimb B, Kiper N, Senocak ME. Multiple jejunoileal perforations because of intestinal involvement of miliary tuberculosis in an infant. *J Ped Surg.* 2008; 43: E17-E21.
- 9) Boțianu PVH, Boțianu A, Sin A, *et al.* Diagnostic and therapeutic difficulties in a case of tuberculous empyema with atypical mycobacteria. *J de Chirurgie Ias.* 2007; 3(1): 45-51.
- 10) Mert A, Bilir M, Tabak F, *et al.* Miliary tuberculosis: clinical manifestations, diagnosis and outcome in 38 adults. *Respirology.* 2001; 6: 217-24.
- 11) Bouakline SH, Vincensini JP, Tuncer S, *et al.* Rapid diagnosis of extrapulmonary tuberculosis by PCR: impact of sample preparation and DNA extraction. *J Clin Microbiol.* 2003; 41(6): 2323-9.
- 12) Viedma DG. Rapid detection of resistance in *Mycobacterium tuberculosis*: a review discussing molecular approaches. *Clin Microbiol Infect.* 2003; (9)5: 349-59.

### Address for correspondence:

Abbas Ali Imani Fooladi, Research Center of Molecular Biology, Baqiyatallah, University of Medical Sciences, Tehran, Iran  
 Tel: +9821 88039883, Fax: +9821 88039883  
 Email: Imanifooladi.a@gmail.com