

Original article

Study on growth of *Toxoplasma gondii* tissue cyst in laboratory mouse

Hossein Hooshyar, Parvin Rostamkhani, Mohsen Arbabi

Department of Parasitology, School of Medicine, Kashan University of Medical Sciences, Kashan, Iran

Received: July 2009

Accepted: November 2009

Abstract

Introduction and objective: *Toxoplasma gondii* is a widespread protozoan parasite that infects human and animals. Tissue cyst of *T. gondii* is an important source of human and other hosts infection including cats as definitive host. This study was carried out to determine growth of *T. gondii* tissue cyst in laboratory syrian mouse.

Materials and methods: Fifteen mice in three groups were infected with *T. gondii* by intraperitoneally inoculation. The mice of each group killed after two, three and four months. Ten smears of brains were prepared from each group and examined microscopically for *Toxoplasma* tissue cyst. The diameter of 17 cysts from each group was determined and recorded and the mean size in each group calculated.

Results: The mean diameters of tissue cysts were $49.4 \times 44.8 \mu\text{m}$ after two months and $64.5 \times 55.7 \mu$ after three months of inoculation. After four months the mean diameter of tissue cyst reached to $60.6 \times 53.48 \mu$. The volume of tissue cysts grew within two and three months after inoculation but after four months the growth leveled off.

Conclusion: The present study showed that the mean diameter of tissue cyst grew during the first three months and after four months became stable and some may get compacted and lesser.

Keywords: *Toxoplasma gondii*, Tissue cyst, Mouse

Introduction

Toxoplasmosis is a zoonotic protozoan disease that infects human and warm-blooded animals as intermediate hosts [1]. In human, the infection is mostly asymptomatic or it may cause lymphadenitis, fever, myalgia and maculopapular rash [2]. The major clinical problem in human is congenital infection of fetus resulted from primary infection during pregnancy which causes abortion, intracerebral calcification, chorioretinitis, hydrocephaly, microcephaly and psychomotore disturbances. Ocular

toxoplasmosis can occur after birth and results in congenital infection. In immunocompromised person also toxoplasmosis can cause severe and fatal encephalitis [2,3]. Today, up to 200 different animals are known as intermediate host for *Toxoplasma gondii* including most livestock and human [1]. It is important for transmission of tissue cyst between intermediate hosts and definitive host [4].

The definitive hosts are domestic cats and other members of Felidae family [1]. Although the oocyst shedding period time in cats is low but it can excrete millions

resistant *T. gondii* oocyst into the environment [5]. Mice and birds probably are most suitable potential source of infection for cats. Cats acquire infection through hunting small animals such as mice, birds and they can also be infected by consuming disposed and undercooked meat released in the environment by human [4].

One study in China showed that antibodies to *T. gondii* were found in 36 of 124 trapped mice but were not found in sera of 104 laboratory-bred mice [7]. Ghorbani *et al.* [8] showed 29% of domestic birds were seropositive for *T. gondii* in Iran. Keshavarz and Ebrahimi [9] showed that 10.5% of small birds in Kerman were infected by *T. gondii*. Tissue cysts were more found in the brain than in other organ in mice and rats [6] and may persist along the life of the mice [3].

The earlier study showed that young tissue cyst in rat is very small but were up to 50 μ in diameter after 72 to 75 days and may reach a diameter of 200 μ (1,10). The object of present study was to determine the growth of *T. gondii* tissue cyst including size and duration of growth in mice as a potential source of definitive host infection.

Material and methods

In this study a wild and unknown strain of *T. gondii* obtained from a cat in Kashan [11] that hold in laboratory mice was used. About 2g of brain of infected syrian mice homogenized with 1ml sterile normal saline, 1000IU penicillin, 0.1g streptomycin and a 20% suspension were prepared [12]. Fifteen syrian mice in three groups (five mice in each group) were selected and 1ml of homogenate was inoculated into each mouse intraperitoneally [12]. Three groups of animals were housed in three separated cages. After two months the mice of group one and after two and three months the mice

of group two and three were killed respectively. Ten smears of brains were prepared from each group and examined under light microscope for *Toxoplasma* tissue cyst. The diameter of 17 cysts from each group determined and recorded and then the mean size in each group was calculated.

Results

The tissue cysts were often spherical and vary in size. The diameter measurement of 17 tissue cysts in different smear showed that they were as small as 20 \times 20 μ and the biggest of them was 124.8 \times 98.8 μ (Fig. 1). The result of this study showed that the mean diameters of tissue cysts were 49.4 \times 44.8 μ after two months and 64.5 \times 55.7 μ after three months of inoculation. After four months the mean diameters of tissue cysts reached to 60.6 \times 53.48 μ (Table 1). According to the results of table one, the volume of tissue cysts grew within two and three months after inoculation but after four months the level of growth was stopped.

Discussion

The importance of tissue cyst in the brain and meat of animals is to be a potential source of infection for human and cats. Feeding on only infective oocyst cause infection in less than 50% of cats while 100% of cats that ingested infection tissue cyst and shedding oocyst got infected [1]. In immunocompatant person, the tissue cysts of *T. gondii* are harmless and may persist for life. The importance of tissue cyst is in immunosuppressed individuals become reactivation of rupture cyst in brain is often fatal [13].

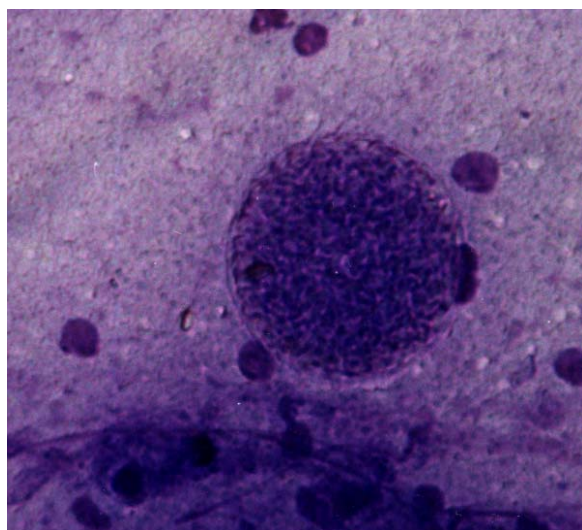


Fig. 1: Tissue cyst of *T. gondii* in brain smears of syrian mouse (Giemsa staining)

Table 1: Size of tissue cyst in brain of syrian mice after 2, 3 and 4 months

Time	Size (μ)		
	2 months	3 months	4 months
1	52×46.8	52 × 41.6	50 × 42.5
2	52 × 52	72.8 × 62.4	60 × 52.5
3	72.8 × 60.38	52 × 64.8	20 × 20
4	54.08 × 41.6	124.8 × 98.8	60 × 57.5
5	41.6 × 33.28	43.68 × 41.6	75 × 70
6	31.2 × 21.84	52 × 31.2	25 × 22.5
7	57.2 × 41.6	62.6 × 52	65 × 60
8	49.9 × 41.6	36.4 × 36.4	62.5 × 62.5
9	41.6 × 32.24	46.8 × 41.6	62.5 × 52.5
10	62.4 × 62.4	31.2 × 36.4	80 × 75.5
11	52 × 42.6	62.4 × 52	77.5 × 77.5
12	41.6 × 41.6	62.4 × 62.4	80 × 57.5
13	41.6 × 41.6	67.6 × 52	65 × 55
14	52 × 41.6	78 × 52	70 × 45
15	31.2 × 29.13	72.8 × 72.8	60 × 50
16	52 × 46.8	114.4 × 93.6	55 × 55
17	53.04 × 52	36.4 × 36.4	62.5 × 52.5
Mean size	49.4 × 42.82	64.5 × 55.7	60.6 × 53.4

Tissue cyst is often spheroidal and may be found in animals as early as eight days after inoculation. Young tissue cyst is very small and its identification is difficult as the bradyzoites are divided by endodyogeny, the tissue cyst grows [6]. The older tissue cyst contains hundreds of bradyzoites and may reach a diameter of 200 μ [1]. The present study showed that the mean

diameter of tissue cyst grew for three months and after four months is stable and some may get compacted and lesser. It may be due to interaction with immunosystem after this time.

Van der Waaij [14] in a study of the growth of tissue cyst in mouse brain of showed that the tissue cyst grew uniformly in size up to 12 week and then the growth

leveled off. He found that the tissue cysts were up to 70 μ in diameter and the mean diameter of 100 tissue cysts was 42 μ . In the present study, we found diameter of tissue cyst from 20 μ up to 124.8 μ . Dubey and Beattie [1] mentioned that the tissue cyst reached up to 200 μ in diameter. In another study, Dubey [10] measured tissue cyst in the brain of rats fed on oocyst 72 to 75 days before, the tissue cysts were up to 50 μ in diameter. It seems that tissue cyst size depends on cyst age, the type of host cell parasitized and animal species that used for inoculation.

Conclusion

The present study showed that the mean diameter of tissue cyst grew for three months and after four months is stable and may some deal compacted and lesser

Acknowledgment

We gratefully acknowledge Mr Mirzaie and Mr Salman of the School of Medicine, Kashan University of Medical Sciences.

References

- 1) Dubey JP, Beattie CP. Toxoplasmosis of animal and man. CRC press, Florida 1988.
- 2) John DT, Petri W. Markell and Voges Medical Parasitology, 9th ed, WB Saunders Co. 2006.
- 3) Jones JL, Dubey JP. Waterborne toxoplasmosis-recent developments. *Exp Parasitol.* 2009; (In press)
- 4) Tenter Astrid M. *Toxoplasma gondii* in animals used for human consumption. *Mem Inst Oswaldo Cruz, Rio de Janeiro.* 2009; 104(2): 364-9.
- 5) Dubey JP, Su C, Cortés JA, Sundar N. *et al.* Prevalence of *Toxoplasma gondii* in cats from Colombia, South America and genetic characterization of *T. gondii* isolates. *Vet Parasitol.* 2006; 141(1-2): 42-7.
- 6) Dubey JP, Lindsay DS, Speer A. Structures of *Toxoplasma gondii* tachyzoites, bradyzoites and sporozoites biology and development of tissue cysts. *Clin Microbiol Rev.* 1998; 11(2): 267-99.
- 7) Zhang SY, Jiang SF, He YY, Pan CE, Zhu M, Wei MX. Serologic prevalence of *Toxoplasma gondii* in field mice, *Microtus fortis*, from Yuanjiang, Hunan province. *China J Parasitol.* 2004; 90(2): 437-8.
- 8) Ghorbani M, Gharavi MJ, Kahn moui A. Serological and parasitological investigations on *Toxoplasma* infection in domestic fowls in Iran. *Iranian J Public Health.* 1990; 19(1-4): 17-9.
- 9) Keshavarz Valian H, Ebrahimi A. Prevalence of *Toxoplasma gondii* in birds of Kerman city by serological and parasitological methods. *Iranian J Public Health.* 1994; 23(1-4): 33-25.
- 10) Dubey JP. Pathogenicity and infectivity of *Toxoplasma gondii* oocyst for rats. *J Parasitol.* 1996; 82: 951-56.
- 11) Hooshyar H, Rostamkhani P, Talari S, Arbabi M. *Toxoplasma gondii* infection in stray cats. *Iranian J Parasitol.* 2007; 2(1): 18-22.
- 12) Beverley JKA. The laboratory diagnosis of Toxoplasmosis, In: Dyke SC, Editor. Recent advances in clinical pathology (3rd ed). Series little, Brown Boston 1960. 38-57.
- 13) Freyre A, Falcon J, Mendez J, Gonzalez M. *Toxoplasma gondii*: Protection against colonization of the brain and muscles in a rat model. *Exp Parasitol.* 2008; 119: 252-5.
- 14) Van der Waaji D. Formation growth and multiplication of *Toxoplasma gondii* cyst in mouse brains. *Trop Geogr Med.* 1959; 11: 345-60.

Address for correspondence:

Hossein Hooshyar, Department of Parasitology, School of Medicine, Kashan University of Medical Sciences, Kashan, Iran
Tel: +98 361 5550021-5; Fax: +98 3615575057
Email: hooshyar4@yahoo.com