



Relapse of a *Plasmodium vivax* Infection in an Iranian Patient: A Case Report

Aliehsan Heidari,^{1,*} Susan Sheikhi,¹ Parviz Fallah,² and Hossein Keshavarz³

¹Department of Parasitology, School of Medicine, Alborz University of Medical Sciences, Karaj, IR Iran

²Department of Hematology, School of Paramedical Sciences, Alborz University of Medical Sciences, Karaj, IR Iran

³Department of Medical Parasitology and Mycology, School of Public Health, Tehran University of Medical Sciences, Tehran, IR Iran

*Corresponding author: Aliehsan Heidari, Department of Parasitology, School of Medicine, Alborz University of Medical Sciences, Karaj, IR Iran. Tel: +98-2634349801, E-mail: aliehsan2001@yahoo.com

Received 2017 June 03; Accepted 2017 October 28.

Abstract

Introduction: *Plasmodium vivax* is the most prevalent in the malaria endemic areas of Iran. The number of *Plasmodium vivax* sporozoites that get to the liver remain latent, and after several months or years of inappropriate treatment period, they can reactivate and leads to the clinical manifestation of malaria.

Case Presentation: A 49-year-old male was referred to a private clinical center in the capital city of Iran, Tehran, in October 2016 due to fever, chills, nausea, appetite, headache, and weakness. The patient had a history of clinical vivax malaria 1-year prior in Chabahar, in the province of Sistan and Baluchistan. The light microscope and nested PCR were applied for detecting the vivax malaria infection. In this patient, the relapse of *P. vivax* occurred after about 12 months, following the primary malaria infection.

Conclusions: The report underlines that relapses should be considered in febrile individuals returning from malaria endemic areas of the country to malaria free areas. In addition, it highlights the occurrence of relapse in the patient with history using primaquine for a radical cure of liver latent parasites.

Keywords: Relapse, Malaria, Primaquine, Iran, *Plasmodium vivax*

1. Introduction

Malaria continues to be an important febrile infectious disease in some areas of the world (1, 2). Out of 5 *Plasmodium* species that infect humans, *Plasmodium vivax* is the most prevalent in the malaria endemic regions of Iran (3). The number of *Plasmodium vivax* sporozoites that get to the liver remain latent (hypnozoite). After several months or years of inappropriate treatment period, hypnozoites can reactivate and again initiate tissue and blood schizogony that leads to the clinical manifestation of malaria (4-6).

It is not usually possible to make a diagnosis of a relapse from a new infection in malaria endemic areas, where new malaria cases still occur due to transmission of *Plasmodium* by mosquito biting (7-9). Meanwhile, malaria patients who leave the malaria endemic areas after the treatment period are appropriate evidence for the exhibition of a relapse.

Emergent relapses in areas such as Iran, which have planned to eliminate malaria, could be considered as an obstacle for accessing the elimination, due to the fact that malaria parasites are again introduced to the mosquito's vector via relapsed malaria patients and vectors that con-

tinue to transmit parasites to humans. In this case report, we describe the appearance of clinical *P. vivax* malaria in a patient out of the malaria endemic area. The patient had a history of clinical malaria and treatment with chloroquine and primaquine in Chabahar, which is the malaria endemic area of Iran.

2. Case Presentation

A 49-year-old male was referred to a private clinical center in the capital city of Iran, Tehran, in October 2016, due to fever, chills, nausea, appetite, headache, and weakness. The patient had a history of clinical vivax malaria 1-year prior in Chabahar, in the province of Sistan and Baluchistan. The province of Sistan and Baluchistan is located south-east of Iran and bordering Pakistan and Afghanistan. This province is the main malaria endemic area of Iran. However, Tehran is a region free from malaria and there has been no malaria transmission in at least the past 4 decades (10). The patient didn't travel to any malaria endemic areas and he had no risk of exposure to the malaria infection during the previous year.

The introduction of laboratory examinations indicated white blood cells of $9,300/\mu\text{L}$ with neutrophil 88.5%. The haemoglobin was 11.7 g/dL. The patient's platelet level was $156,000/\mu\text{L}$. Microcytic hypochromic RBC was reported. Trophozoite and schizont forms of *Plasmodium vivax* were observed in Giemsa peripheral blood smear under a light microscope (Figure 1). Other laboratory test findings were in the normal ranges.

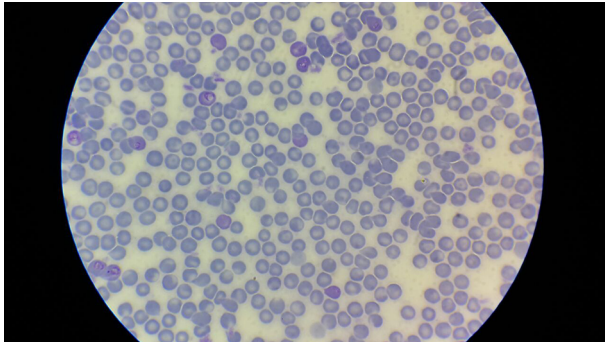


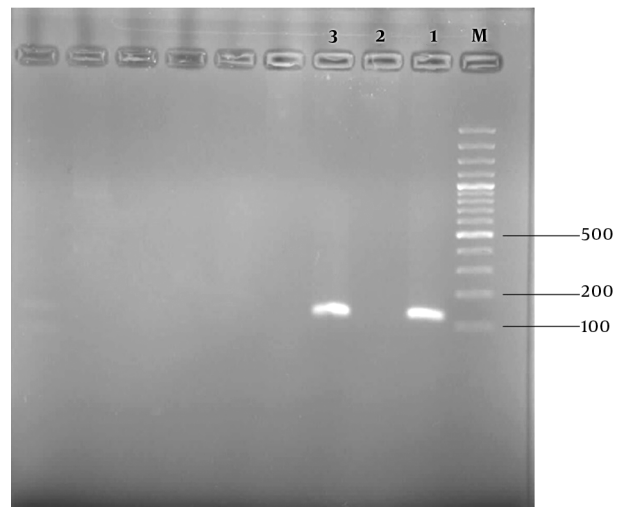
Figure 1. Malaria Parasites in Blood Giemsa Stained Slide in Infected Patient with *Plasmodium vivax*

The nested PCR using the *Plasmodium* 18 subunit ribosomal RNA gene was applied for confirming the *vivax* malaria infection. The DNA of the patient's blood was extracted using a Qiagen Kit. The nested PCR product was approximately 120 bp in agarose gel electrophoresis. Therefore, the existence of *P. vivax* parasites in the blood was confirmed by nested PCR data (Figure 2). Primers and a detailed nested PCR amplifying method have been described previously (11). The patient was treated for 3 days with a regimen of chloroquine as anti-malaria blood schizonticide and primaquine for the resolution of the latent forms in the liver, according to the protocol of the Iranian Ministry of Health and Medical Education. His fever and symptoms were completely resolved at the day-1 follow-up. The thick and thin peripheral blood smears on days 7, 14, and 28 were negative.

3. Discussion

During the initial infection, the patient had been treated with chloroquine as a blood schizonticide and primaquine as a radical cure for the resolution of hypnozoites in the liver, in Chabahar, 1-year prior to the occurrence of the relapse. Primaquine, 8-aminoquinoline, has remained the only drug to resolve the latent phase of *P. vivax* in the liver (2, 9, 12). Primaquine can lead to deadly hemolysis in patients with glucose 6 phosphate dehydrogenase

Figure 2. Gel Photograph Showing Nested PCR Amplified Products from a Relapse *Plasmodium vivax* in a Patient in Iran



The DNA size marker is a 100 bp ladder shown on the right. Lane 1 is Patient *Plasmodium vivax* relapse. Lane 2 and 3 are negative and positive controls respectively.

(G6PD) deficiency (2). According to World Health Organisation (WHO) protocols for preventing severe hemolysis, in countries with high rate of G6PD deficiency individuals, primaquine is administrated at 45 mg per week for 8 weeks instead of the usual regimen of 14 days afterwards by the Iranian Ministry of Health and Medical Education (13). It seems that the surveillance of this regimen encountered some difficulties due to the longitude of the regimen duration, and the patients may not carefully obey the primaquine doses in the 8-week regimen, specifically when they feel better and their clinical manifestations disappear. There are some reports of *P. vivax* relapses in the world with using an inadequate dosage of primaquine (7, 9). It has been noted that there are geographical variations in the emergence and periodicity of *P. vivax* relapses from 3 weeks to 3 years following the initial infection (2, 14). Despite tropical strains of *P. vivax* that are described with short latency, the strains in temperate and subtropical areas have a tendency to illustrate a long latency (2, 7).

In this patient, the relapse of *P. vivax* occurred after about 12 months following the primary malaria infection. Sistan and Baluchistan has a temperate to subtropical climate. In addition, it seems that the relapse happened after a longer time in comparison with the tropical strains, such as Chession. The tendency of *P. vivax* to persistently form liver stage malaria parasites causes more difficulties in the control and elimination of *vivax* malaria than *Plasmodium falciparum* in endemic areas including southeast of Iran.

3.1. Conclusions

The report underlines that relapses should be considered in febrile individuals returning from malaria endemic areas of the country to malaria free areas, as well as, highlights the occurrence of relapse in the patient with history using primaquine for a radical cure of liver hypnozoites. Therefore, more surveillance and monitoring should be applied for correct consuming primaquine. Finally, the emergence of *P. vivax* relapses in the endemic region of Iran could hinder the elimination malaria program.

References

1. Sachs J, Malaney P. The economic and social burden of malaria. *Nature*. 2002;**415**(6872):680–5. doi: [10.1038/415680a](https://doi.org/10.1038/415680a). [PubMed: [11832956](https://pubmed.ncbi.nlm.nih.gov/11832956/)].
2. Battle KE, Karhunen MS, Bhatt S, Gething PW, Howes RE, Golding N, et al. Geographical variation in Plasmodium vivax relapse. *Malar J*. 2014;**13**:144. doi: [10.1186/1475-2875-13-144](https://doi.org/10.1186/1475-2875-13-144). [PubMed: [24731298](https://pubmed.ncbi.nlm.nih.gov/24731298/)].
3. Ehtesham R, Fazaeli A, Raeisi A, Keshavarz H, Heidari A. Detection of mixed-species infections of Plasmodium falciparum and Plasmodium vivax by nested PCR and rapid diagnostic tests in southeastern Iran. *Am J Trop Med Hyg*. 2015;**93**(1):181–5. doi: [10.4269/ajtmh.14-0650](https://doi.org/10.4269/ajtmh.14-0650). [PubMed: [25962771](https://pubmed.ncbi.nlm.nih.gov/25962771/)].
4. White NJ. Determinants of relapse periodicity in Plasmodium vivax malaria. *Malar J*. 2011;**10**:297. doi: [10.1186/1475-2875-10-297](https://doi.org/10.1186/1475-2875-10-297). [PubMed: [21989376](https://pubmed.ncbi.nlm.nih.gov/21989376/)].
5. Andrianaranjaka V, Lin JT, Golden C, Juliano JJ, Randrianarivelosia M. Activation of minority-variant Plasmodium vivax hypnozoites following artesunate + amodiaquine treatment in a 23-year old man with relapsing malaria in Antananarivo, Madagascar. *Malar J*. 2013;**12**:177. doi: [10.1186/1475-2875-12-177](https://doi.org/10.1186/1475-2875-12-177). [PubMed: [23721298](https://pubmed.ncbi.nlm.nih.gov/23721298/)].
6. Durante Mangoni E, Severini C, Menegon M, Romi R, Ruggiero G, Majori G. Case report: An unusual late relapse of Plasmodium vivax malaria. *Am J Trop Med Hyg*. 2003;**68**(2):159–60. [PubMed: [12641405](https://pubmed.ncbi.nlm.nih.gov/12641405/)].
7. McFarland AP, Sanchez JF, Mercado A, Ventocilla JA, Cavalcanti S, Gonzalez S, et al. Repeated Plasmodium vivax malaria relapses in a Peruvian sailor. *Malar J*. 2015;**14**:478. doi: [10.1186/s12936-015-0959-x](https://doi.org/10.1186/s12936-015-0959-x). [PubMed: [26620122](https://pubmed.ncbi.nlm.nih.gov/26620122/)].
8. Miahipour A, Keshavarz H, Heidari A, Raeisi A, Rezaeian M, Rezaei S. Assessment of the efficacy of 8 weeks of primaquine for the prevention of relapse in vivax malaria patients using SSCP-PCR and sequencing in South and South-East Iran, 2008–2011. *Trans R Soc Trop Med Hyg*. 2013;**107**(7):420–6. doi: [10.1093/trstmh/trt035](https://doi.org/10.1093/trstmh/trt035). [PubMed: [23694816](https://pubmed.ncbi.nlm.nih.gov/23694816/)].
9. Bright AT, Alenazi T, Shokoples S, Tarning J, Paganotti GM, White NJ, et al. Genetic analysis of primaquine tolerance in a patient with relapsing vivax malaria. *Emerg Infect Dis*. 2013;**19**(5):802–5. doi: [10.3201/eid1905.121852](https://doi.org/10.3201/eid1905.121852). [PubMed: [23648098](https://pubmed.ncbi.nlm.nih.gov/23648098/)].
10. Edrissian G. Malaria in Iran, past and present situation. *Iran J Parasitol*. 2006;**1**(1):1–4.
11. Snounou G, Viriyakosol S, Zhu XP, Jarra W, Pinheiro L, do Rosario VE, et al. High sensitivity of detection of human malaria parasites by the use of nested polymerase chain reaction. *Mol Biochem Parasitol*. 1993;**61**(2):315–20. [PubMed: [8264734](https://pubmed.ncbi.nlm.nih.gov/8264734/)].
12. Baird JK. Evidence and implications of mortality associated with acute Plasmodium vivax malaria. *Clin Microbiol Rev*. 2013;**26**(1):36–57. doi: [10.1128/CMR.00074-12](https://doi.org/10.1128/CMR.00074-12). [PubMed: [23297258](https://pubmed.ncbi.nlm.nih.gov/23297258/)].
13. World Health Organization. *World health organization, guidelines for the treatment of malaria*. 2 ed. Geneva, Switzerland: WHO; 2010.
14. Ingram RJ, Crenna-Darusallam C, Soebianto S, Noviyanti R, Baird JK. The clinical and public health problem of relapse despite primaquine therapy: case review of repeated relapses of Plasmodium vivax acquired in Papua New Guinea. *Malar J*. 2014;**13**:488. doi: [10.1186/1475-2875-13-488](https://doi.org/10.1186/1475-2875-13-488). [PubMed: [25495607](https://pubmed.ncbi.nlm.nih.gov/25495607/)].