



Hepatoprotective Effect of Aqueous Extract of Persian Gulf Brown Algae *Sargassum swartzii* Against Acetaminophen-Induced Hepatotoxicity in Mice

Mohammad Reza Masoudian Khouzani^{1,2}, Mohammad Reza Shushizadeh^{1,3,*}, Heibatullah Kalantari⁴ and Ebrahim Rajabzadeh Ghotrami^{1,5}

¹Department of Medicinal Chemistry, Faculty of Pharmacy, Ahvaz Jundishapur University of Medical Sciences, Ahvaz, Iran

²Student Research Committee, Ahvaz Jundishapur University of Medical Sciences, Ahvaz, Iran

³Marine Pharmaceutical Science Research Centre, Ahvaz Jundishapur University of Medical Sciences, Iran

⁴Department of Toxicology, Faculty of Pharmacy, Ahvaz Jundishapur University of Medical Sciences, Ahvaz, Iran

⁵Halal Research Center of Islamic Republic of Iran, Tehran, Iran

*Corresponding author: Department of Medicinal Chemistry, Faculty of Pharmacy, Ahvaz Jundishapur University of Medical Sciences, Ahvaz, Iran. Email: m.r.shushizadeh@ajums.ac.ir

Received 2018 May 09; Revised 2018 June 28; Accepted 2018 July 07.

Abstract

Background: The liver plays an important role in detoxification of harmful materials and chemical agents. Many medicines, such as acetaminophen, are potential for oxidative stress and liver toxicity. The brown algae *Sargassum swartzii* possesses many pharmacological benefits. The present study investigated the aqueous extract of Persian Gulf brown algae *Sargassum swartzii* effect on acetaminophen-induced liver injury in mice.

Objectives: It seems that Persian Gulf algae (*Sargassum swartzii*) with its anti-inflammatory and antioxidant properties has preventive effects on acetaminophen-induced liver toxicity, yet no research has been reported in this regard so far. Therefore, this study aimed at evaluating the effect of acetaminophen-induced liver toxicity in mice.

Methods: Brown algae (*Sargassum swartzii*) was collected from the low tide area of Boushehr coasts, Persian Gulf). After transfer to the laboratory, the collected sample was washed with distilled water, air dried, and pulverized to powder. The air dried *S. swartzii* powder was soaked in 95% ethanol to remove pigments and small lipophilic molecules. The residue was then extracted with 10 mL of distilled water at 90°C for three hours, three times. All water extracts were combined, filtrated, and concentrated by water bath at 90°C and stored at 0°C for further analysis. Hepatoprotective activity of the *S. swartzii* extract was confirmed by aspartate aminotransferase (AST), alanine aminotransferase (ALT), and alkaline phosphatase (ALP) levels and histopathologic findings as evidences.

Results: Aqueous extract of *S. swartzii* at dose of 200 mg/kg showed a significant ($P < 0.05$) decrease in the levels of ALT, AST, and ALP, yet at dose of 100 mg/kg, it showed a significant ($P < 0.05$) decrease in the level of ALT.

Conclusions: Administration of the aqueous extract of *S. swartzii* (100 and 200 mg/kg) could improve hepatotoxicity induced by acetaminophen via change in liver marker enzymes and also improved histopathological alterations in liver tissue.

Keywords: Hepatoprotective, Brown Algae, *Sargassum swartzii*, Persian Gulf, Acetaminophen, Alanine Aminotransferase, Aspartate Aminotransferase, Alkaline Phosphatase, Mice

1. Background

Liver is an important organ that is involved in medicine and xenobiotics metabolism, and is a vital station for substance regulation and bioprocessing (1-3). Liver enzymes neutralize numerous xenobiotics, yet induce bio-activated toxicities, which cause other liver damages (4-7). Metabolism of many drugs, such as acetaminophen, at therapeutic doses is not harmful yet at higher doses oxidative stress may result (8) and subsequently lead to increment of free radicals and reactive

oxygen species due to saturation of metabolic pathways. Free radicals are detoxified due to binding to intracellular glutathione and in case of glutathione reduction (3, 9, 10), they will bind to cellular macromolecules, which consequently cause cellular death and liver damage (1, 2). Chronic liver diseases are characterized by progressive evolution from steatosis to chronic hepatitis, fibrosis, cirrhosis, and hepatocellular carcinoma (2, 11, 12). By changing human lifestyle, liver diseases have become one of the most common and fatal diseases all over the world,

particularly in developing countries. Therefore, numerous efforts have been made to explore new drugs of herbal and marine plant origin in order to reduce drug-induced liver injuries (3).

People use algae for centuries because of their high nutritional value. They contain bioactive organic compounds, such as terpenoids and carotenoids. Also, they contain natural antioxidant, sulfated polysaccharides, lipids, proteins, vitamins, and minerals, which are exclusively found in marine plants (2, 13-16)

Sargassum spp. have been shown to have extremely high cleaning property for free radicals (17-21). Herbal polysaccharides are known as a significant group of bioactive natural products (22). Therefore, herbal and marine plants have attracted the attention of pharmaceutical and medical industries due to their demonstrated rich sources of structurally miscellaneous bioactive compounds. Sulfated polysaccharides isolated from seaweeds were investigated to possess immune stimulation (8), anti-tumoral (9, 12, 23), antiviral (10), immunomodulatory (12), and anti-inflammatory properties (11), hepatoprotective (13, 24, 25) and nephroprotective (26) effects of some marine algae have also been reported.

2. Objectives

The aim of this research was to investigate the hampering effects of *S. swartzii* aqueous extract on acetaminophen-induced hepatotoxicity in mice by virtue of its antioxidant properties.

3. Methods

3.1. Material and Sample Collection

All chemicals at analytical grades were obtained from the Merck company of Germany. Brown algae (*Sargassum swartzii*) were collected from low tide areas of Boushehr province (Persian Gulf) coasts, during July 2016.

3.2. Preparation of Aqueous Extract of *Sargassum swartzii*

After transfer to the laboratory, the collected sample was washed with distilled water, air dried, and pulverized in powder. To remove pigments and fat molecules of *S. swartzii* powder, 100 g of powder was immersed in ethanol (95%). The residue was then extracted from 1:10 volume of distilled water at 90°C for three hours, three times. All water extracts were combined, filtrated, and concentrated in a water bath at 90°C. The residue was stored at 0°C for further analysis (12, 16).

3.3. Animals

Overall, 30 male mice (18 to 27 g) were purchased from the animal house of Ahvaz Jundishapur University of Medical Sciences (Ahvaz, Iran).

They were kept in standard single cages under standardized conditions (22 ± 4°C). The animals were maintained on standard chow diet and water *ad libitum*. Furthermore, the Institutional Ethics Committee of the Medicine School of Ahvaz Jundishapur University of Medical Sciences guideline approved all procedures adopted in this study (Ethical number: IR.AJUMS.REC.1396.297).

3.4. Experimental Design

Healthy male mice, weighing 18 to 27g were housed in cages. The animals were kept under standard conditions, seven days after adaptation, and mice were randomly divided to five groups; each of which had six mice. Experimental groups were treated by oral gavage for one week with different doses of aqueous extract of *S. swartzii* (100 and 200 mg/kg) one hour after receiving acetaminophen (350 mg/kg). Normal saline (5 mL/kg) was orally administered to the negative control group. Also, one hour after receiving acetaminophen (350 mg/kg), the positive control group received normal saline (5 mL/kg), respectively. Finally, the last group received aqueous extract of *S. swartzii* (100 mg/kg) without acetaminophen administration.

Twenty-four hours after the last administration, animals were anesthetized by Ketamine-Xylazine and serum samples were obtained by heart puncture. Blood collection and centrifugation at 3000 rpm for 15 minutes was performed. Obtained clear supernatant was stored at -70°C prior to analysis for subsequent measurement of ALT, AST, and ALP. Liver was isolated and quickly washed with normal saline, and was then fixed in 10% formalin for histological studies (27-30).

3.5. Serum Biochemical Parameters

The most commonly used markers of liver injury are aspartate aminotransferase (AST), alanine aminotransferase (ALT), and alkaline phosphatase (ALP). Colorimetric determination of ALT and AST were estimated by measuring the amount of pyruvate or oxaloacetate produced by the formation of 2, 4-dinitrophenylhydrazine, according to the method of Reitman and Franker (31); also, colorimetric determination of ALP was estimated by measuring the amount of p-nitrophenyl-phosphate produced by the formation of phosphate substrate when dephosphorylated by ALP (32).

3.6. Histopathology

All mice livers were immediately fixed at 10% formalin for 24 hours, and afterwards embedded in paraffin. Then, they were dehydrated through soaking in alcohol and xylol, respectively. Finally, after preparation of 5-micron tissue sections using rotary microtome, the Haematoxylin and Eosin (H&E) staining technique was performed. The histopathological changes were examined using the light microscope (33).

3.7. Statistical Analysis

Results were presented as mean \pm SD values. The statistical significance of differences between groups was determined by one-way analysis of variance (ANOVA), followed by Tukey's post hoc test for multiple comparisons. A probability value of $P < 0.05$ was assumed to indicate statistical significance (34).

4. Results

The effects of aqueous extract of *S. swartzii* on liver marker enzymes are listed in Table 1. These data indicate that the group that received normal saline (NS) showed a normal range of ALT, AST, and ALP levels, whilst the treated group that received acetaminophen showed increased levels of ALT, AST, and ALP, which means acetaminophen (APAP) causes hepatotoxicity at higher dosages.

Table 1. Effect of Aqueous Extract of *S. swartzii* on Liver Marker Enzymes^a

Groups	ALT (IU/L)	AST (IU/L)	ALP (IU/L)
NS (A)	49.33 \pm 4.71	156.16 \pm 9.74	354.50 \pm 7.66
APAP+NS (B)	112.16 \pm 8.42	335.83 \pm 8.42	698.16 \pm 8.72
APAP+S. <i>swartzii</i> 100 mg/kg (f1)	65.16 \pm 7.05	184.83 \pm 6.56	428.66 \pm 9.13
APAP+S. <i>swartzii</i> 200 mg/kg (f2)	55.33 \pm 4.76	159.33 \pm 6.99	363.33 \pm 4.92
<i>S. swartzii</i> 100 mg/kg + NS (f)	51.16 \pm 5.03	157.83 \pm 8.28	361.16 \pm 9.45

^a Values are expressed as mean \pm SD.

The increment of liver marker enzymes are considered as indicators for enzyme release from destroyed cells. On the other hand, the extract-treated group showed interesting results.

4.1. Effect of Aqueous Extract of *S. swartzii* on the Serum Levels of ALT

Prescription of acetaminophen (APAP) significantly ($P < 0.05$) increased the serum levels of ALT when compared to the other groups (*). Oral treatment with *S. swartzii* (f1, f2) caused a significant decrease in the serum levels of ALT

($P < 0.05$) in a dose-dependent manner. There was a difference between hepatoprotective activity of f1 and f2. Also, no significant ($P < 0.05$) difference was observed between NS, f, and f2 groups (Figure 1 and Table 1).

4.2. Effect of Aqueous Extract of *S. swartzii* on the Serum Levels of AST

The f1 and acetaminophen (APAP) groups significantly ($P < 0.05$) increased the serum levels of AST when compared to the other groups (*). There was no significant ($P < 0.05$) difference between NS, f, and f2 groups (Figure 2 and Table 1).

4.3. Effect of Aqueous Extract of *S. swartzii* on the Serum Levels of ALP

The f1 and Acetaminophen (APAP) groups significantly ($P < 0.05$) increased the serum levels of ASP when compared to the other group (*). There was no significant ($P < 0.05$) difference between NS, f, and f2 groups (Figure 3 and Table 1).

4.4. Histopathology

In APAP-treated group (Figure 4B), severe changes were observed in liver morphology, including hepatocytes necrosis, accumulation of inflammatory cells, loss of cellular boundaries, dilated sinusoids, and change in liver cells fat and cell swelling (\rightarrow) compared with the control group (Figure 4A). Mice that were treated with aqueous extract of *S. swartzii* (f1 and f2) showed less degeneration of hepatocytes necrosis, reduction of inflammatory cells accumulation, cell swelling in hepatocytes, cellular boundaries, and dilated sinusoids, and these changes in the f2 group showed more complete improvement compared to the f1 group. The group that only received aqueous extract of *S. swartzii* 100 mg/kg (f) showed a normal structure (groups f, f1, and f2; Figure 4).

5. Discussion

The findings of this study indicate that APAP can induce hepatotoxicity through increasing ALT, AST, and ALP serum levels, which can cause histopathological alterations in liver tissue. Administration of the aqueous extract of *S. swartzii* (100 and 200 mg/kg) could improve hepatotoxicity induced by APAP via change in liver marker enzymes and also improved histopathological alterations in liver tissue when compared with the APAP group. Thus, it can be suggested that the aqueous extract of *S. swartzii* (100 and 200 mg/kg) may prevent hepatotoxicity induced by APAP, yet the aqueous extract of *S. swartzii* (200 mg/kg) significantly ($P < 0.05$) prevents hepatotoxicity induced by APAP.

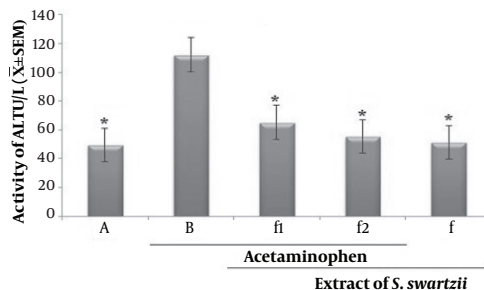


Figure 1. Effect of aqueous extract of *S. swartzii* on the serum levels of ALT

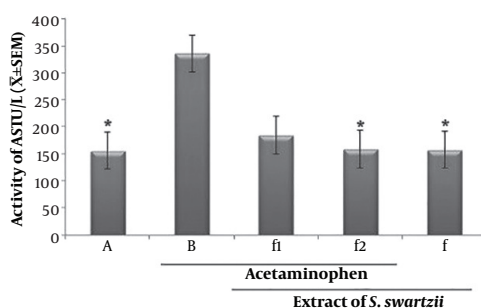


Figure 2. Effect of aqueous extract of *S. swartzii* on the serum levels of AST

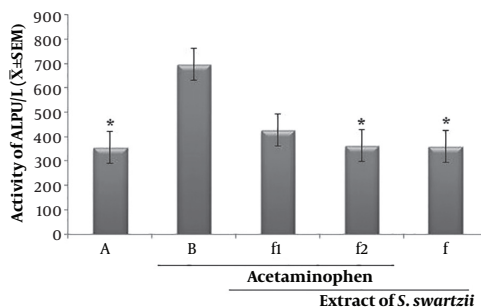


Figure 3. Effect of aqueous extract of *S. swartzii* on the serum levels of ALP. A, group that only received normal saline (NS); B, group that received acetaminophen 350 mg/kg + normal saline; f1, treatment group which received acetaminophen (350 mg/kg) one hour before aqueous extract of *S. swartzii* (100 mg/kg); f2, treatment group which received acetaminophen (350 mg/kg) one hour before aqueous extract of *S. swartzii* (200 mg/kg); f, group that only received aqueous extract of *S. swartzii* (100 mg/kg)

In past studies, hepatoprotective effects of different extracts of *Sargassum binderi*, *Sargassum tenerrimum*, *Sargassum variegatum*, and *Sargassum polycystum* has been investigated (25, 35). According to the obtained results of the present study, aqueous extract of *Sargassum swartzii* (200 mg/kg) had a more preventive effect on increment of liver enzymes (ALT, AST, and ALP) in comparison to other extracts of *Sargassum binderi*, *Sargassum tenerrimum*, *Sargassum variegatum*, and *Sargassum polycystum*, which results in better protective effects of *Sargassum swartzii* (200

mg/kg) on the liver. This is due to the content of their flavonoids, carotenoids, polysaccharides, and phenolic, which can be used as a source of natural non-toxic antioxidants in food, cosmetics, and pharmaceutical industries (2, 20, 36-40).

In the present study, the protective role of the aqueous extract of *S. swartzii* at different levels was evaluated and confirmed the scientific evidence for pharmacological use of aqueous extract of *S. swartzii* in liver injuries.

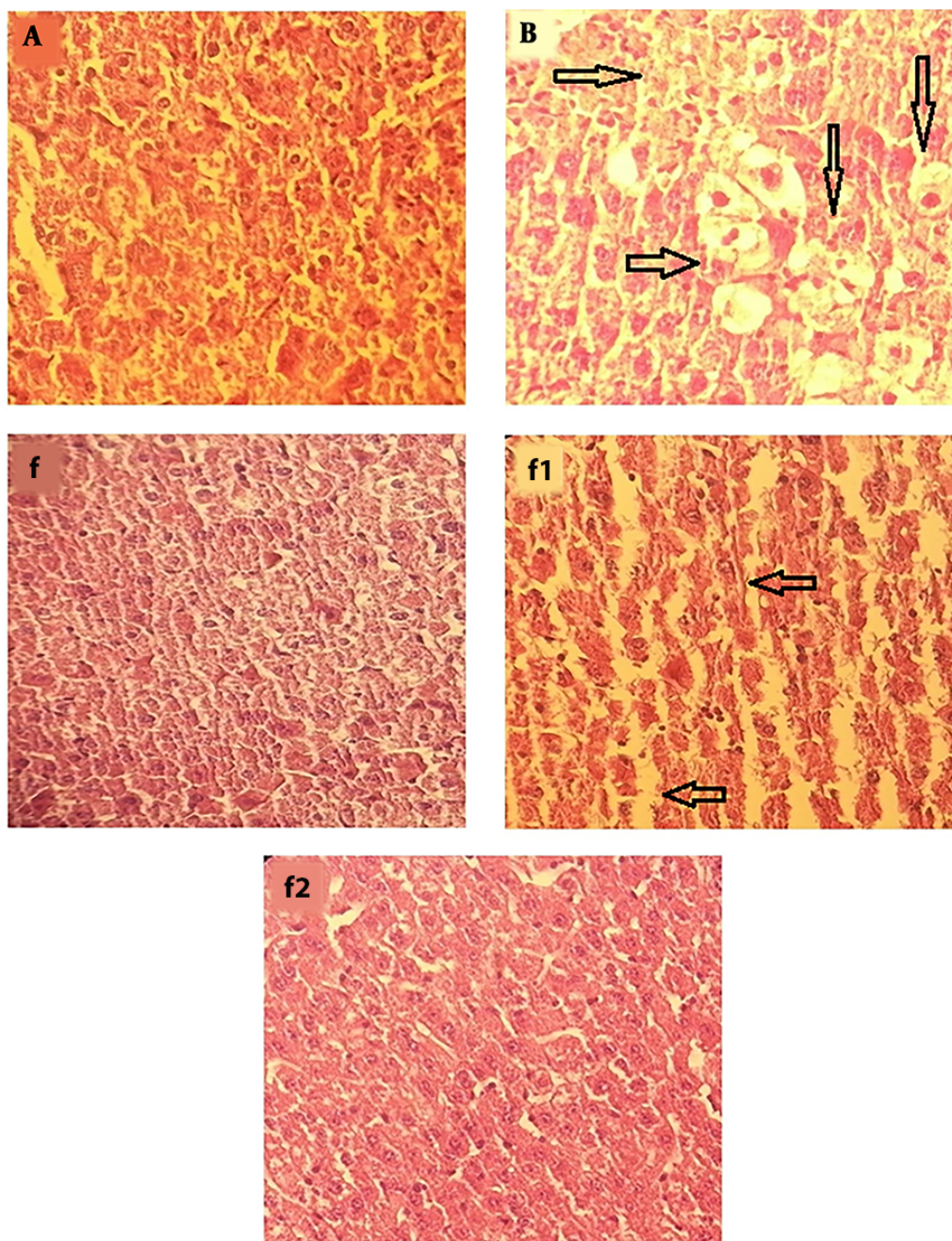


Figure 4. Photomicrograph showing histopathological section of liver tissue from each group (original magnification: $\times 100$). A, group that received normal saline (NS); normal morphology of histological section of mice liver; B, group that received acetaminophen 350 mg/kg; f, group that only received aqueous extract of *S. swartzii* (100 mg/kg); f1, treatment group which received acetaminophen (350 mg/kg) one hour before aqueous extract of *S. swartzii* (100 mg/kg); f2, treatment group which received acetaminophen (350 mg/kg) one hour before aqueous extract of *S. swartzii* (200 mg/kg).

Footnotes

Conflict of Interests: It is not declared by the authors.

Ethical Approval: The Institutional Ethics Committee of

the Medicine School, Ahvaz Jundishapur University of Medical Sciences approved all procedures adopted in this study (ethical number: IR.AJUMS.REC.1396.297).

Funding/Support: It is not declared by the authors.

References

- Rajasulochana P, Dhamotharan R, Krishnamoorthy P, Murugesan S. Antibacterial activity of the extracts of marine red and brown algae. *J Am Sci.* 2009;**5**(3):20–5.
- Mutawie HH, ElNaggar SMM. The protective effect of *Sargassum crassifolia* against Nimbecidine-induced hepatotoxicity and nephrotoxicity in Wistar rats. *Life Sci J.* 2013;**10**(4).
- Madkour FF, Khalil WF, Dessouki AA. Protective effect of ethanol extract of *Sargassum dentifolium* (Phaeophyceae) in carbon tetrachloride-induced hepatitis in rats. *Int J Pharm Pharm Sci.* 2012;**4**(3):637–41.
- Lahaye M, Kaeffer B. Seaweed dietary fibres: structure, physicochemical and biological properties relevant to intestinal physiology. *Sci Des Aliments.* 1997;**17**(6):563–84.
- Holt M, Ju C. Drug-induced liver injury. In: Uetrecht J, editor. *Adverse Drug Reactions.* 196. Berlin, Heidelberg: Springer; 2010. p. 3–27. doi: [10.1007/978-3-642-00663-0_1](https://doi.org/10.1007/978-3-642-00663-0_1).
- Rates SM. Plants as source of drugs. *Toxicol.* 2001;**39**(5):603–13. doi: [10.1016/S0041-0101\(00\)00154-9](https://doi.org/10.1016/S0041-0101(00)00154-9). [PubMed: [11072038](https://pubmed.ncbi.nlm.nih.gov/11072038/)].
- Fontana RJ, Seeff LB, Andrade RJ, Bjornsson E, Day CP, Serrano J, et al. Standardization of nomenclature and causality assessment in drug-induced liver injury: Summary of a clinical research workshop. *Hepatology.* 2010;**52**(2):730–42. doi: [10.1002/hep.23696](https://doi.org/10.1002/hep.23696). [PubMed: [20564754](https://pubmed.ncbi.nlm.nih.gov/20564754/)]. [PubMed Central: [PMC3616501](https://pubmed.ncbi.nlm.nih.gov/PMC3616501/)].
- Yeh ST, Lee CS, Chen JC. Administration of hot-water extract of brown seaweed *Sargassum duplicatum* via immersion and injection enhances the immune resistance of white shrimp *Litopenaeus vannamei*. *Fish Shellfish Immunol.* 2006;**20**(3):332–45. doi: [10.1016/j.fsi.2005.05.008](https://doi.org/10.1016/j.fsi.2005.05.008). [PubMed: [16005643](https://pubmed.ncbi.nlm.nih.gov/16005643/)].
- Dias PF, Siqueira JM Jr, Vendruscolo LF, de Jesus Neiva T, Gagliardi AR, Maraschin M, et al. Antiangiogenic and antitumoral properties of a polysaccharide isolated from the seaweed *Sargassum stenophyllum*. *Cancer Chemother Pharmacol.* 2005;**56**(4):436–46. doi: [10.1007/s00280-004-0995-7](https://doi.org/10.1007/s00280-004-0995-7). [PubMed: [15902462](https://pubmed.ncbi.nlm.nih.gov/15902462/)].
- Paskaleva EE, Lin X, Duus K, McSharry JJ, Veille JC, Thornber C, et al. *Sargassum fusiforme* fraction is a potent and specific inhibitor of HIV-1 fusion and reverse transcriptase. *Virology.* 2008;**5**:8. doi: [10.1186/1743-422X-5-8](https://doi.org/10.1186/1743-422X-5-8). [PubMed: [18197976](https://pubmed.ncbi.nlm.nih.gov/18197976/)]. [PubMed Central: [PMC2267448](https://pubmed.ncbi.nlm.nih.gov/PMC2267448/)].
- Kang JY, Khan MN, Park NH, Cho JY, Lee MC, Fujii H, et al. Antipyretic, analgesic, and anti-inflammatory activities of the seaweed *Sargassum fulvellum* and *Sargassum thunbergii* in mice. *J Ethnopharmacol.* 2008;**116**(1):187–90. doi: [10.1016/j.jep.2007.10.032](https://doi.org/10.1016/j.jep.2007.10.032). [PubMed: [18079077](https://pubmed.ncbi.nlm.nih.gov/18079077/)].
- Chen X, Nie W, Yu G, Li Y, Hu Y, Lu J, et al. Antitumor and immunomodulatory activity of polysaccharides from *Sargassum fusiforme*. *Food Chem Toxicol.* 2012;**50**(3-4):695–700. doi: [10.1016/j.fct.2011.11.015](https://doi.org/10.1016/j.fct.2011.11.015). [PubMed: [22120506](https://pubmed.ncbi.nlm.nih.gov/22120506/)].
- Meena B, Ezhilan RA, Rajesh R, Hussain AS, Ganesan B, An R. Antihypertensive potential of *Sargassum polycystum* (Phaeophyceae) on antioxidant defense status in D-galactosamine-induced hepatitis in rats. *Afr J Biochem Res.* 2008;**2**(2):51–5.
- Shao P, Chen X, Sun P. Chemical characterization, antioxidant and antitumor activity of sulfated polysaccharide from *Sargassum horneri*. *Carbohydr Polym.* 2014;**105**:260–9. doi: [10.1016/j.carbpol.2014.01.073](https://doi.org/10.1016/j.carbpol.2014.01.073). [PubMed: [24708979](https://pubmed.ncbi.nlm.nih.gov/24708979/)].
- Vijayabaskar P, Vaseela N, Thirumaran G. Potential antibacterial and antioxidant properties of a sulfated polysaccharide from the brown marine algae *Sargassum swartzii*. *Chin J Nat Med.* 2012;**10**(6):421–8. doi: [10.1016/S1875-5364\(12\)60082-X](https://doi.org/10.1016/S1875-5364(12)60082-X).
- Ye H, Wang K, Zhou C, Liu J, Zeng X. Purification, antitumor and antioxidant activities in vitro of polysaccharides from the brown seaweed *Sargassum pallidum*. *Food Chem.* 2008;**111**(2):428–32. doi: [10.1016/j.foodchem.2008.04.012](https://doi.org/10.1016/j.foodchem.2008.04.012). [PubMed: [26047446](https://pubmed.ncbi.nlm.nih.gov/26047446/)].
- Fujimoto K, Kaneda T. Separation of antioxygenic (antioxidant) compounds from marine algae. In: Bird CJ, Ragan MA, editors. *Eleventh International Seaweed Symposium.* 22. Springer; 1984. p. 111–3. doi: [10.1007/978-94-009-6560-7_17](https://doi.org/10.1007/978-94-009-6560-7_17).
- Xiaojun Y, Xiancui L, Chengxu Z, Xiao F. Prevention of fish oil rancidity by phlorotannins from *Sargassum kjellmanianum*. *J Appl Phycol.* 1996;**8**(3):201–3. doi: [10.1007/BF02184972](https://doi.org/10.1007/BF02184972).
- Ruperez P, Ahrazem O, Leal JA. Potential antioxidant capacity of sulfated polysaccharides from the edible marine brown seaweed *Fucus vesiculosus*. *J Agric Food Chem.* 2002;**50**(4):840–5. doi: [10.1021/jf010908o](https://doi.org/10.1021/jf010908o). [PubMed: [11829654](https://pubmed.ncbi.nlm.nih.gov/11829654/)].
- Park PJ, Shahidi F, Jeon YJ. Antioxidant activities of enzymatic extracts from an edible seaweed *Sargassum horneri* using ESR spectrometry. *J Food Lipids.* 2004;**11**(1):15–27. doi: [10.1111/j.1745-4522.2004.tb00257.x](https://doi.org/10.1111/j.1745-4522.2004.tb00257.x).
- Anggadiredja J, Andyani R. Antioxidant activity of *Sargassum polycystum* (Phaeophyta) and *Laurencia obtusa* (Rhodophyta) from Seribu islands. *J Appl Phycol.* 1997;**9**(5):477. doi: [10.1023/A:100807562](https://doi.org/10.1023/A:100807562).
- Hu M, Zhang H, Feng B, Liu K, Guo S. Extraction of polysaccharides from *Fomes officinalis* Ames and their antitumor activity. *Exp Ther Med.* 2013;**6**(2):451–4. doi: [10.3892/etm.2013.1163](https://doi.org/10.3892/etm.2013.1163). [PubMed: [24137206](https://pubmed.ncbi.nlm.nih.gov/24137206/)]. [PubMed Central: [PMC3786837](https://pubmed.ncbi.nlm.nih.gov/PMC3786837/)].
- Patra S, Muthuraman MS, Prabhu AR, Priyadarshini RR, Parthiban S. Evaluation of antitumor and antioxidant activity of *Sargassum tenerimum* against Ehrlich ascites carcinoma in mice. *Asian Pac J Cancer Prev.* 2015;**16**(3):915–21. doi: [10.7314/APJCP.2015.16.3.915](https://doi.org/10.7314/APJCP.2015.16.3.915). [PubMed: [25735382](https://pubmed.ncbi.nlm.nih.gov/25735382/)].
- Sathivel A, Raghavendran HB, Devaki T. Hepatoprotective nature of seaweeds (*Ulva lactuca*/*Gracilaria edulis*) against liver injury induced by D-Galactosamine/endotoxin in rats. *Seaweed Res Util.* 2003;**25**(1-2):109–11.
- Hira K, Sultana V, Ara J, Ehteshamul-Haque S, Athar M. Hepatoprotective potential of three sargassum species from Karachi coast against carbon tetrachloride and acetaminophen intoxication. *J Coastal Life Med.* 2016;**4**(1):10–3. doi: [10.12980/jclm.4.2016j5-204](https://doi.org/10.12980/jclm.4.2016j5-204).
- Ramarajan L, Somasundaram ST, Subramanian S, Pandian V. Nephroprotective effects of *Colpomenia sinuosa* (Derbes & Solier) against carbon tetrachloride induced kidney injury in Wistar rats. *Asia Pacific J Tropic Dis.* 2012;**2**(1):S435–41. doi: [10.1016/S2222-1808\(12\)60199-6](https://doi.org/10.1016/S2222-1808(12)60199-6).
- Mossanen JC, Tacke F. Acetaminophen-induced acute liver injury in mice. *Laboratory Anim.* 2015;**49**(1_suppl):30–6. doi: [10.1177/0023677215570992](https://doi.org/10.1177/0023677215570992).
- Nithianantham K, Shyamala M, Chen Y, Latha LY, Jothy SL, Sasidharan S. Hepatoprotective potential of *Clitoria ternatea* leaf extract against paracetamol induced damage in mice. *Molecules.* 2011;**16**(12):10134–45. doi: [10.3390/molecules161210134](https://doi.org/10.3390/molecules161210134). [PubMed: [22146374](https://pubmed.ncbi.nlm.nih.gov/22146374/)]. [PubMed Central: [PMC6264671](https://pubmed.ncbi.nlm.nih.gov/PMC6264671/)].
- Sener G, Sehirlir AO, Ayanoglu-Dulger G. Protective effects of melatonin, vitamin E and N-acetylcysteine against acetaminophen toxicity in mice: A comparative study. *J Pineal Res.* 2003;**35**(1):61–8. doi: [10.1034/j.1600-079X.2003.00050.x](https://doi.org/10.1034/j.1600-079X.2003.00050.x). [PubMed: [12823615](https://pubmed.ncbi.nlm.nih.gov/12823615/)].
- Yapar K, Kart A, Karapehlivan M, Atakisi O, Tunca R, Erginsoy S, et al. Hepatoprotective effect of L-carnitine against acute acetaminophen toxicity in mice. *Exp Toxicol Pathol.* 2007;**59**(2):121–8. doi: [10.1016/j.etp.2007.02.009](https://doi.org/10.1016/j.etp.2007.02.009). [PubMed: [17716880](https://pubmed.ncbi.nlm.nih.gov/17716880/)].
- Crowley LV. The Reitman-Frankel colorimetric transaminase procedure in suspected myocardial infarction. *Clin Chem.* 1967;**13**(6):482–7. [PubMed: [6027778](https://pubmed.ncbi.nlm.nih.gov/6027778/)].
- Bowers GN, McComb RB. Measurement of total alkaline phosphatase activity in human serum. *Clin Chem.* 1975;**21**(13):1988–95.
- Fischer AH, Jacobson KA, Rose J, Zeller R. Hematoxylin and eosin staining of tissue and cell sections. *CSH Protoc.* 2008;**2008**:pdb prot4986. doi: [10.1101/pdb.prot4986](https://doi.org/10.1101/pdb.prot4986). [PubMed: [21356829](https://pubmed.ncbi.nlm.nih.gov/21356829/)].
- Armitage P, Berry G, Matthews JNS. *Statistical methods in medical research.* John Wiley & Sons; 2008.
- Raghavendran HRB, Sathivel A, Devaki T. Hepatoprotective nature of seaweed alcoholic extract on acetaminophen induced hepatic oxidative stress. *J Health Sci.* 2004;**50**(1):42–6. doi: [10.1248/jhs.50.42](https://doi.org/10.1248/jhs.50.42).
- Yang X, Kang MC, Lee KW, Kang SM, Lee WW, Jeon YJ. Antioxidant activity and cell protective effect of loliolide isolated from *Sargassum ring-*

- goldianum subsp. coreanum. *Algae*. 2011;**26**(2):201-8. doi: [10.4490/algaee.2011.26.2.201](https://doi.org/10.4490/algaee.2011.26.2.201).
37. Daisy A, Indra V, Geetha S, Seetharaman S, Selvamuthu B. Phytochemical profiling of seaweeds collected from Pulicat lake, Coramandal coast of south India. *World J Pharm Pharm Sci*. 2016;**5**(7):1292-7.
38. Bhaigyabati T, Kirithika T, Shiny K, Usha K. Phytochemical screening and antioxidant activity of various extracts of *Sargassum muticum*. *Int J Pharm Res Dev*. 2011;**3**(10):25-30.
39. Bambang BS, Kumalaningsih S, Susinggih W, Hardoko . Polyphenol content and antioxidant activities of crude extract from brown algae by various solvents. *J Life Sci Biomed*. 2013;**3**(6):439-43.
40. Jin W, Zhang W, Wang J, Yao J, Xie E, Liu D, et al. A study of neuroprotective and antioxidant activities of heteropolysaccharides from six *Sargassum* species. *Int J Biol Macromol*. 2014;**67**:336-42. doi: [10.1016/j.ijbiomac.2014.03.031](https://doi.org/10.1016/j.ijbiomac.2014.03.031). [PubMed: [24680812](https://pubmed.ncbi.nlm.nih.gov/24680812/)].