


Case Report

Unusual Metastatic Malignant Gastric Glomus Tumor (Glomangiosarcoma): A Case Report and Literature Review



Abdolhassan Talaiezhadeh¹ , Mohammad Nejaty^{1*}, Nematollah Jazayeri²

1. Department of Surgical Oncology, Faculty of Medicine, Cancer Research Center, Ahvaz Jundishapur University of Medical Sciences, Ahvaz, Iran.
2. Department of Pathology, Faculty of Medicine, Ahvaz Jundishapur University of Medical Sciences, Ahvaz, Iran.



Citation Talaiezhadeh A, Nejaty M, Jazayeri N. Unusual Metastatic Malignant Gastric Glomus Tumor (Glomangiosarcoma): A Case Report and Literature Review. *Judishapur Journal of Oncology*. 2016; 2(2):58-62. <http://dx.doi.org/10.32598/jjo.20.2.2>

 <http://dx.doi.org/10.32598/jjo.20.2.2>

**Article info:**

Received: 23 May 2016

Accepted: 12 Sep 2016

Available Online: 01 Dec 2016

ABSTRACT

Glomangiosarcoma is a pericytic neoplasm derived from glomus cells. It is a rare tumor, especially within the gastrointestinal tract. We report a female patient around 67 years old with a history of gastrectomy surgery due to a submucosal glomus tumor. After 4 years of surveillance, the patient came with thigh and hepatic metastases with the same histology (metastatic glomangiosarcoma).

Keywords: Glomangiosarcoma, Glomus tumor, Gastric tumor, Liver, Thigh

* Corresponding Author:

Mohammad Nejaty, MD.

Address: Cancer Research Center, Ahvaz Jundishapur University of Medical Sciences, Ahvaz, Iran.

Tel: +98 (916) 3077469

E-mail: nejatymohammad.surgery@gmail.com

1. Background

Glomangioma (glomus tumor) is an uncommon form of perivascular neoplasm that is trivial from a clinical standpoint. It originates from the glomus bodies, arteriovenous anastomoses concerned with thermoregulation, most frequent in the dermis and hypodermis of the fingers, particularly subungually [1]. Generally, glomus tumors appear as a single, small (usually <1.0 cm in diameter), condensed, red-blue, a painful nodule that affects teenagers [2]. Glomangiosarcoma (malignant glomus tumor) is an uncommon mesenchymal sarcoma responsible for less than 1% of glomus neoplasms [3]. They are differentiated from their benign counterpart by their spatial dimension of greater than 2.0 cm, visceral or deep site, infiltrative growth configuration, and extra histologic features such as nuclear pleomorphism and multiplied mitotic activity (>4 per 50 high-power fields). Notwithstanding their malignant histological criteria, it has been stated that glomangiosarcoma rarely metastasize [4].

2. Case Presentation

A 67-year-old female was presented with complaints of vague upper abdominal pain that worsened when eating meals. The complaints lasted approximately 8 weeks with 2 kg weight loss over 3 months. She had no past medical or surgical history. On physical examination, slight and vague abdominal tenderness was noted. Her laboratory work-up revealed anemia (Hb: 8 mg/dL). She was subsequently prompted for further evaluation with gastroduodenal endoscopy.

Endoscopy demonstrated a polypoidal ulcerated mass 3×3 cm in the greater curvature of the stomach near to incisura, and a biopsy was taken. Pathology and Immunohistochemistry (IHC) reported vascular or pericytic proliferation. Histologically, dilated and angulated blood vessels were surrounded by solid sheets of glomus cells. The neoplastic cells were monomorphic and showed eosinophilic cytoplasm, central oval nuclei, and brisk mitotic activity. IHC revealed strong positivity for smooth muscle actin within tumor cells. The follow-up computed tomography scan with intravenous contrast confirmed the presence of a solid mass in the liver. Sonography revealed a hyperechoic lesion in segment 6 of the liver, so a biopsy was taken. The final pathology was negative for metastasis. The patient was taken to the operating room for a planned laparotomy and resection. The mass appeared to be arising from the greater curve of the gastric body. A subtotal gastrectomy and loop gastrojejunostomy was performed.

Pathology results reported a 3×3×4 cm tumor extending to subserosa, with no lymph node involvement; IHC findings favor intermediate grade neuroendocrine tumor over other possibilities (SYN+, CK-, CD45-, h-caldesmon +, Ki-67 index 4%). After four years of follow-up, the patient came to the clinic with a large mass in the left thigh in the popliteal region. Magnetic resonance imaging with gadolinium contrast revealed a lobulated heterogeneous intensity 72×65×58 mm mass in the posterolateral aspect of the left distal thigh, with no relation to femoral cortex or vessels (Figure 1). Ultrasound-guided core needle biopsy showed neoplastic tumor suggestive of soft tissue sarcoma. However, final IHC findings were compatible with glomus tumor, which could be metastasis from previous gastric glomus tumor with the same

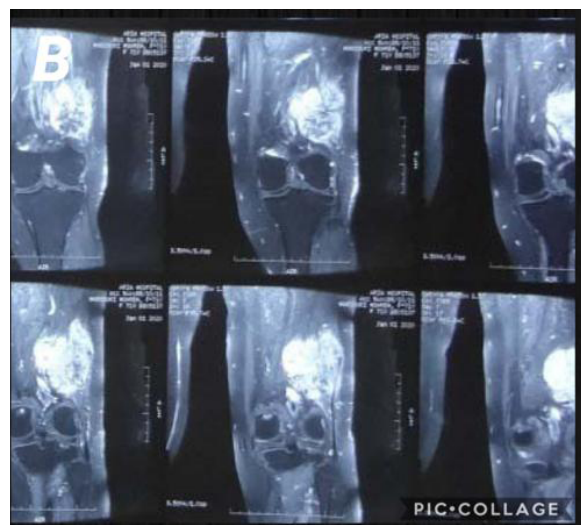
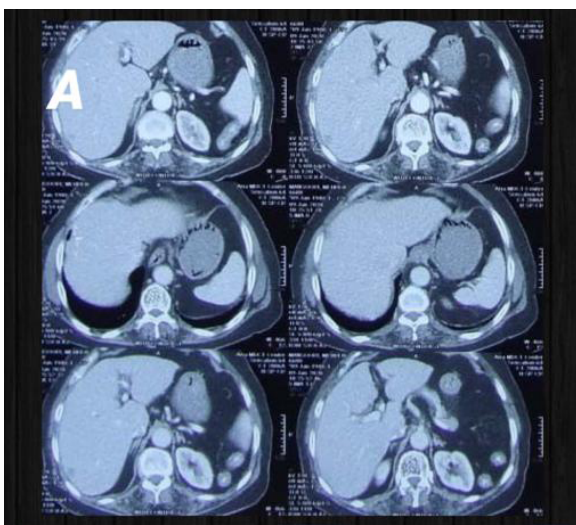


Figure 1. Liver and thigh CT scan

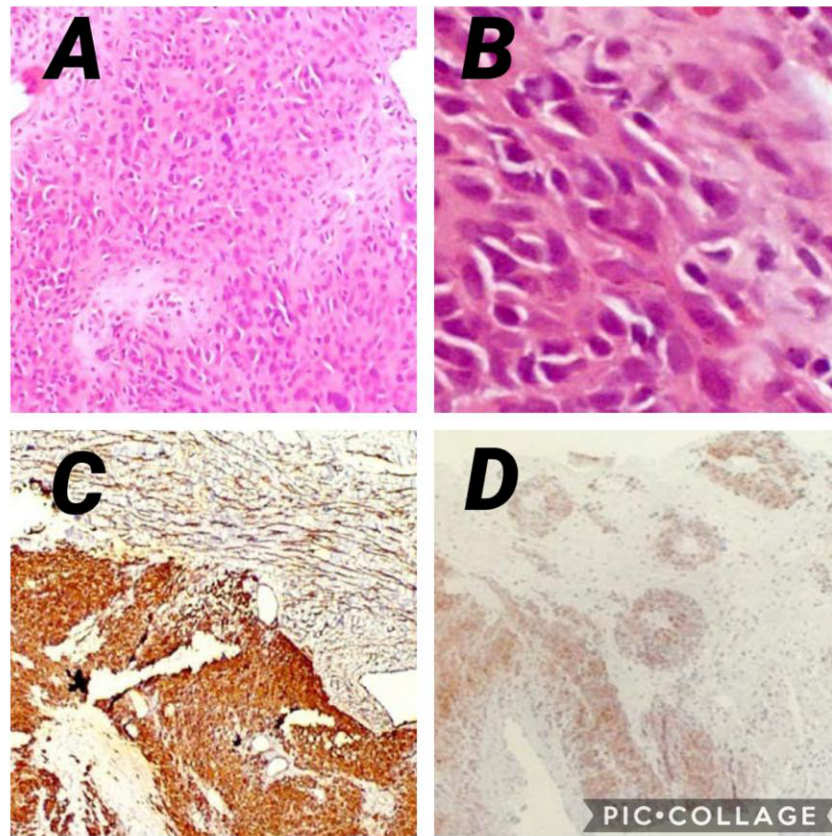


Figure 2. A: Thigh mass metastatic glomus tumor (×200, H&E staining); B: Thigh mass (×600, H&E staining); C: Thigh mass (SMA staining); D: Thigh mass (synaptophysin staining)

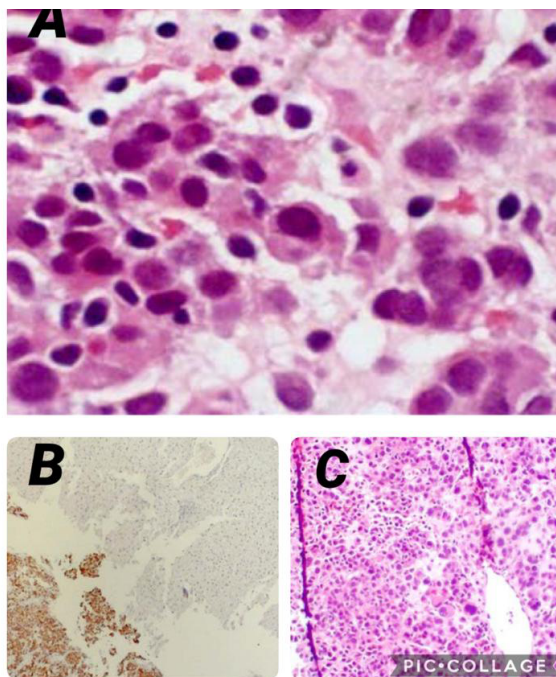


Figure 3. A: Liver metastases (H&E staining, high power field); B: Liver metastases (synaptophysin staining); C: Liver metastatic tumor showing similar morphology to the primary gastric mass (low power field)

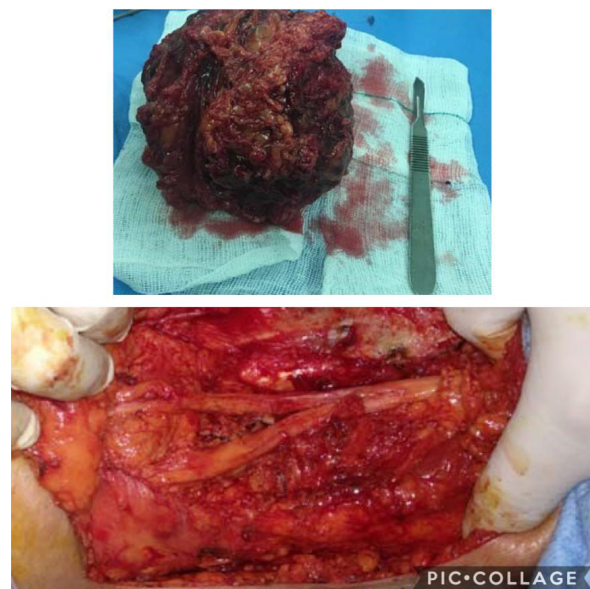

Figure 4. Operation field and metastatic mass

histologic and immunohistochemistry staining features (Vimentin +, SMA +, Synaptophysin +) (Figure 2).

The patient underwent whole-body CT with contrast for metastasis work-up, which revealed a small ovoid hypodense solid mass 16×10 mm in the lateral subcapsular region of segment 6 of the liver (Figure 1).

Biopsy of liver mass under sonography guide was taken. Pathology and IHC findings favor myofibroblastic tumors (Vimentin+, SMA+) (Figure 3).

First, the large popliteal mass was resected with free margin, saving neurovascular bundles. Then after three months interval, liver metastasectomy as segmentectomy was accomplished, and segment VI of the liver involved by metastatic glomangiosarcoma was successfully removed (Figure 4).

3. Discussion

Glomus tumors within the gastrointestinal system have been reported at the gastric antrum [5-12], liver [13], duodenum [14], and cecum [7]. These reports bear the notion that, in general, glomus tumors of the stomach have an excellent prospect, with a weak recurrence rate or danger of metastasis [7-14]. The line between benign and malignant glomus tumors was not well drawn in the previous years. In 2001, Folpe et al. set particular criteria so that, in their detailed statement, glomangiosarcoma typically has a size >2.0 cm, deep location, atypical mitotic figures, or prominent atypia and mitotic activity >4 per 50 high power fields [2]. Glomangiosarcoma occurs in the skin of the limbs, where they appear afresh [2, 4, 15-18] or from malignant transformation of an assumedly favorable glomus tumor [19]. Despite their malignant histological characteristics, glomangiosarcoma rarely metastasize [3].

There have been several reports of metastases from glomangiosarcoma originating from the lung tissue, bronchial tree [13], upper extremity [15], bladder [14], and kidney [16]. Sufferers with extensive metastases from glomangiosarcoma frequently ceased living with the disease [3, 5, 20]. Glomangiosarcoma tumor along the gastrointestinal system has been recorded in small bowel [17], esophagus [12], and stomach [18]. Lee et al. reported two patients with glomangiosarcoma tumor of the stomach with extensive metastases [8].

4. Conclusion

The vast majority of gastrointestinal sarcoma tumors are gastrointestinal stromal tumors; however, glomangiosarcoma should be incorporated into differentials of stomach tumors. The diagnosis of glomangiosarcoma is confirmed by histologic and immunohistochemical assessment. Concerning statements detailed by Folpe et al. [2], deep site, spatial dimension greater than 2.0 cm, and the state of having atypical mitotic shapes are characteristics that anticipate unfavorable prognosis. Our case report emphasizes the metastatic capability of visceral glomangiosarcoma.

Ethical Considerations

Compliance with ethical guidelines

There were no ethical considerations to be considered in this research.

Funding

This research did not receive any grant from funding agencies in the public, commercial, or non-profit groups.

Authors' contributions

All authors equally contributed to preparing this article.

Conflict of interest

The authors declare no conflict of interest.

References

- [1] Tsuneyoshi M, Enjoji M. Glomus tumor. A clinicopathologic and electron microscopic study. *Cancer*. 1982; 50(8):1601-7. [DOI:10.1002/1097-0142(19821015)50:83.0.CO;2-5]
- [2] Folpe AL, Fanburg-Smith JC, Miettinen M, Weiss SW. Atypical and malignant glomus tumors: Analysis of 52 cases, with a proposal for the reclassification of glomus tumors. *The American Journal of Surgical Pathology*. 2001; 25(1):1-2. [DOI:10.1097/0000478-200101000-00001] [PMID]
- [3] Gaertner EM, Steinberg DM, Huber M, Hayashi T, Tsuda N, Askin FB, et al. Pulmonary and mediastinal glomus tumors: Report of five cases including a pulmonary glomangiosarcoma: A clinicopathologic study with literature review. *The American Journal of Surgical Pathology*. 2000; 24(8):1105-14. [DOI:10.1097/0000478-200008000-00008] [PMID]
- [4] Park JH, Oh SH, Yang MH, Kim NI. Glomangiosarcoma of the hand: A case report and review of the lit-

- erature. *The Journal of Dermatology*. 2003; 30(11):827-33. [DOI:10.1111/j.1346-8138.2003.tb00486.x] [PMID]
- [5] Wang S, Ding C, Tu J. Malignant glomus tumor of the lung with multiple metastasis: A rare case report. *World Journal of Surgical Oncology*. 2015; 13(1):1-4. [DOI:10.1186/s12957-014-0423-3] [PMID] [PMCID]
- [6] Fletcher CD, Sundaram M, Rydholm A, Coindre JM, Singer S. Soft tissue tumours: Epidemiology, clinical features, histopathological typing and grading. *Pathology and Genetics of Tumours of Soft Tissue and Bone: WHO. World Health Organization Classification of Tumours*. 2002:12. [Link]
- [7] Miettinen M, Paal E, Lasota J, Sobin LH. Gastrointestinal glomus tumors: A clinicopathologic, immunohistochemical, and molecular genetic study of 32 cases. *American Journal of Surgical Pathology*. 2002; 26(3):301-11. [DOI:10.1097/00000478-200203000-00003] [PMID]
- [8] Lee HW, Lee JJ, Yang DH, Lee BH. A clinicopathologic study of glomus tumor of the stomach. *Journal of Clinical Gastroenterology*. 2006; 40(8):717-20. [DOI:10.1097/00004836-200609000-00011] [PMID]
- [9] Huang CC, Yu FJ, Jan CM, Yang SF, Kuo YT, Hsieh JS, Wang JY. Gastric glomus tumor: A case report and review of the literature. *The Kaohsiung Journal of Medical Sciences*. 2010; 26(6):321-6. [DOI:10.1016/S1607-551X(10)70046-2]
- [10] Tsagakataki ES, Flamourakis ME, Gkionis IG, Giakoumakis MI, Delimpaltadakis GN, Kazamias GM, et al. Gastric glomus tumor: A case report and review of the literature. *Journal of Medical Case Reports*. 2021; 15(1):1539-46. [DOI:10.1177/147323001003800438] [PMID]
- [11] Kang G, Park HJ, Kim JY, Choi D, Min BH, Lee JH, et al. Glomus tumor of the stomach: A clinicopathologic analysis of 10 cases and review of the literature. *Gut and liver*. 2012; 6(1):527. [DOI:10.5009/gnl.2012.6.1.52] [PMID] [PMCID]
- [12] Troller R, Soll C, Breitenstein S. Glomus tumour of the stomach. *Case Reports*. 2016; 2016:bcr2015214135. [DOI:10.1136/bcr-2015-214135] [PMID] [PMCID]
- [13] Jaiswal VR, Champine JG, Sharma S, Molberg KH. Primary glomangioma of the liver: A case report and review of the literature. *Archives of Pathology & Laboratory Medicine*. 2004; 128(3):e46-9. [DOI:10.5858/2004-128-e46-PGOT-LA] [PMID]
- [14] Jundi M, Lack EE, Brun EA, Esquivel J, Kumar D. Glomus tumor of the duodenum: A case report. *International Journal of Surgical Pathology*. 2004; 12(4):411-4. [DOI:10.1177/106689690401200417] [PMID]
- [15] Matsumoto K, Kakizaki H, Yagihashi N, Yagihashi S. Malignant glomus tumor in the branchial muscle of a 16-year-old girl. *Pathology International*. 2001; 51(9):729-34. [DOI:10.1046/j.1440-1827.2001.01268.x] [PMID]
- [16] Oh SD, Stephenson D, Schnall S, Fassola I, Dinh P. Malignant glomus tumor of the hand. *Applied Immunohistochemistry & Molecular Morphology*. 2009; 17(3):264-9. [DOI:10.1097/PAI.0b013e31818a9d5d] [PMID]
- [17] Terada T, Fujimoto J, Shirakashi Y, Kamo M, Sugiura M. Malignant glomus tumor of the palm: A case report. *Journal of Cutaneous Pathology*. 2011; 38(4):381-4. [DOI:10.1111/j.1600-0560.2009.01490.x]
- [18] Lancerotto L, Salmaso R, Sartore L, Bassetto F. Malignant glomus tumor of the leg developed in the context of a superficial typical glomus tumor. *International Journal of Surgical Pathology*. 2012; 20(4):420-4. [DOI:10.1177/1066896911432454] [PMID]
- [19] Damavandy AA, Anatelli F, Skelsey MK. Malignant glomus tumor arising in a long standing precursor lesion. *American Journal of Dermatopathology*. 2016; 38(5):384-7. [DOI:10.1097/DAD.0000000000000481] [PMID]
- [20] Brathwaite CD, Poppiti RJ. Malignant glomus tumor: A case report of widespread metastases in a patient with multiple glomus body hamartomas. *American Journal of Surgical Pathology*. 1996; 20(2):233-8. [DOI:10.1097/00000478-199602000-00012] [PMID]