

## ■ Review article

## Confirming nasogastric tube position: methods and restrictions: A narrative review

Mehdi Rahimi<sup>1,\*</sup>, Khosro Farhadi<sup>2</sup>, Hossein Ashtarian<sup>3</sup>, Frahnaz Changaei<sup>4</sup>

(Received: 16 Sep 2014; Accepted: 23 Nov 2014)

### Abstract

**Background and Purpose:** Inserting a nasogastric tube, though a common clinical procedure with widespread use for critically ill patients, can produce unexpected complications so that tube misplacement into the lungs is a potential complication with serious consequences. The reliability of common bedside methods to differentiate between pulmonary and gastric placement has not been acceptable. The goal of this study was to review the diagnostic accuracy of methods in detecting inadvertent airway intubation and verifying correct placement of nasogastric tube and restrictions.

**Methods:** A review of Pub Med, Medline and CINAHL databases has been conducted to identify peer-reviewed, English language, human subject research studies published between the years 1994 and 2013. The research was conducted on the confirmation, methods and restrictions of NGT in the adult's population. Out of 151 English publications, 29 were duplicates and 2 were animal studies. Quality assessments, data extractions and analysis were completed on all included studies.

**Results:** Although methods for assessing correct NGT location at the bedside are available, each has its limitations. The methods include auscultation (the most common method), PH testing of aspirates, capnography, insertion under direct vision and magnetic detection. All studies used X-rays as the reference standard for comparison since auscultation is unreliable.

**Conclusion:** While none of the existing bedside methods for testing the position of nasogastric tubes is totally reliable, the evidence suggest that using more than one method for confirmation of nasogastric tube position is necessary.

**Keywords:** limitations, Confirmation, Nasogastric tube, Tube position

### Introduction

Nasogastric tube (NGT) is in widespread use for critically ill patients (1,2). The main reasons for inserting a NGT are to decompress the stomach and remove stomach content, assessment, enteral feeding and medication administration (3). It is estimated that more than 1.2 million feeding tubes are used each year in the United States alone (4) and The National Patient Safety Agency (NPSA)

estimates that at least 1 million tubes are purchased every year in England and Wales (5). Then nasogastric tube insertion is a usual procedure in the intensive care unit (ICU) (6).

Although often considered an innocuous procedure, blind placement of a feeding tube can cause serious damage and even death (7, 8).

Nasal insertion of the tubes has been widely

<sup>1</sup>\*Corresponding author: Department of Medical Surgical Nursing, Nursing & Midwifery School, Lorestan University of Medical Sciences, Lorestan, Iran. Email: mehdirahimi414@yahoo.com.

<sup>2</sup>Department of Anesthesia and Assistant Professor of Kermanshah University of Medical Sciences, Kermanshah, Iran.

<sup>3</sup>Department of Nursing Educations and Management, Nursing and Midwifery School, Kermanshah University of Medical Sciences, Kermanshah, Iran.

<sup>4</sup>Department of Midwifery, Nursing and Midwifery School, Lorestan University of Medical Sciences (LUMS), Lorestan, Iran.

practiced since the early 1980s, and is associated with complications including intrapulmonary feeding or “aspiration by proxy” and esophageal perforation (5).

Misplacement of NGT into the lungs may lead to serious complications including intrapulmonary infusion of fluids, pneumothorax, pneumonitis (8), hydropneumothorax, bronchopleural fistula, empyema, and pulmonary hemorrhage (9).

Other complications accompanying nasally placed tubes may include disrupted breathing, sinusitis and epistaxis (8). Although rare, nasogastric tubes may be misplaced in the brain, especially in patients following maxillofacial trauma (9) or after endoscopic skull base surgery (10).

The presence of an endotracheal tube or tracheostomy does not protect the tracheobronchial tree from accidental placement (2, 5,11,12). Patients with low consciousness or decreased cough or gag reflex are more prone to misplacement in the tracheobronchial tree (2). It is difficult to estimate the prevalence of tube misplacement since cases are not frequently reported. In a review of over 2,000 feeding tube insertions, investigations found that nasogastric tubes were misplaced in 1.3 to 3.2 percent of all insertions. Serious complications were associated with the misplacements in 28% of the patients (13). Rassias reported 2% incidence of tracheopulmonary complications among 740 tube insertions and 0.3% deaths due to the complications (9). Reported misplacement rates vary widely from 1.4 to 27% (14,15).

The confirmation of correct positioning of NG tubes is carried out at bedside by the nurse on duty and a wide range of methods for this purpose are described in the literature (16). A common method to verify tube placement involves auscultation. However, evidence from several systematic reviews concluded that this method is not advisable due to the risk of false negative results and thereby not identifying the misplaced NG tubes (7,17). Another commonly used method is measuring pH from aspirate from NG tube

where low pH indicates the presence of gastric acid and thereby correct positioning of NG tube. However, this method is also related to certain problematic issues (2). Other methods include insertion under direct vision, capnography, magnetic detection and X-ray that have some restrictions (5,17). Better designed studies exploring the accuracy of methods are required to improve the diagnostic policy (5,11).

Consequently, the objective of this review is to review the methods' diagnostic accuracy in detecting inadvertent airway intubation and verifying (confirmation) the correct placement of nasogastric tube and restrictions.

## Materials and Methods

A narrative review of studies was undertaken. A three-step search strategy will be utilized in this review. An initial limited search of Pub Med, Medline and CINAHL will be undertaken, followed by the analysis of text words contained in the title and abstract, and of the index terms used to describe the article. A second search using identified keywords and index terms will then be undertaken across all included databases. Index terms will be selected to match the specific database since index terms may vary between databases. Thirdly, the reference lists of the reports and articles included for critical appraisal will be explored for additional studies. Studies published in English will be considered for inclusion in this review. This relates to the expertise of the review team.

The search strategy included a MeSH Terms search using “Enteral Nutrition” and “Intubation, gastrointestinal” and relevant subheadings, with the search restricted to major topic headings only. The following search term strategy was also used: “NG, nasogastric, gastric, enteral” AND “feeding, nutrition, tube, tubes” AND “correct position, checking procedures, correct placement, accurate location, location, positioning, placement”. In addition, the studies that evaluated the diagnostic

accuracy of the methods in detecting inadvertent airway intubation and differentiating between respiratory and gastrointestinal tube placement were included. The search cases were limited to include only human studies published in English language between the years 1994 and 2013. The related articles function was used to broaden the search, and all abstracts, studies and citations scanned were reviewed. This review excluded descriptive reports, literature reviews, expert opinions and studies of other types of tubes such as nasointestinal feeding, gastrostomy and jejunostomy tubes. Since chest X-ray is widely accepted as the gold standard for verifying NG tube placement (2,11) it will also be viewed as the gold standard by this systematic review.

Of 151 English publications, 29 were duplicates, and 2 were animal studies. Quality assessments, data extractions and analysis were completed on all of the included studies. In other words, data

will be extracted by two reviewers independently. Any discrepancies among the reviewers will be resolved by discussion.

### Results

Our literature review reveals various and unusual complications associated with their use. For providing a complete picture, we outline both thoracic and non-thoracic misadventures below.

We go on to discuss only the thoracic complications in this review.

Our review studies including: observing for respiratory signs (5,7), auscultation (2,8,18-20), observing visual characteristics of aspirate from the tube (17), pH testing of aspirates (2,5,17,21), insertion under direct vision (2), capnography/colorimetry (5,11,22-24), magnetic detection (1,5,17), radiography/x-ray (5, 12, 16, 18, 19, 25). Some research is given in Table 1.

**Table 1.** Assessment methods to determine the correct gastric tube placement

Reference (Author, Year, Title)	Purpose Questions/Hypothesis	Design/Sample Setting	Findings
Burns, S. M., et al (2006). Detecting inadvertent airway intubation during gastric tube insertion: Capnography versus a colorimetric carbon dioxide detector.	Study Purpose: 1. Compare the accuracy of colorimetry vs. capnography in determining GT placement in lung 2. Describe variables that correlate with inadvertent GT airway intubation Hypothesis/Theoretical Framework: Colorimetric CO detector will indicate the presence of CO2 as accurately as capnography does.	Design: Non-experimental N = 52 misplaced tubes out of 195 GT insertions (130 patients) Randomization: No Convenience Sample: Yes Population: Adult MICU patients Setting: Urban Acute Care Hospital (expedited); no consent required)	1. 100% agreement between colorimetry and capnography in identifying CO2 when the tube was inserted into an endotracheal tube in situ (n=5) 2. Insertion failure: 27% of attempts failed per capnometer (disposable sensor detected CO2 in all failures).
Elpern, E. H., et al (2007). Capnometry and air insufflations for assessing initial placement of gastric tubes.	Study Purpose: 1. Compare accuracy of Capnometry and air insufflations with radiography to detect GT placement 2. Determine the occurrence of false positives and false negatives with air insufflations and Capnometry (specific to large bore tubes)	N= 91 GT placements (69 patients) Randomization :No Convenience Sample; Yes Population: Adult pts. In MICU or intermediate care unit Setting: Urban Acute Care Hospital IRB Approval: Yes	No lung GT placements. Unable to document false-negatives. 16% false positives with Capnometry; 5% with insufflations
Metheny, N., et al (1994). Visual characteristics of aspirates from feeding tubes as a method for predicting tube location.	Study Purpose: To determine characteristics of tube placed in GI vs. respiratory tract and to determine to what extent nurses are able to judge placement based on the visual characteristics of aspirate. Significance: Highly clinically significant	Design: Descriptive Sample: Convenience N=880 aspirates. 444 from stomach; 448 from intestine; conducted by 30 acute care nurses in urban hospital setting.	Nurses' ability to identify 50 gastric and intestinal aspirates significantly improved after reading a list of suggested Characteristics of feeding tube aspirates (81.33%).

Cont. Table 1.

Reference (Author, Year, Title)	Purpose Questions/Hypothesis	Design/Sample Setting	Finding
Kearns, P., et al (2001). A controlled comparison of traditional feeding tube verification methods to a bedside, electromagnetic technique.	Purpose: Compare diagnostic test characteristics of four GT confirmation methods: auscultation, pH, visual inspection of aspirate, or electromagnetic technique.	Prospective, blinded multisite trial-including ward and ICU patients from four acute care hospitals. Total of 113 patients ages 18 and older completed entire protocol. Total of 134 GT (small bore) placements in study.	Agreement with x-ray confirmation of placement : Auscultation: 84% Aspiration: 50% pH: 56 % Electromagnetic: 76% Electromagnetic and visual inspection identified 100% of GT above the diaphragm. Aspiration unsuccessful in making a determination 53% of the time. Electromagnetic device successful 90% of time.
Taylor, S. J., et al (2005). Confirmation of nasogastric tube position by pH testing.	1. What is the appropriate hospital population for pH testing method of NG tube placement? Number of patients. on H2 2. blockers/proton-pump inhibitor and methods of GT confirmation. 3. How does pH testing compare with different pH strips	Design two phase observational study N= Phase 1: 52 patients (1 day survey of all pts requiring NG and NI feeding within a geographic area); Phase 2: 6 types of pH strips, number of testers unknown Randomization: No Convenience: Yes Population: ICU	PH strips more reliable than Litmus paper; pH strip testing unreliable in 29% of patients with NG tubes receiving proton-pump inhibitor or H-2 blocker.

Methods for Confirming Nasogastric Tube Position: Improving safe and cost-effective procedures for patient care is essential. Methods for verifying the tube sites vary between hospitals and countries. Nurses are often responsible for placing nasogastric tubes in critically ill patients (1,11) and checking for correct NG tube placement had always been a part of the nursing process (26).

Methods to Check Correct Placement of Nasogastric Tube include: Observing for respiratory signs or symptoms such as coughing, dyspnoea, or cyanosis does not provide evidence of tube misplacement into the lungs. In addition, the use of fine-bore tubes for feeding delivery is increasingly accepted as standard, and these tubes can inadvertently be placed into tracheobronchial tract without causing any subjective or objective changes in the clinical state of the patient (5).

Auscultation; the most common method is to auscultate the epigastric region during air insufflations and is still used to check placement in many settings (2,5,8). Auscultation is a simple and low-cost method (18). An American Association of Critical Care Nurses (AACN) practice alert in 2007 suggested auscultation method unreliable for the tubes placement verification (19). Although this is a frequently used method in the clinical setting, research literature does not support the reliability of

this method (17,18,20). In addition, the misclassified NG tubes were located in the right lower lobe bronchus and the right pleural space, but loud gurgling sounds were still heard when auscultated at the epigastrium while inflating 20ml air into the NG tube (5).

Observing visual characteristics of aspirate from the tube; observing the visual characteristics of feeding tube aspirates is of little value in differentiating between respiratory and GI placement (17,27).

PH testing of aspirates; if the aspirate pH is 4.0 or lower, feeding can start safely and tube placement is correct (5). In one trial, pH of 4 was able to accurately identify the location of only 56% of all NGTs (17). The pH method has no benefit in detecting placement of a feeding tube in the esophagus. Fluid withdrawn from the esophagus can be swallowed with alkaline saliva or refluxed acidic gastric juice (21). In addition, the pH test can be misleading because of the significant variations of intragastric pH in critically ill patients because of the extensive use of ulcer prophylactic therapy (2).

Insertion under direct vision; this method is the best method to insure correct placement in high-risk patients. This can be achieved either by using a Laryngoscope or fiberoptic endoscope to insure correct placement (2). The methods are costly, delay

feeding and incur risk, endoscopy by being invasive and fluoroscopy from transportation off-ward (28).

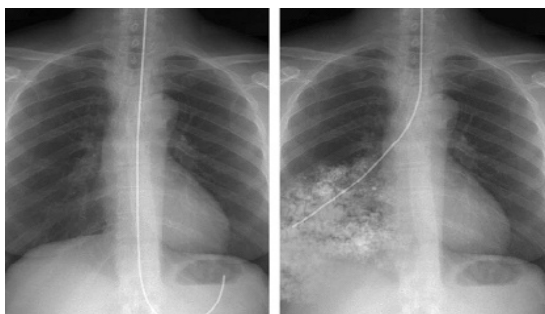
Capnography/colorimetry; to detect carbon dioxide (CO<sub>2</sub>) through the tubes as an indicator of misplacement in the respiratory tree. The use of colorimetric capnography and epigastric auscultation to confirm feeding tube placement improves nurse's organization of care, saves time, and decreases costs (22) and is a safe method (6).

In contrast, the studies to date give conflicting results of CO<sub>2</sub> detection with tubes coiled in the mouth or pharynx (5).

A study indicated that Capnometry incorrectly identified 16% of gastrointestinal placement as in the lung (11).

Magnetic detection; the third study demonstrated that magnetic detection method was 100% sensitive in detecting misplaced tubes, although it was unable to determine the exact location of the tubes (17). The presentation of the data for this study is incomplete and inconsistent, making the interpretation of the results difficult (5). Further well-designed prospective studies are needed to evaluate the technology.

X-ray; Radiography/x-ray is the gold standard to verify nasogastric tube placement (18,25) because it visualizes anatomy in the context of tube position (12). However, the challenge with using radiography routinely is because of causing delays in tube feedings, radiographic exposures, and added cost (25). In addition, a radiographic test cannot be performed by the bedside nurse (19) Figure 1 (20).



**Figure 1.** Chest X-rays show a correctly positioned nasogastric tube (left) and a nasogastric tube inadvertently positioned in the lower lobe of the right lung and a resulting infiltrate (right). By the courtesy of Pennsylvania Patient Safety Advisory.

## Discussion

Despite widespread use of nasogastric tubes in clinical practice, there is little research on the accuracy of bedside checking procedures for the confirmation of NGT position. Nurses are often responsible for the placement of NGTs in inpatients, and there is a risk of inadvertent pulmonary intubations (3).

Many techniques and tools have been developed to insert NGTs, with variable success (29).

The focus of our recommendations is the safest outcome for the patients requiring nasogastric tube. Many methods and tools have been developed to insert NGTs, with variable success. The most popular method was auscultation. A survey on 383 intensive care units in 20 countries found that 73% of the nurses used the auscultation method as the most common method to check the placement (25).

Despite the fact that auscultation is ineffective, changing long-standing traditional nursing care practices can be difficult. The primary problem with auscultation is that sounds can be transmitted to the epigastrium regardless of whether the NG tube is placed in the lung, esophagus, stomach, duodenum or proximal jejunum (18). Besides, auscultation method has been discredited largely due to numerous case reports of tube misplacement in which this method falsely indicated the correct gastric position (5). Another method is observing for cough or cyanosis. Studies imply that signs or symptoms such as coughing, dyspnoea, or cyanosis does not provide evidence for tube misplacement in the airway. These signs may be absent in either unconscious patients or those with a poor gag reflex (18).

Another commonly used method is measuring pH from aspirate. Numerous studies have assessed the accuracy of measuring the aspirate pH to predict the feeding tube placement (5). In adults, mean gastric pH is  $3.52 \pm 2.02$ . This can be differentiated from pleural pH of  $7.92 \pm 0.28$  or tracheobronchial PH of  $7.81 \pm 0.71$ , but values  $\geq 6.0$

cannot differentiate fluid from the lung, esophagus or small bowel pH of  $6.94 \pm 1.31$ . A pH of  $\leq 4.0$  would exclude lung placement but may be clinically impractical because pH goes up by H<sub>2</sub>-blockers or proton-pump inhibitors (5).

Two other methods are Endoscopy and Fluoroscopy; however, both methods are costly, delay feeding and incur risk, that is, endoscopy by being invasive and fluoroscopy from transportation off-ward (30). Another method is Capnography and Capnometry that can reduce the risk from lung trauma and X-ray-associated costs but they must be combined with a method that confirms gastrointestinal position, particularly to eliminate oral, nasopharyngeal and esophageal misplacement (11).

Capnography was also able to identify tubes located in the esophagus and in the oral cavity but was unable to differentiate between the two (3). In addition, auscultation, appearance, and capnography/colorimetry should not be used on their own (5).

Despite possibilities for misinterpretations (5,7), X-rays remain the current gold standard for tube site verifications (2,9,31).

Finally no single bedside method has been shown to be reliable for continuous assessment of tube position (5,7,32). Unfortunately, a post procedural radiograph does not prevent some complications of tracheobronchial insertion such as pneumothorax because pneumothorax occurs when the diameter of the feeding tube is greater than that of the bronchus where it is inserted (23). Minimizing the number of x-rays is important in order to avoid increased exposure to radiation, loss of feeding time and increased handling of seriously ill patients (33).

## Conclusions

Due to the heterogeneity of the studies and small sample sizes, no conclusion can be drawn about the diagnostic performance of the different methods. In summary, no single bedside method is perfect for the confirmation of tube position and

it is essential to perform large prospective clinical studies to further evaluate the emerging technologies.

While none of the existing bedside methods for testing the position of nasogastric feeding tubes is totally reliable, there is evidence suggesting that using more than one method for the confirmation of nasogastric tube position is necessary.

## Conflict of interests

The authors declare that they have no competing interests.

## Author's Contributions

M. Rahimi and H. Ashtarian: contribution in designing, writing, revising and approving the final manuscript. K. Farhadi: performing the interviews and designing, interpreting the discussion and A. Mohamadi: doing data collection and approving the final manuscript as well.

## Acknowledgement

The authors sincerely appreciate the editor, all colleagues, and the anonymous referees for their valuable comments.

The authors sincerely appreciate the editor, all colleagues, and the anonymous referees for their valuable comments.

## References

1. Rivera R, Campana J, Hamilton C, Lopez R, Seidner D. Small Bowel Feeding Tube Placement Using an Electromagnetic Tube Placement Device Accuracy of Tip Location. *J Parenter Enteral Nutr.* 2011; 35(5): 636-42.
2. Kawati R, Rubertsson S. Malpositioning of fine bore feeding tube: a serious complication. *Acta Anaesthesiol Scand.* 2005; 49(1): 58-61.
3. Chau JP, Lo SH, Thompson DR, Fernandez R, Griffiths R. Use of end-tidal carbon dioxide detection to determine correct placement of nasogastric tube: A meta-analysis. *INT J NURS STUD.* 2011; 48(4): 513-21.

4. Krenitsky J. Blind bedside placement of feeding tubes: treatment or threat? *PRACT GASTROENTEROL*. 2011; 32.
5. Hanna G, Phillips L, Priest O, Ni M. Improving the safety of nasogastric feeding tube insertion. Developing guidelines for the safe verification of feeding tube position-a decision analysis approach (A report for the NHS patient safety research portfolio) 2010.
6. Meyer P, Henry M, Maury E, Baudel J-L, Guidet B, Offenstadt G. Colorimetric capnography to ensure correct nasogastric tube position. *J Cri Care*. 2009; 24(2): 231-5.
7. Bourgault AM, Halm MA. Feeding tube placement in adults: safe verification method for blindly inserted tubes. *Am J of Crit Care*. 2009; 18(1): 73-6.
8. Metheny NA, Meert KL, Clouse RE. Complications related to feeding tube placement. *Curr Opin in Gastroenterol*. 2007; 23(2): 178-82.
9. Pillai JB, Vegas A, Brister S. Thoracic complications of nasogastric tube: review of safe practice. *Interact Cardiovas Thorac Surg*. 2005; 4(5): 429-33.
10. Hanna AS, Grindle CR, Patel AA, Rosen MR, Evans JJ. Inadvertent insertion of nasogastric tube into the brain stem and spinal cord after endoscopic skull base surgery. *Am j otolaryngol*. 2012; 33(1): 178-80.
11. Elpern EH, Killeen K, Talla E, Perez G, Gurka D. Capnometry and air insufflation for assessing initial placement of gastric tubes. *American Journal of Critical Care*. 2007; 16(6): 544-9.
12. Wang P-C, Tseng G-Y, Yang H-B, Chou K-C, Chen C-H. Inadvertent tracheobronchial placement of feeding tube in a mechanically ventilated patient. *J Chin Med Assoc*. 2008; 71(7): 365-7.
13. Sorokin R, Gottlieb JE. Enhancing patient safety during feeding-tube insertion: a review of more than 2000 insertions. *J of Parenter Enter Nutr*. 2006; 30(5): 440-5.
14. Burns SM, Carpenter R, Blevins C, Bragg S, Marshall M, Browne L, et al. Detection of inadvertent airway intubation during gastric tube insertion: capnography versus a colorimetric carbon dioxide detector. *Am J Crit Care*. 2006; 15(2): 188-95.
15. Sparks DA, Chase DM, Coughlin LM, Perry E. Pulmonary Complications of 9931 Narrow-Bore Nasoenteric Tubes During Blind Placement A Critical Review. *JPEN J Parenter Enteral Nutr*. 2011; 35(5): 625-9.
16. Metheny NA, Meert KL. Monitoring feeding tube placement. *Nutr Clinl Pract*. 2004; 19(5): 487-95.
17. Institute JB. Methods for determining the correct nasogastric tube placement after insertion in adults. *The JBI Database of Best Practice Information Sheets and Technical Reports*. 2010; 14(1): 1-4.
18. Farrington M, Lang S, Cullen L, Stewart S. Nasogastric tube placement verification in pediatric and neonatal patients. *Pediatr Nurs*. 2009; 35(1): 17.
19. Proehl JA, Heaton K, Naccarato MK, Crowley MA, Storer A, Moretz JD, et al. Emergency nursing resource: gastric tube placement verification. *J Emerg Nurs*. 2011; 37(4): 357-62.
20. Simons SR, Abdallah LM. Bedside assessment of enteral tube placement: aligning practice with evidence. *AJN The Am J Nurs*. 2012; 112(2): 40-6.
21. Metheny NA, Clouse RE, Clark JM, Reed L, Wehrle MA, Wiersema L. pH testing of feeding-tube aspirates to determine placement. *Nutr Clin Pract*. 1994; 9(5): 185-90.
22. Galbois A, Vitry P, Ait-Oufella H, Baudel J-L, Guidet B, Maury E, et al. Colorimetric capnography, a new procedure to ensure correct feeding tube placement in the intensive care unit: An evaluation of a local protocol. *J Crit Care*. 2011; 26(4): 411-4.
23. Meyer P, Henry M, Maury E, Baudel JL, Guidet B, Offenstadt G. Colorimetric capnography to ensure correct nasogastric tube position. *J Crit Care*. 2009; 24(2): 231-5. PubMed PMID: 19327299. Epub 2009/03/31. eng.
24. Ortega R, Connor C, Kim S, Djang R, Patel K. Monitoring ventilation with capnography. *N Engl J Med*. 2012; 367(19): e27. PubMed PMID: 23134404. Epub 2012/11/09. eng.
25. Chan E-Y, Ng IH-L, Tan SL-H, Jabin K, Lee L-N, Ang C-C. Nasogastric feeding practices: A survey using clinical scenarios. *Int J Nurs Stud*. 2012; 49(3): 310-9.
26. Tho PC, Mordiffi S, Ang E, Chen H. Implementation of the evidence review on best practice for confirming the correct placement of nasogastric tube in patients in an acute care hospital. *Int J Evid Based Healthc*. 2011; 9(1): 51-60.
27. Metheny NA, Titler MG. Assessing placement of feeding tubes. *AJN The Am J Nurs*. 2001; 101(5): 36-45.

28. Metheny NA. Preventing respiratory complications of tube feedings: evidence-based practice. *Am J Crit Care*. 2006; 15(4): 360-9.
29. Halloran O, Grecu B, Sinha A. Methods and complications of nasoenteral intubation. *JPEN J Parenter Enteral Nutr*. 2011; 35(1): 61-6.
30. Fuchs J, Schummer C, Giesser J, Bayer O, Schummer W. Detection of tracheal malpositioning of nasogastric tubes using endotracheal cuff pressure measurement. *Acta Anaesthesiol Scand*. 2007; 51(9): 1245-9.
31. Taylor SJ, Fettes SB, Jewkes C, Nelson RJ. Prospective, randomized, controlled trial to determine the effect of early enhanced enteral nutrition on clinical outcome in mechanically ventilated patients suffering head injury. *Crit Care med*. 1999; 27(11): 2525-31.
32. Wentzel Persenius M, Larsson BW, Hall-Lord M-L. Enteral nutrition in intensive care: nurses' perceptions and bedside observations. *Intensive Crit Care Nurs*. 2006; 22(2): 82-94.
33. Ioos V, Galbois A, Chalumeau-Lemoine L, Guidet B, Maury E, Hejblum G. An integrated approach for prescribing fewer chest x-rays in the ICU. *Ann Intensive Care*. 2011; 1(1).