

Anti-Inflammatory Effect of *Ocimum Basilicum* Linn. Seeds Hydroalcoholic Extract and Mucilage on Acetic Acid-Induced Colitis in Rats

Fahimeh Saeidi^a, Sayed-Ebrahim Sajjadi^b, Mohsen Minaiyan^{c*}

^a School of Pharmacy and Pharmaceutical Sciences, Isfahan University of Medical Sciences, Isfahan, Iran

^b Department of Pharmacognosy, School of Pharmacy and Pharmaceutical Sciences, Isfahan University of Medical Sciences, Isfahan, Iran

^c Department of Pharmacology and Pharmaceutical Sciences Research Center, School of Pharmacy and Pharmaceutical Sciences, Isfahan University of Medical Sciences, Isfahan, Iran

ARTICLE INFO

Article Type:
Research Article

Article History:
Received: 2018-05-12
Revised: 2018-06-25
Accepted: 2018-07-14
ePublished: 2018-07-26

Keywords:
Acetic acid
Basil seed mucilage
Colitis
Ocimum basilicum
Plant extract

ABSTRACT

Seeds of *Ocimum basilicum* (Basil) have many phytochemical components with anti-inflammatory and antioxidant property like its leaves. Aim of this study was to determine anti-inflammatory effect of *O. basilicum* seeds extract (OBSE) and mucilage (OBSM) on acetic acid-induced colitis in rats. Three doses of OBSE and OBSM (100, 200, and 400 mg/kg) were administered orally to separate groups of male Wistar rats, 2 h before ulcer induction (acetic acid 4%) and continued for 5 days. Normal saline (5 ml/kg) and dexamethasone (1 mg/kg) were administered in control and reference groups, respectively. All rats were sacrificed 24 h after the last dose (at sixth day) and tissue injuries were assessed macroscopically, pathologically and for myeloperoxidase (MPO) activity. All three doses of OBSM and OBSE reduced ulcer score, area and index as well as weight of wet colonic tissue compared to the control group significantly. In addition, OBSM (at three doses) and OBSE (400 mg/kg) were statistically effective in attenuation of mucosal inflammation severity and extent, crypt damage, total colitis index, and mono-amino oxidase (MPO) activity compared with controls. While both fractions were effective in amelioration of colitis in rats, OBSM was more effective than OBSE especially with greater doses (200, 400 mg/kg). It seems that mucilage form of *O. basilicum* could exert more protection against oxidative stress and inflammatory mediators in colitis tissue suggesting a suitable candidate for colitis prevention or treatment as alternative or complementary therapy.

*Corresponding Author: Mohsen Minaiyan, E-mail: minaiyan@pharm.mui.ac.ir

Introduction

Ulcerative colitis (UC) and Crohn's disease (CD), are chronic inflammatory conditions of the gastrointestinal (GI) tract that known as a chronic idiopathic inflammatory bowel diseases (IBD) [1,2]. Although the etiological factors not apparent, recent studies have been suggested that a combination of genetic susceptibility factors, microbial agents along with exacerbations of immune response to bacterial antigens in mucosal region contributes in pathological process and relapse of IBD [3,4]. Pathologically, UC is often characterized by infiltration of immune cells including neutrophils, macrophages, lymphocytes and pathologic cytokines production accompany with eicosanoids and reactive oxygen species [5]. The pathologic manifestation could be identified by acute and chronic intestinal inflammation [5]. To date, several medicines have been used in the treatment of UC, such as 5-aminosalicylic acid derivatives, azathioprine, 6-mercaptopurine, cyclosporine A, and monoclonal antibodies for targeting TNF-alpha receptors [6,7]. In recent years, public trend has been increased in the usage of herbal products, because of easy accessibility, inexpensive, and possibly their lower adverse effects especially in the UC treatment [8]. Medicinal plants have been used as an important source to study of new compounds with anti-inflammatory potential. *Ocimum basilicum* L. (Lamiaceae), known as basil, is cultivated as a culinary, industrial and medicinal plant in many countries from thousands years ago. *O. basilicum* is a well-known edible natural compound with aromatic terpenoids (estragole and alpha-terpinolene), essential oils (linalool, beta-pinene, trans-verbrenol, limonene), phenolic acids (ellagic acid, catechic acid, gallic acid) and flavonoids (quercetin, apigenin, luteolin, rutin) [9-12]. Analgesic, antispasmodic, anti-ulcerogenic, anti-inflammatory, antioxidant and immune -modulatory effects of *O. basilicum* leaves providing a good potential for the treatment of IBD, however for basil seeds (Tokhme Sharbati, Tukmeria, Falooda) there are minimal reports in this regard [13-15].

In our pervious study, authors indicated that the essential oil of *O. basilicum* which was extracted by hydro-distillation and analyzed by gas

chromatography-mass spectrometry (GC/MS) exhibited protective effect against acetic acid-induced colitis [16]. We know that the basil seeds possess mucilage and resin, phenolic compounds, flavonoids, constant oils, fatty acids, protein, terpenoids and oleoresin [17]. Albeit there is no documented report about detailed individual components of basil seeds, several uses have been reported for basil seeds in Traditional and Ayurveda medicine including: laxative and carminative, regulation of appetite and blood sugar, relieve of fatigue and depression and relieve of genitourinary tract inflammation and infection [18,19]. The shell of basil seeds has been really covered by a thick layer of mucilage so that they become quickly swollen when the seeds are soaked in water [20]. It has been reported that plants with high mucilage content e.g. Aloe, Plantain, Mallow and Quince have protective and healing activity on experimental models of colitis [21-25]. Therefore, with regard to this potential of mucilage and polyphenolic ingredients exist within the basil seeds, present study was designed to investigate anti-colitis effect of OBSE and OBSM on acetic acid induced colitis in rats.

Material and methods

Plant material and extract preparation

O. basilicum seeds were purchased from Pakan Bazr, Isfahan, Iran while the plant cultivated in the field of Malayer, Hamadan province, Iran. Its genus and variety were authenticated by Dr. Ghannadi, a pharmacognosist at the Pharmacognosy Department of Isfahan School of Pharmacy and Pharmaceutical Sciences, herbarium voucher. For preparation of OBSE, dried and fine powdered seeds of *O. basilicum* (400 g) were macerated by 800 ml of EtOH/H₂O (70/30) and left for 24 h. To achieve most complete extraction, percolation technique was consequently done using 800 ml of fresh EtOH/H₂O (70/30) for 48 h. Then, the pooled extract was filtered and evaporated in a rotary evaporator under reduced pressure until a semisolid extract yield 3.0% (w/w) was prepared. For preparation of OBSM, 500 g of *O. basilicum* seeds were macerated by 1500 ml of distilled

water (1:3) and left for 24 h. Then it was placed on a shaker for 30 minutes. In this step, the OBSM was mostly separated from the seed. Then the resultant mixture was squeezed in a fine cloth to separate the mucilage completely. Finally, the isolated mucilage was dried by freeze dryer and the resultant white powder was weighted (yield value was 1.0% (w/w)).

Drugs and chemicals

Dexamethasone powder was prepared from Iran Hormone Co. (Tehran, Iran) as a gift. Orto-dianizidin dihydrochloride (ODD) and hexa-decyl trimethyl ammonium bromide (HTAB) were obtained from Sigma Company (St. Louis, USA). Formalin solution 35% w/w and glacial acetic acid were analytical grade and purchased from Merck Company (Darmstadt, Germany). Ethanol (96%) was procured from Stalak Company (Tehran, Iran).

Animals

Fifty-four male Wistar rats (180-220 g) bred at the animal house of the School of Pharmacy, Isfahan University of Medical Sciences, Isfahan, Iran, were used in this study. Animals were maintained at controlled environmental conditions where the temperature, humidity and light/dark cycling were adjusted appropriately. All animals were fed with standard pelleted diet and had free access to tap water. Animals were housed in standard cages and acclimatized for one week before start of the treatment. All the animal handling and working were conducted according to the guidelines delineated by the Ethics Committee of Isfahan University of Medical Sciences (IR.MUI.REC.1395.3.937).

Animals were randomly assigned into following 9 groups with 6 rats in each:

Group 1 (Sham or normal group), received vehicle (normal saline) (5 ml/kg/day, p.o. and by rectal route) without colitis induction.

Group 2 (Control group), received vehicle (normal saline) (5ml/kg/day, p.o.). The first dose was administered 2 h before colitis induction.

Group 3 (Reference group), received dexamethasone (1 mg/kg/day, p.o.) initiated 2 h before colitis induction.

Groups 4, 5 and 6 (Extract groups), received 3 increasing doses of OBSE (100, 200, 400 mg/kg/day, p.o.) initiated 2 h before colitis induction.

Groups 7, 8 and 9 (Mucilage groups) received 3 increasing doses of OBSM (100, 200, 400 mg/kg/day, p.o.) initiated 2 h before colitis induction. All treatments were performed for the following 5 consecutive days.

Induction of ulcerative colitis

For inducing acute colitis, first, the rats were fasted for 24 h. Colitis was induced in rats using 2 ml acetic acid 4 % via intra-rectal administration. Briefly, under light ether anesthesia, a soft and flexible catheter (2 mm inner diameter and 10 cm in length) was inserted to the anus for 8 cm and acetic acid was carefully injected. Before taking the catheter out, the rats were maintained in a head-down position for at least 30 seconds to prevent solution spreading out [26].

Evaluation of macroscopic features

The rats were sacrificed 24 h after the last treatment (day 6) by an overdose inhalation of ether. The last 8 cm of the colon, 3 cm apart from the anus was excised, opened longitudinally, washed with normal saline, and the wet weight was measured [27]. Then the tissue specimens of colon were used for macroscopic evaluation, histopathology grading, and the measurement of tissue myeloperoxidase (MPO) activity. Macroscopic damage scoring was performed by a blind observer according to the following scale: 0 = no macroscopic changes; 1 = mucosal erythema only; 2 =mild mucosal edema, slight bleeding, or slight erosion; 3 = moderate edema, bleeding ulcers or erosions; and 4 = severe ulceration, erosions, edema, and even tissue necrosis. Colonic specimens were cut into 2 pieces, one piece for histopathology evaluation (maintained in formalin 10%) and the other for measuring MPO activity which were frozen in liquid nitrogen and kept in a freezer (-70°C). Besides, ulcer area was assessed

by Fiji-Win 32 software (NIH Image for the Macintosh, 2004). Finally, ulcer index for each specimen was measured with adding ulcer score and ulcer area values using the following formula: Ulcer index = Ulcer area (cm²) + macroscopic damage score [27].

Evaluation of histopathologic features

Tissue specimens were separately fixed in formalin 10%; paraffin embedded, processed, and sectioned in 4 mm thick layers. Then they were sequentially deparaffinized with xylene, hydrated with ethanol, and stained with hematoxylin and eosin (H&E). Inflammation severity (0 = none, 1 = slight, 2 = moderate, 3 = severe), extent (0 = none, 1 = mucosa, 2 = mucosa and submucosa, 3 = transmural and crypt damage (0 = none, 1 = basal 1/3 damaged, 2 = basal 2/3 damaged, 3 = surface epithelium intact only) were evaluated in H&E stained, encoded sections using a minor modification of a validated scoring scheme reported by Cooper *et al.* [28]. At the end, total colitis index was measured by summing the scores of inflammation severity, inflammation extent, and crypt damage. Histopathological assessments were carried out using a Zeiss microscope equipped with a Sony® color video camera (Sony, Japan) for digital imaging.

Evaluation of MPO activity

Colonic tissue activity of MPO was measured according to the method described by Motaghi *et al.* [29]. A colon tissue specimen (0.1 g) was homogenized in 1 mL of 50 mM potassium phosphate (pH, 6) with 0.5 % HTAB in an ice bath using a polytron homogenizer (Kinematica, Switzerland). Excess buffers were added to obtain a concentration equivalent to 5 mL per 0.1 g of colon tissue. The homogenate mixture was sonicated in an ice bath for 10 seconds, then subjected to a sequence of freezing and thawing for 3 times, sonicated again for 10 seconds and centrifuged for 15 minutes at 15000 rpm at 4°C. The supernatant (0.1mL) was mixed with 2.9 mL of 50 mM phosphate buffer (pH, 6) containing 0.167 mg/ml ODD and 0.0005% hydrogen

peroxide. The change in absorbance at 460 nm was measured using a UV/VIS spectrophotometer (LSI Model Alfa-1502). MPO activity was reported as U/g weight of wet colon tissue [29].

Statistical analysis

Statistical analyses were performed using SPSS (Version 19, Chicago, IL, USA). Values are given as mean ± SD and group differences were calculated by parametric one-way ANOVA test with Tukey's HSD as post hoc test. Nonparametric (scoring) data were analyzed using Mann-Whitney U test and values are given as median (range). For all tests, P < 0.05 was considered significant.

Results

Effect of OBSE and OBSM on macroscopic parameters

Observations revealed that no changes were appeared in Sham (normal) group suggesting that handling and surgical procedure had no interference with experimental results. Treatment with dexamethasone as corticosteroid reference drug reduced the ulcer score, ulcer area (cm²), ulcer index and the wet weight of 8 cm of distal colon (mg) (P<0.001) (Table 1 and Figure1). Oral treatment with all doses of OBSE and OBSM reduced the colonic wet weight compared with control group (at least P<0.01), however OBSE at 100 mg/kg had no significant effect (Table1).

The severity of lesion scores, ulcer area, hemorrhage, and edema were significantly reduced with administration of all doses of OBSE (100,200,400 mg/kg) and OBSM (100,200,400 mg/kg) nearly in a dose related manner (P<0.01). So that groups receiving 400 mg/kg OBSE and 400 mg/kg OBSM had lowest median (range) of the severity of lesion scores, ulcer area, hemorrhage, and edema (Table 1, Figure 1).

Table 1. Effect of *O. basilicum* seeds extract and mucilage on the macroscopic parameters of colitis induced by acetic acid in rats.

Group/dose (mg/kg)	Ulcer Score (0-4)	Ulcer Area (Cm ²)	Ulcer Index (0-10)	Weight of colon (mg)
Sham	0.0 (0)	0.0 ± 0.0	0.0 ± 0.0	89.6 ± 3.2
Control (colitis)	4.0 (4)	5.9 ± 0.2	9.9 ± 0.2	238.1 ± 7.6
Dexamethasone 1	1.5(1-2)***	1.3 ± 0.3***	2.8 ± 0.3***	130.6 ± 14.1***
OBSE 100	3.0 (2-4)*	3.8 ± 0.6*	6.8 ± 0.6*	223.6 ± 15.8
OBSE 200	2.0(1-4)**	2.6 ± 0.4**	4.6 ± 0.4***	184.1 ± 11.7**
OBSE 400	2.0(1-4)**	1.8 ± 0.5***	3.8 ± 0.4***	154.6 ± 6.4***
OBSM 100	2.0(2-4)**	2.5 ± 0.5**	4.5 ± 0.5***	153.0 ± 6.7***
OBSM 200	1.5(1-3)***	2.2 ± 0.4***	3.7 ± 0.3***	148.6 ± 9.4***
OBSM 400	1.0(1-2)***	1.6 ± 0.4***	2.6 ± 0.3***	137.0 ± 8.1***

Sham: normal rats received normal saline (5ml/kg/day). Control: rats with colitis received normal saline (5ml/kg/day). OBSE: *O. basilicum* seeds extract (100, 200, 300 mg/kg), OBSM: *O. basilicum* seeds mucilage (100, 200, 300 mg/kg). Data are expressed as mean ± SD or median (range) for scoring parameter, n=6). * p < 0.05, **p<0.01, ***p<0.001, denote significant difference versus control (ANOVA with Tukey’s HSD as post hoc test).

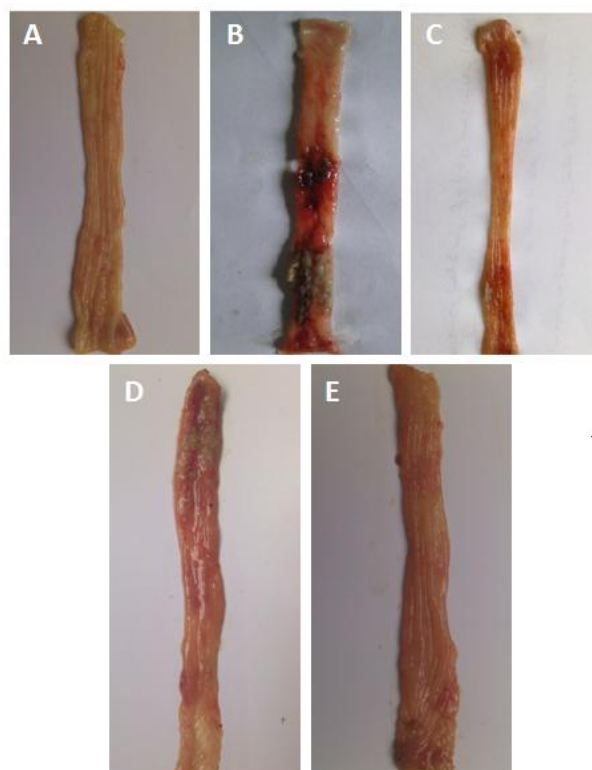


Fig. 1. Photographs of colon tissue, 5 days after acetic acid-induced colitis in rats: (A) Sham; Normal colon treated with normal saline; (B) Control colitis treated with normal saline; (C) Colitis treated with dexamethasone (1mg/kg); (D) Colitis treated with *O. basilicum* seeds extract (OBSE, 400 mg/kg). (E) Colitis treated with *O. basilicum* seeds mucilage (OBSM, 400 mg/kg).

Effect of OBSE and OBSM on pathologic parameters

Colon tissue damage well induced pathologically and histologically in control group compared to Sham group. Control group expressed destruction of epithelium, hemorrhage, edema, and inflammatory cells infiltration and crypt damage which are well defined markers of ulceration at mucus and sub-mucosal layers (Table 2 and Figure 2).

Oral administration of OBSE at 400 mg/kg was effective to reduce histopathology scores including inflammation severity, inflammation

extent, crypt damage and total colitis index (at least $P < 0.05$) (Table 2, Figure 2) compared to control colons. Two lower doses of OBSE (100, 200mg/kg), however were not effective.

Treatment with OBSM was effective to reduce histopathology scores including inflammation severity, inflammation extent, crypt damage, and total colitis index (at least $p < 0.05$) at all examined doses (Table 2, Figure 2).

Treatment with dexamethasone (1mg/kg) on the other hand, showed meaningful reduction in inflammation severity and extent, crypt damage and total colitis index (at least $p < 0.01$) after oral administration (Table 2, Figure2).

Table 2. Effect of *O. basilicum* seeds extract and mucilage on the macroscopic parameters of colitis induced by acetic acid in rats.

Group/Dose (mg/kg)	Inflam. Severity (0-3)	Inflam. Extent (0-3)	Crypt Damage (0-4)	Total Colitis Index (0-10)
Sham	0.0 (0-0)	0.0 (0-0)	0.0 (0-0)	0.0 (0-0)
Control (colitis)	3.0 (3)	3.0 (3)	3.0 (2-4)	9.0 (8-10)
Dexamethasone 1	1.0 (0-1)**	1.0 (0-2)**	1.0 (0-2)**	2.5 (0-4)***
OBSE 100	3.0 (1-3)	2.5(1-3)	2.5(0-4)	8.0 (2-9)
OBSE 200	2.5(0-3)	2.5(0-3)	1.5(1-4)	7.0 (1-10)*
OBSE 400	1.5(0-3)**	1.0 (0-2)**	2.0 (1-3)*	4.5 (1-6)**
OBSM 100	2.0 (1-3)**	2.0 (1-3)**	2.0 (0-3)*	5.5(3-9)**
OBSM 200	1.5(1-2)**	1.0 (0-3)*	1.0 (0-4) *	3.5(2-8)**
OBSM 400	1.0 (0-2)**	1.5(0-2)**	1.0 (0-2)**	3.5 (1-5)***

Sham: normal rats received normal saline (5ml/kg/day). Control: rats with colitis received normal saline (5ml/kg/day). OBSE: *O. basilicum* seeds extract (100, 200, 300 mg/kg), OBSM: *O. basilicum* seeds mucilage (100, 200, 300 mg/kg). Data are expressed as median (range), n=6). * $p < 0.05$, ** $p < 0.01$, *** $p < 0.001$, denote significant difference versus control (Mann-Whitney U test).

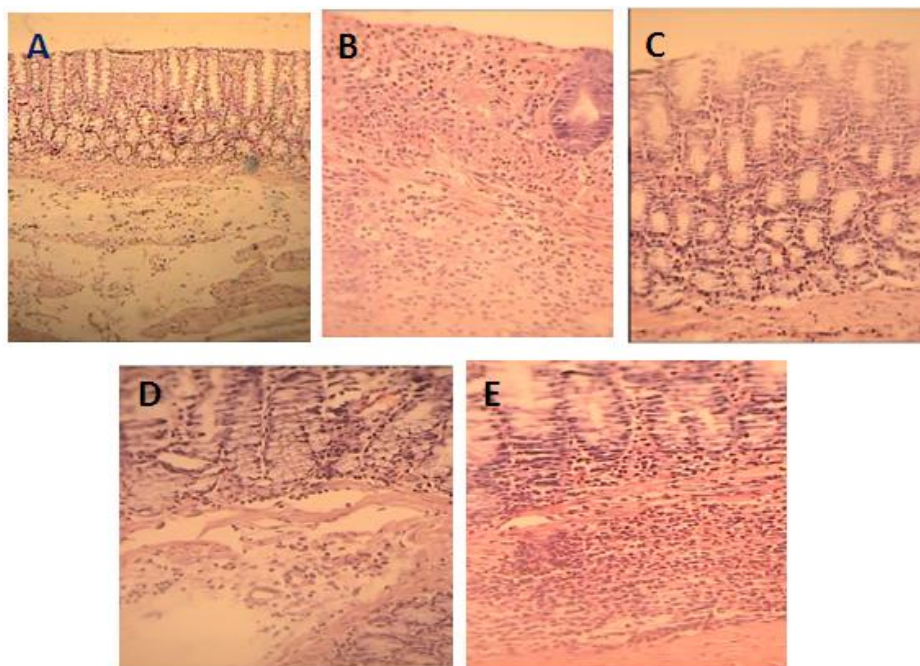


Fig. 2. Microscopic presentation of acetic acid-induced colitis in rats. (A) Normal colon treated with normal saline; mucus layer, and crypts are normal and leucocyte infiltration is negligible (B) Colitis induced by acetic acid in control group; crypt damage, mucosal layers destruction and leukocyte infiltration are evident (C) Dexamethasone (1mg/kg) treated colitis (D) Colitis treated with *O. basilicum* seeds extract (OBSE, 400 mL/kg) (E) Colitis treated with *O. basilicum* mucilage (OBSM, 400 mg/kg). H&E staining with $\times 40$ magnification.

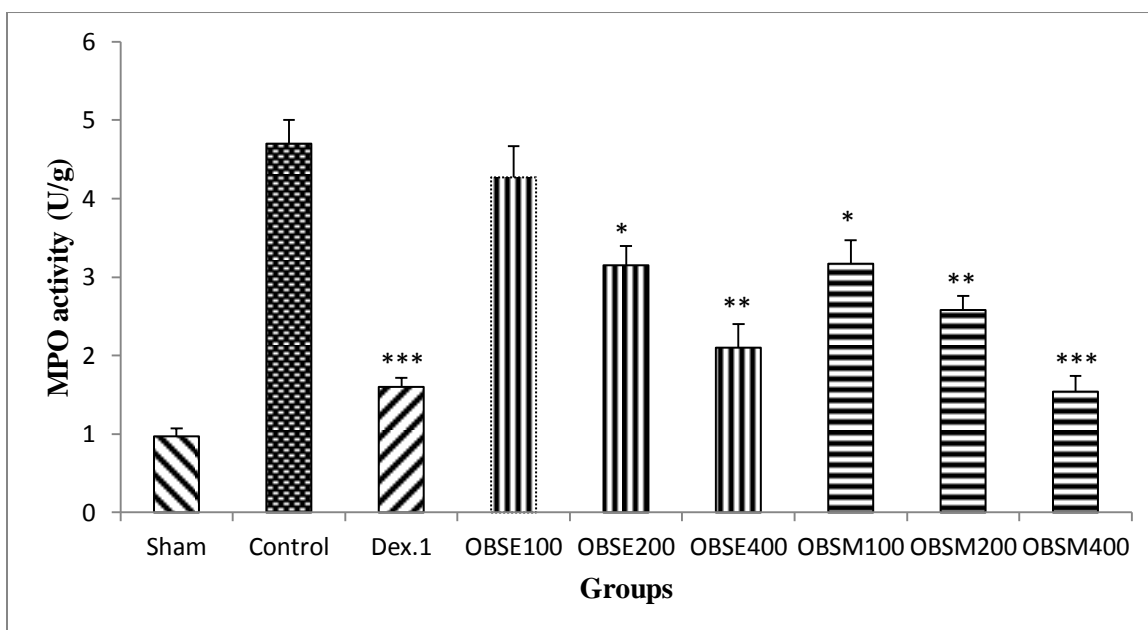


Fig. 3. Monoamino-oxidase (MPO) activity (U/g) in colonic tissue of rats treated with normal saline (5ml/kg), *O. basilicum* seeds extract (OBSE), *O. basilicum* mucilage (OBSM) and dexametazone (Dex., 1mg/kg). * $p < 0.005$, ** $p < 0.01$, *** $p < 0.001$ denote significant difference versus control (ANOVA with Tukey's HSD as post hoc test).

MPO activity measurement

Result of present study indicated that the activity of MPO enzyme was significantly diminished in both OBSE and OBSM treated groups as well as dexamethasone ($P < 0.001$) group. The exception was OBSE (100mg/kg) which was not effective ($p > 0.05$) to diminish this parameter (Figure 3).

Discussion

Results of present study indicated protective effect of OBSE and OBSM considering macroscopic, microscopic and biochemical factors in acetic acid model of experimental colitis. Phytochemical composition analysis by Parikh *et al.* revealed that *O. basilicum* seeds containing higher amount of phenolic acids and flavonoid content [30] rather than its leaves. Methanolic seed extract of *O. basilicum*, showed the presence of carbohydrate, saponins, phenolics, flavonoids, and mucilage [30]. Phenolic compounds and flavonoids e.g. rosmarinic acid, ferulic acid and caffeic acid are among potent natural antioxidants and free radical scavengers with inhibitory activities against some pathogenic microorganisms [9]. Anti-inflammatory and antioxidant properties of *Ocimum* genus has been demonstrated in several studies [9,11,14,16]. In this regard our study is in consistent with Rameshrad *et al.* [31] and Gajula *et al.* [32]. Rameshrad *et al.* reported ethanol extract of *O. basilicum* significantly decreased the inflammatory reaction in rat's paw edema induced by carrageenan. In addition Gajula *et al.* indicated Holy and culinary basil significantly reduced the number of azoxymethane- induced colon tumors as well as tumor associated edema and inflammation in fisher 344 male rats. Our results showed an increase in wet weight of distal colon and macroscopic damage score in colitis control group verifying a distinct inflammation and presence of inflammatory cells induced by acetic acid. Neutrophils are essential source of inflammatory cytokines that accumulate in inflamed colonic mucosa and cause the mucosal and sub-mucosal layers to be destructed [33]. Our findings revealed that treatment with OBSM (at all doses) and OBSE (at 200, 400 mg/kg doses) could

decrease the wet weight of distal colon segments and macroscopic damage score compared with control group. A study conducted by Rai *et al.* revealed that administration of ethanol extract of leaves and seeds of *O. canum* could decrease leucocytes number in vital (liver, kidney, heart, ...) and lymphoid organs [34].

Therefore, loose in wet weight of distal colon segments is well correlated with regression in local inflammation scores. In addition, both fractions (OBSE and OBSM) significantly decreased the histological signs of inflammation such as infiltration of lymphocytes and macrophages into the mucosa, edema, and tissue damage. Oxidative stress is one of the most important etiological and/or triggering factors for IBD. The adverse effects of reactive oxygen species (ROS) have been well known in the inflammatory process (Balmus, *et al.*). Our present research showed that administration of OBSE and OBSM decreased MPO activity intensified during acetic acid-induced colitis indicating a significant anti-inflammatory activity on this model. MPO is a membrane bound enzyme that involves in lipid peroxidation process, which acts as dominant cell effector of the innate host defense and incorporates in inflammatory tissue damage [35]. This enzyme has been found to convert hydrogen peroxide and oxygen chloride to hypochlorous acid, a powerful oxidant, that reacts readily with macromolecules to exert antimicrobial activity of neutrophils which are also involves in colonic mucosal damage [36,37]. So the activity of MPO from damaged tissue is directly proportional to the number of neutrophils observed in histological fields [38]. As it is mentioned before, the seeds of basil contain a wide range of *O. basilicum* derived compounds include mainly triterpenoids, polyphenols, steroids, flavonoids and tannins, which are considered as chemical compounds principally by anti-oxidant and anti-inflammatory activity [9,34,39,40]. So this anti-inflammatory effect on colitis might be attributed to the presence of terpenoids and flavonoids which are known to inhibit the inflammatory signaling through NF-kB suppression. [5,21,41] NF-kB through TNF-alpha activation has a pivotal role in IBD pathology and recurrence such as its suppression could result in

colitis remission both in experimental and clinical settings [41].

We showed that OBSM had stronger effect on colitis protection than OBSE. It is assumed that the mucilaginous (gum) layer forming around the basil seeds when they soaked in water causes a thickening and stabilizing agent which can improve stability and textural properties of basil seeds components [17]. In a study by Saeedi *et al.* explained *O. basilicum* mucilage have high potential to use as a controlled release excipient and has a suitable drug delivery in complex matrix [42]. The mucilaginous layer of the swollen seeds has a large capacity for hydration. It is reported that the polysaccharides extracted from basil seed composed of acid-stable core glucomannan and a (1-4)-linked xylan having acidic side chains at C-2 and C-3 of the xylosyl residues in acid-soluble portion [43]. Therefore, it is thought that this structure of OBSM can sustain and improve antioxidant property of terpenoids and phenolic compounds of seeds by slower release in colon tissue.

Conclusions

In conclusion basil seeds extract and mucilage fractions (OBSE and OBSM) could protect against acetic acid-induced colitis in rats at least by reducing leukocytes infiltration and activation and inhibiting myeloperoxidase activity within the tissue. Mucilage layer in basil seeds exerted a more potent action against colonic inflammation and confirmed again that protectant and demulcent property of mucilage and gums could be beneficial in IBD treatment and/or its recurrence prevention. However further studies are recommended to elucidate the complete mechanism of *O. basilicum* seeds action in IBD.

Acknowledgements

We thank Dr. Parvin Mahzouni for her assistance in pathologic evaluation of colonic samples. This study was financially supported by Research Council of Isfahan University of Medical Sciences under project number 395937.

Conflict of interest

Authors certify that there is no actual or potential conflict of interest in relation to this article.

References

- [1] Ko JK, Auyeung KK. Inflammatory bowel disease: etiology, pathogenesis and current therapy. *Curr Pharm Des.* 2014;20:1082-1096.
- [2] Ni J, Wu GD, Albenberg L, Tomov VT. Gut microbiota and IBD: causation or correlation? *Nat Rev Gastroenterol Hepatol.* 2017;14:573-584.
- [3] Shouval DS, Rufo PA. The role of environmental factors in the pathogenesis of inflammatory bowel diseases: A review. *JAMA Pediatr.* 2017;171:999-1005.
- [4] Mikhailov TA, Furner SE. Breastfeeding and genetic factors in the etiology of inflammatory bowel disease in children. *World J Gastroenterol.* 2009;15:270-279.
- [5] Shi XZ, Winston JH, Sarna SK. Differential immune and genetic responses in rat models of Crohn's colitis and ulcerative colitis. *Am J Physiol Gastrointest Liver Physiol.* 2011;300:G41-51.
- [6] Burger D, Travis S. Conventional medical management of inflammatory bowel disease. *Gastroenterology.* 2011;140:1827-1837.
- [7] Chang S, Hanauer S. Optimizing pharmacologic management of inflammatory bowel disease. *Expert Rev Clin Pharmacol.* 2017;10:595-607.
- [8] Ke F, Yadav PK, Ju LZ. Herbal medicine in the treatment of ulcerative colitis. *Saudi J Gastroenterol.* 2012;18:3-10.
- [9] Shirazi MT, Gholami H, Kavooosi G, Rowshan V, Tafsiry A. Chemical composition, antioxidant, antimicrobial and cytotoxic activities of *Tagetes minuta* and *Ocimum basilicum* essential oils. *Food Sci Nutr.* 2014;2:146-155.
- [10] Siddiqui BS, Aslam H, Ali ST, Begum S, Khatoon N. Two new triterpenoids and a steroidal glycoside from the aerial parts of *Ocimum basilicum*. *Chem Pharm Bull* 2007;55:516-519.
- [11] Strazzer P, Guzzo F, Levi M. Correlated accumulation of anthocyanins and rosmarini c acid in mechanically stressed red cell suspensions of basil (*Ocimum basilicum*). *J Plant Physiol* 2011;168:288-293.
- [12] Al Jaouni S1, Saleh AM2, Wadaan MAM3, Hozzein WN4, Selim S5, AbdElgawad H6. Elevated CO2 induces a global metabolic change in basil (*Ocimum basilicum* L.) and peppermint (*Mentha*

- piperita* L.) and improves their biological activity. J Plant Physiol. 2018 ;224-225:121-31.
- [13] Singh, Surender. Mechanism of action of antiinflammatory effect of fixed oil of *Ocimum basilicum* Linn. Indian J Exp Biol. 1999; 37(3):248-52.
- [14] Singh S, Taneja M, Majumdar DK. Biological activities of *Ocimum sanctum* L. fixed oil – an overview. Indian J Exp Biol. 2007;45:403 -12.
- [15] Akhtar MS1, Munir M. Evaluation of the gastric antiulcerogenic effects of *Solanum nigrum*, *Brassica oleracea* and *Ocimum basilicum* in rats. J Ethnopharmacol. 1989;27:163-176.
- [16] Rashidian A, Roohi P, Mehrzadi S, Ghannadi AR, Minaiyan M. Protective effect of *ocimum basilicum* essential oil against acetic acid-induced colitis in rats. J Evid Based Complementary Altern Med. 2016;21:NP36-42.
- [17] Gajendiran A, Thangaraman V, Thangamani V, Ravi D and Abraham J. Antimicrobial, antioxidant and anticancer screening of *Ocimum basilicum* seeds. Bull Pharm Res. 2016;6:114-119.
- [18] Kamyab AA, Eshraghian A. Anti-Inflammatory, gastrointestinal and hepatoprotective effects of *Ocimum sanctum* Linn: an ancient remedy with new application. Inflamm Allergy Drug Targets. 2013;12:378-384
- [19] DelRe PV, Jorge N. Antioxidant potential of oregano (*Oreganum vulgare* L.), basil (*Ocimum basilicum* L.) and thyme (*Thymus vulgaris* L.): application of oleoresins in vegetable oil. Cienciae Tech Alimen Campinas. 2011;31:955-959.
- [20] Azuma J, Sakamoto M. Cellulosic hydrocolloid system present in seed of plants. Trends Glycosci Glycotechnol. 2003;15:1-14.
- [21] Gautam MK, Goel S, Ghatule RR, Singh A, Nath G, Goel RK. Curative effect of *Terminalia chebula* extract on acetic acid-induced experimental colitis: role of antioxidants, free radicals and acute inflammatory marker. Inflammopharmacology. 21:377-383.
- [22] Hamedi A, Rezaei H, Azarpira N, Jafarpour M, Ahmadi F. Effects of *Malva sylvestris* and its isolated polysaccharide on experimental ulcerative colitis in rats. J Evid Based Complementary Altern Med. 2016;21:14-22.
- [23] Surjushe A, Vasani R, Saple DG. Aloe vera: A short review. Indian J Dermatol. 2008;53:163-166.
- [24] Minaiyan M, Ghannadi A, Etemad M, Mahzouni P. A study of the effects of *Cydonia oblonga* Miller (Quince) on TNBS-induced ulcerative colitis in rats. Res Pharm Sci. 2012;7:103-110.
- [25] Rahimi R, Shams-Ardekani MR, Abdollahi M. A review of the efficacy of traditional Iranian medicine for inflammatory bowel disease. World J Gastroenterol. 2010;16:4504-514.
- [26] Minaiyan M, Asghari G, Taheri D, Saeidi M, Nasr-Esfahani S. Anti-inflammatory effect of *Moringa oleifera* Lam. seeds on acetic acid-induced acute colitis in rats. Avicenna J Phytomed. 2014;4:127-136.
- [27] Minaiyan M, Ghassemi-Dehkordi N, Mahzouni P, Ansari-Roknabady M. Effect of *Matricaria aurea* (Loefl.) Shultz-Bip. hydroalcoholic extract on acetic acid-induced acute colitis in rats. Iranian J Basic Med Sci. 2010;14:67-74.
- [28] Cooper HS, Murthy SN, Shah RS, Sedergran DJ. Clinicopathologic study of dextran sulfate sodium experimental murine colitis. Lab Invest. 1993;69:238-249.
- [29] Motaghi E, Hajhashemi V, Mahzouni P, Minaiyan M. The effect of memantine on trinitrobenzene sulfonic acid-induced ulcerative colitis in mice. Eur J Pharmacol. 2016;15;793:28-34.
- [30] Parikh NH, Kothari CS. Phytochemical analysis and total phenolic and flavonoid contents determination of methanolic extract of *Ocimum basilicum* L seed. Intern J PharmTech Res. 2016;9:215-219.
- [31] Rameshrad M, Salehian R, Fathiazad F, Hamedeyazdan S, Garjani M, Maleki-Dizaji N, et al. The effects of *Ocimum basilicum* ethanol extract on carrageenan induced paw inflammation in rats. Pharm Sci. 2015;20:149-156.
- [32] Gajula D, Verghese M, Boateng I, Shackelford L, Mentreddy SR, Sims C, et al. Basil (*Ocimum basilicum* and *Ocimum tenuiflorum*) reduces azoxymethane induced colon tumors in Fisher 344 male rats. Res J Phytochem. 2010;4:136-145.
- [33] Muthas D, Reznichenko A, Balendran CA, Böttcher G, Clausen IG, Kärrman Mardh C. et al. Neutrophils in ulcerative colitis: A review of selected biomarkers and their potential therapeutic implications. Scand J Gastroenterol. 2017;52:125-135.
- [34] Rai S, Ghosh H, and Basheer M. Phytochemical characterization and antioxidative property of *Ocimum canum*: Effect of ethanolic extract of leaves and seeds on basic immunologic and metabolic status of male rats. J Immuno Biol. 2016;1:1-7.
- [35] Parker H, Albrett AM, Kettle AJ, Winterbourn CC. Myeloperoxidase associated with neutrophil extracellular traps is active and mediates bacterial killing in the presence of hydrogen peroxide. J Leukoc Biol. 2012;91:369-376.

- [36] Balmus IM, Ciobica A, Trifan A, Stanciu C. The implications of oxidative stress and antioxidant therapies in inflammatory bowel disease: Clinical aspects and animal models. *Saudi J Gastroenterol.* 2016;22:3-17.
- [37] V VP, C G. Protective effect of marine mangrove *Rhizophora apiculata* on acetic acid induced experimental colitis by regulating anti-oxidant enzymes, inflammatory mediators and nuclear factor-kappa B subunits. *Int Immunopharmacol.* 2014;18:124-134.
- [38] Krawisz JE, Sharon P, Stenson WF. Quantitative assay for acute intestinal inflammation based on myeloperoxidase activity. *Gastroenterology.* 1984; 87:1344-1350.
- [39] Siddiqui BS, Aslam H, Ali ST, Begum S, Khatoon N. Two new triterpenoids and a steroidal glycoside from the aerial parts of *Ocimum basilicum*. *Chem Pharm Bull* 2007;55:516-519.
- [40] Strazzer P, Guzzo F, Levi M. Correlated accumulation of anthocyanins and rosmarini c acid in mechanically stressed red cell suspensions of basil (*Ocimum basilicum*). *J Plant Physiol.* 2011;168:288-293.
- [41] de Ca ´ssia da Silveira e Sa ´ R, Andrade LN, de Sousa DP. A review on anti-inflammatory activity of monoterpenes. *Molecules.* 2013;18:1227-1254.
- [42] Saeedi M, Morteza-Semnani K, Akbari J, Bazargani MH, Amin Gh. Evaluation of *Ocimum basilicum* L. seed mucilage as rate controlling matrix for sustained release of propranolol HCl. *Pharm Biomed Res.* 2015;1:18-25.
- [43] Razavi SAR, Bostan A, Rezaie M. Image processing and physico-mechanical properties of basil seed (*Ocimum basilicum*). *J Food Process Eng.* 2010;33:51-64.