

# Therapeutic Effect of *Ferulago angulata* Extract on Reproductive Parameters and serum testosterone levels in Diabetic Male Rats

Glavizh Rostami Nassab<sup>a</sup>, Somayeh Bohlouli<sup>b\*</sup>, Ali Ghanbari<sup>c\*\*</sup>

<sup>a</sup> Department of Biology, Hamedan branch, Islamic Azad University, Hamedan, Iran.

<sup>b</sup> Department of veterinary, College of Agriculture, Kermanshah Branch, Islamic Azad University, Kermanshah, Iran.

<sup>c</sup> Fertility and Infertility Research Center, Kermanshah University of Medical Sciences, Kermanshah, Iran.

## ARTICLE INFO

**Article Type:**  
Research Article

**Article History:**  
Received: 2017-08-15  
Revised: 2017-09-01  
Accepted: 2017-09-20  
ePublished: 2017-10-11

**Keywords:**  
Diabetes  
Ferulago Angulata  
Reproductive Parameters  
Rat

## ABSTRACT

Diabetes is an important metabolic disease inducing different effects on body organs, especially reproductive system. Increased oxidative stress and antioxidant capacity changed in diabetes induce infertility and decrease the sperm parameters. This study was to evaluate the therapeutic effects of hydro alcoholic extract of *Ferulago angulata* on reproductive parameters in diabetic male rats. In this experimental study, we used 30 male Wistar rats (230- 250g) with an average age of 10 weeks. A total of 24 rats were made diabetes type I by 40 mg/kg streptozotosin. Animals were divided into 5 groups of control, diabetic, and diabetic+ *Ferulago angulata* extract (100, 200 and 400mg/kg). Sperm parameters, serum testosterone level, seminiferous tubules diameter, and germ line epithelium maturity were assayed at the end of study. Data were analyzed by one-way ANOVA test and  $P < 0.05$  was considered statistically significant. Our results showed serum testosterone level and sperm parameters, including count, viability, progressive motility, and normal morphology as well as seminiferous tubules diameter and germ line epithelium maturity of diabetic male rats increased at 200 and 400 mg/kg doses of *Ferulago angulata* extract ( $P < 0.05$ ). The hydroalcoholic extract of *Ferulago angulata*, an herbal plant with abundant antioxidants, improved the quality of sperm and reproductive parameters in diabetic male rats.

\*Corresponding Author: Somayeh Bohlouli, E-mail: [sbohloli@yahoo.com](mailto:sbohloli@yahoo.com)

Co Corresponding Author: Ali Ghanbari, E-mail: [aghanbari@kmus.ac.ir](mailto:aghanbari@kmus.ac.ir)

Copyright © 2018 by Kermanshah University of Medical Sciences

## Introduction

Diabetes mellitus is a metabolic disorder which is induced by insulin production deficiency and is followed by chronic hyperglycemia. Diabetes mellitus induces damage to and failure of various organs in the body, especially the eyes, liver, kidneys, nerves, and heart [1]. Male reproductive system is also affected by diabetes mellitus. Decrease in testosterone production and sexual functions and reduction of seminiferous tubules diameter have been reported in diabetic patients [2]. Diabetes also influences spermatogenesis. Low quality of semen, including decreased sperm count and motility, and increased abnormal sperms has been reported in diabetic patients. Also body weight loss and epididymis shrinkage, which result in the decrease of head and body have been reported in diabetic rats [2, 3, 4]. During progression of diabetes mellitus, the altered metabolism of lipids, carbohydrates and proteins increase lipid peroxides and oxidative stress, leading to increase production of reactive oxygen species (ROS) [5]. Antioxidant capacity decreases in diabetes mellitus [6].

Many herbs are known to have anti-diabetic effects and are used to treat the patients. The main therapeutic mechanism of these medicinal plants for treatment of diabetes is inhibiting the free radicals. *Ferulago angulata* (locally known as Chavir) is a traditional herb in west of Iran. *F. angulata* has been used to treat digestive pains, hemorrhoids, snake bite, ulcers. It has also been used as a sedative in herbal medicine. Recently, the anti-tumor and antifungal effects of *Ferulago angulata* have been demonstrated by many authors, indicating that the plant is involved in the regulation of many molecular processes like apoptosis and angiogenesis [7]. Further, *Ferulago angulata*, as a natural antioxidant source, is used to reduce serum levels of total cholesterol, triglycerides, and LDL. It can also inhibit lipid peroxidation [8]. *F. angulata* is a strong antioxidant and can be used instead of synthetic antioxidant [9]. Administration of *Ferulago angulata* extract has a positive effect on immunological indices and

immune system activity in rainbow trout (*Oncorhynchus mykiss*) fingerling [10]. Considering the recent evidence supporting the antioxidant activity of *Ferulago angulata* and the role of oxidation in induction and progression of diabetes and its side effects on male reproductive system, this study was conducted to investigate the therapeutic effect of hydro alcoholic extract of *Ferulago angulata* on reproductive parameters in diabetic male rats.

## Materials and Methods

### Animals

Thirty male Wistar rats (230-250 g) were purchased from Pasture Institute (Tehran- Iran) and kept in the temperature of  $22 \pm 2^{\circ}\text{C}$  under controlled environmental conditions, 12/12 h light-dark cycle with free access to water and food for one week before the start of the experiment so that the animals could be adapted to the environment. The ethical committee of the university approved animal experiments in this study.

### Preparation of plant extract

*Ferulago angulata* was obtained from Dallaho Mountains in west of Kermanshah, Iran. The plant was identified and authenticated by Dr. Sharifi, assistant professor, Kermanshah Branch, Islamic Azad University, Kermanshah, Iran. *Ferulago angulata* leaves and stems dried and powdered. 200 g of powdered plant added to 400 cc 70% ethanol and were left to macerate at room temperature for 4 h. Then, the soaked plant were extracted by percolation method, it was removed from percolator, and filtered by Whatman filter paper (NO.4), then dried under reduced pressure at  $37^{\circ}\text{C}$  with rotator evaporator [10].

### Experimental design

To induce type I diabetes, 40 mg/kg streptozotocin (STZ) (USA Sigma Co.) was

dissolved in citrate buffer (0.1 M, pH=4.5). It was administered intraperitoneally in a single dose. Seven days after STZ administration, blood sample was collected from the tail of the rats and the serum was separated by centrifuge. The blood was assessed by spectrophotometer, and glucose level over 200 mg/dL was considered diabetic. Animals were divided into 5 groups: control, diabetic, and diabetic+ *Ferulago angulata* (100mg/kg, 200mg/kg, and 400mg/kg). Treatment groups with *Ferulago angulata* extract received different doses of the extract, and control and diabetic groups received normal saline intraperitoneally during the treatment. The rats were anesthetized. Blood was taken from the heart and its serum was separated by centrifuge. The serum samples were kept in freezer at -20°C. The serum testosterone level was determined by ELISA method [5]

### ***Semen analysis***

Cauda epididymis was separated and cut in DMEM/F12 containing 10% FBS and was put in incubator (37°C and 5% CO<sub>2</sub>) for thirty minutes. The prepared suspension was used for the analysis of sperm parameters, including motility, count, and morphology. Neubauer slide was used for counting the sperms. To count the sperms, after putting the sperm suspension on Neubauer's chamber, the sperm heads on the four corners of the central square were counted under a microscope and data were expressed as the number of sperm per ml. Smear was prepared from the samples to examine sperm morphology and was stained and analyzed by Papanicolaou test. Then, the testicles were removed and 5 µm histological sections were prepared from the paraffin blocks of left testes. The sections were stained by hematoxylin and eosin staining technique. About 100 tubules were evaluated in each animal to determine the maturity of germ line epithelium by ×20 objective lens, for which Johnson's score was used. The diameter of seminiferous tubules was also measured by Motic camera and software (AE-3; Motic S.L.C. Barcelona, Spain). The mean diameter of seminiferous tubules in micrometers was determined for each testis and examined by light microscopy at ×20 objective lens, totaling 200

seminiferous tubular cross-sections per animal [11, 12]. The testosterone levels were measured by inductive coupled plasma-optical emission spectroscopy (Perkin El-Mer, model 7300, USA) using specific ELISA kite (No; 55-TESMS-E01) for rat. The data of testosterone were expressed as ng/ml.

### ***Statistical analysis***

The data were presented as Mean± SD. One-way ANOVA was run for multiple groups comparisons followed by Turkey's test using SPSS software (version 20). P<0.05 was considered statistically significant.

### ***Results***

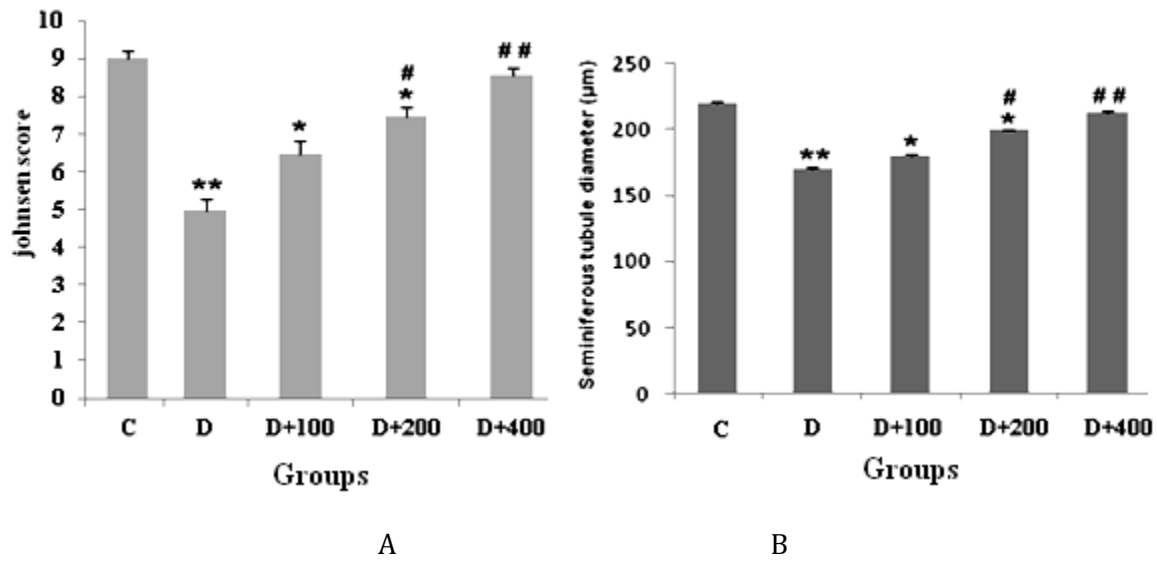
The data of serum testosterone levels and testis weight are shown in Table 1. The data of sperm parameters: sperm count and viability, high motility, and morphology (Normal) are shown in Table 2. There was a significant decrease in serum testosterone levels and testis weight in diabetic group compared with control group (P<0.05). Serum testosterone levels and testis weight were increased significantly in high doses of the extract (200 and 400mg/kg) in comparison with control and diabetic groups (p<0.001). There was a significant decrease in sperm parameters (count, motility, viability and morphology) in diabetic group compared with control group (P<0.05). In treatment groups, sperm parameters were also significantly increased in 200 and 400mg/kg doses in comparison to diabetic group (p<0.001). The data of seminiferous tubules diameter and Johnson's score are presented in figure 1 that are derived from photomicrograph of H&E staining (Fig 2). Seminiferous tubules diameter and Johnson's score were decreased in diabetic group compared to control group (P<0.001). These parameters were decreased in diabetic +100 and 200mg/kg extracts compared to control group (P<0.05). However, in diabetic and treatment groups, the seminiferous tubules diameter and Johnson's score were increased in diabetic+ 200mg/kg extract (P<0.05) and diabetic+ 400mg/kg extract (P<0.001) in comparison with diabetic group.

**Table 1.** The effect of hydro alcoholic extract of *Ferulago angulata* on testosterone hormone and testis weight (the data are indicated as Mean± SE). Significant differences are shown by \*P<0.05 and \*\* P<0.001 in comparison with control group.

PARAMETERS	GROUPS				
	Control	Diabetic	100mg/kg extract	200mg/kg extract	400mg/kg extract
Testosterone (ng/ml)	2.20±0.05	1.62 ± 0.00	1.67 ± 0.00	1.71 ± 0.01**	1.76 ± 0.00**
Testis weight(g)	1.25± 0.05	1.35 ± 0.01*	1.37 ± 0.01	1.42 ± 0.01**	1.46 ± 0.03**

**Table 2.** The effect of hydro alcoholic extract of *Ferulago angulata* on sperm parameters, including sperm count, viability, motility and normal morphology of male rats (the data are indicated as Mean± SE). Significant differences are shown by \*P<0.05 and \*\* P<0.001 in comparison with control group.

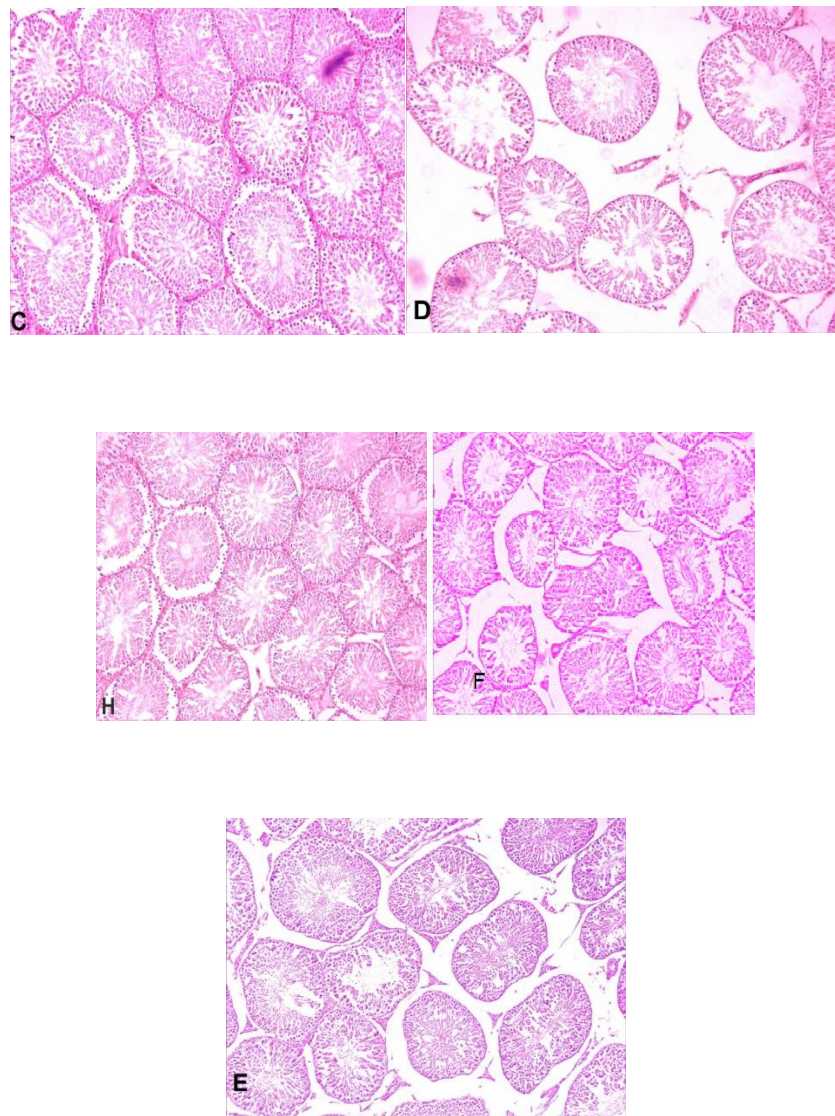
Parameters	Groups				
	Control	Diabetic	100mg/kg extract	200mg/kg extract	400mg/kg extract
Sperm count (×10 <sup>6</sup> )	76.33± 1.498	36.33 ± 1.476*	40.17 ± 1.195	48.00 ± 1.065**	53.50 ± 1.522**
High motility (%)	57.50 ± 2.187	24.83 ± 1.138*	29.00 ± 3.225	34.33 ± 3.502**	42.50 ± 2.168**
Viability (%)	80.83 ± 2.088	55.67 ± 0.601*	58.17 ± 1.155	65.00 ± 1.195**	70.17 ± 1.283**
Morphology (Normal %)	71.33±1.145	32.83 ± 0.946*	36.50 ± 0.992	38.50 ± 0.992**	47.00 ± 0.966**



**Fig. 1.** The effect of hydro alcoholic extract of *Ferulago angulata* on seminiferous tubules diameter and germ line epithelium maturity of rats. The study groups included C: control, D: Diabetic, D+100mg/kg extract, D+200, and Diabetic+ 400mg/kg extract.

\*\* P<0.001, \*P<0.05: Statistical difference between control and experimental groups.

## P<0.001, #P<0.05: Statistical difference between diabetic and other experimental groups.



**Fig. 2.** Photomicrograph of seminiferous tubules after treatment with hydro alcoholic extract of *Ferulago angulata* of rats. The study groups included C: control, D: Diabetic, E: D+100mg/kg extract, F: D+200. G: Diabetic+ 400mg/kg extract, and H: D+400: Diabetic+ 400mg/kg extract. Photos represent X200 magnification, H&E staining.

## Discussion

The current study evaluated the effect of hydro alcoholic extract of *Ferulago angulata* on reproductive parameters in diabetic male rats. *Ferulago angulata* extract were effect in reproductive parameters in male rats. Our data in this study indicated that hydro alcoholic extract of *Ferulago angulata* significantly increased serum testosterone level, sperm parameters, including

count, viability, progressive motility and normal morphology as well as seminiferous tubules diameter and germ line epithelium maturity of diabetic male rats. Intraperitoneal injection of *Ferulago angulata* extract (200 and 400mg/kg) to the diabetic male rats increased the sperm count and viability significantly compared with non-diabetic male rats. Also, significant improvement was seen in the morphology and motility of the groups treated with extract (diabetic groups) in

comparison with non-diabetic group. Lack of insulin leads to damage to the body systems, especially reproductive system. Diabetes has negative effects on the fertility of STZ-injected male rats. These abnormalities could be characterized by decrease in seminal volume, sperm density, and motility. Significant decrease was observed in Johnsen's scores and seminiferous tubules diameter of diabetic groups. Cameron et al. showed that diabetes caused atrophy of tubules and reduced spermatogenic cells, which could be considered as signs of morphological abnormalities in spermatogenesis [13]. Diabetes-induced oxidative stress has been reported to cause the atrophy of tubules, being observed as reduced diameter of tubules and loss of spermatogenic cells [14]. *Ferulago angulata* is an herbal plant in the west of Iran that belongs to the Apiaceae (Umbelliferae) family. The plant has antioxidant compounds, including flavonoids, Coumarin, and Sesquiterpene [15]. *Conium maculatum* and *Coriandrum sativum* are belongs Umbelliferae family with Anti-Diabetes Activity used in Traditional Persian Medicine [16]. Flavonoids like Quercetin have been indicated to have antioxidant effects. Quercetin administration improves the testicular impairments such as decreased sperm count, motility and viability in STZ-induced diabetic rats [17]. One study reported that flavonoids and saponine compounds of *Tribulus terrestris* could improve the quality of semen and increase the number and motility of sperms in cock [18]. Another study showed that antioxidant compounds of flavonoids in *Cirsium vulgare* increased the motility and serum testosterone level [19]. These results are in parallel with the findings of our study. It has also been shown that serum testosterone levels and seminiferous tubules diameter reduce in diabetic rats [5]. STZ can disturb the Leydig cell function and reduce serum testosterone level, especially at higher dosage [20].

## Conclusions

In the present study, we assayed the serum testosterone levels. There was a significant increase in serum testosterone levels, indicating a significant difference between control (non-diabetic) and diabetic groups treated with different doses of *Ferulago angulata* extract, especially at higher dose (400mg/kg) of extract. *Dorema aucheri* extract with flavonoid compounds significantly increased serum testosterone level in low dose (100mg/kg) but significantly decreased it in 200 and 400mg/kg in rat [21]. It can be concluded that *Ferulago angulata* extract has therapeutic effects in high doses (200, 400mg/kg) and increases serum testosterone levels, sperm parameters, and histological features of testis tissue in diabetic male rats. Antioxidant compounds in *Ferulago angulata*, an herbal plant living in the west of Iran, can be used to induce such effects. The present study introduces *Ferulago angulata* to improve the side effects of diabetes on male reproductive system.

## Acknowledgements

This article was financially supported by the authors from Hamedan Branch, Islamic Azad University, Hamedan, Iran and Kermanshah Branch, Islamic Azad University, Kermanshah, Iran.

## Conflict of interest

Authors certify that there is no actual or potential conflict of interest in relation to this article.

## References

- [1] Tharkar S, Devarajan A, Kumpatla S, Viswanathan V. The socioeconomics of diabetes from a developing country: a population based cost of illness study. *Diabetes Res Clin Pract.*2010; 89: 334-340.
- [2] Guneli E, Tugyan K, Ozturk H, Gumustekin M, Cilaker S, Uysal N. Effect of melatonin on testicular

damage in streptozotocin-induced diabetes rats. *Eur Surg Res.*2008; 40: 354-360.

[3] Kim ST, Moley KH. Paternal effect on embryo quality in diabetic mice is related to poor sperm quality and associated with decreased glucose transporter expression. *Reproduction.*2008; 136: 313-322.

[4] Scarano WR, Messias AG, Oliva SU, Klinefelter GR, Kempinas WG. Sexual behavior, sperm quantity and quality after short-term streptozotocin-induced hyperglycemia in rats. *Int J Andro.*2006; 29: 482-488.

[5] Lotfi N, Khazaei M, Shariatzadeh SMA, Malek Solmani Mehranjani M, Piri F, Ansarian A. Reproductive Parameters in Diabetic Male Rat after Exposure to Cannabis Sativa Hydroalcoholic Extract. *J. Rep. Pharm. Sci.*2014; 3:193-200.

[6] Alekseev IB, Kochergin SA, Vorob'eva IV, Mikhaleva LG. On some pathogenic features of diabetic retinopathy in type II diabetes mellitus and the role of antioxidants and ginkgo biloba. *Vestn Oftalmol.*2013; 129: 89-93.

[7] Heidari S, Akrami H, Gharaei R, Jalili A, Mahdiuni H, Golezar E. Anti-tumor Activity of *Ferulago angulata* Boiss: Extract in Gastric Cancer Cell Line via Induction of Apoptosis. *Iran J Pharm Res.*2014; 13: 1335-1345.

[8] Rafieian-Kopaei M, Shahinfard N, Rouhi-Boroujeni H, Gharipour M, Darvishzadeh-Boroujeni P. Effects of *Ferulago angulata* Extract on Serum Lipids and Lipid Peroxidation. *Evid Based Complement Alternat Med.* 2014; 680856. doi: 10.1155/2014/680856.

[9] Sadeghi E, Mahtabani A, A Etminan A, Karami F. Stabilization of soybean oil during accelerated storage by essential oil of *Ferulago angulata* Boiss. *Int J Food Sci Tech.*2016; 53: 1199-1204.

[10] Bohlouli S, Sadeghi E. Growth performance and haematological and immunological indices of rainbow trout (*Oncorhynchus mykiss*) fingerlings supplemented with dietary *Ferulago angulata* (Schlecht) Boiss. *Acta Vet Brno.*2016; 85: 231-238.

[11] Moradi M, Mahmoodi M, Raofi A, Ghanbari A. Chorionic morphine, naltrexone and pentoxifylline effect on hypophyso-gonadal hormones of male rats. *Bratisl Lek Listy.*2015; 116: 276-279.

[12] Hamidi M, Ziaee M, Delashoub M, Marjani M, Karimitabar F, Khorami A, Ahmadi NA. The Effects of Essential Oil of *Lavandula Angustifolia* on Sperm Parameters Quality and Reproductive Hormones in Rats Exposed to Cadmium. *J. Rep. Pharm. Sci.*2015; 4: 121-128.

[13] Shayakhmetova GM, Bondarenko LB, Matvienko AV, Kovalenko VM. Correlation between spermatogenesis disorders and rat testes CYP2E1 mRNA contents under experimental alcoholism or type I diabetes. *Adv Med Sci.*2014; 59:183-189

[14] Orman D, Vardi N, Ates B, Taslidere E, Elbe H. Aminoguanidine mitigates apoptosis, testicular seminiferous tubules damage, and oxidative stress in streptozotocin-induced diabetic rats. *Tissue Cell.*2015; 47:284-90.

[15] Hosseini N, Akbari M, Ghafarzadegan R, Changizi Ashtiyani S, Shah Mohammadi R. Total Phenol, Antioxidant and Antibacterial Activity of the Essential Oil and Extracts of *Ferulago angulata* ssp. *Angulata*. *J Med Plant.* 2012; 11: 80-89.

[16] Farzaei F, Morovati MR, Farjadmand F, Farzaei MH. A Mechanistic Review on Medicinal Plants Used for Diabetes Mellitus in Traditional Persian Medicine. *J Evid Based Complementary Altern Med.*2017; 1:1-12.

[17] Khaki A, Nouri M, Fathiazade F, Ahmadi-Ashtiani HR, Rastgar H, Rezazadeh Sh. Protective Effects of Quercetin on Spermatogenesis in Streptozotocin- Induced Diabetic Rat. *J Med Plant.* 2009; 8: 57- 64.

[18] Grigorova S, Kashamov B, Sredkova V, Surdjiiska S, Zlatev H. Effect of *Tribulus Terrestris* Extract on Semen Quality and Serum Total Cholesterol Content in White Plymouth Rock- mini Cocks. *Biotechnol. Anim. Husan.*2008; 24: 139-146.

[19] Tabibian M, nasri S, krishchi P, Amin GH. The effect of *Gundelia tournefortii* hydroalcoholic extract on sperm parameters and testosterone concentration in mice. *ZJRMS.*2013; 15:18-21.

[20] Stanciu C, Abboud I, Kellman A, Williams D, Azad N. Correlation of Aging and Body Mass Index with the Hypothalamic- Pituitary- Gonadal Axis Hormones in Men, with Diabetes Mellitus. *The Open Androl.*2010; 5: 6- 10.

[21] Azarneoshan F, Khatam Saz S, Sadeghi H. The Effects of Hydro Alcoholic Extract of *Dorema Aucheri* on Blood Concentration of Gonadotropin and Androgen Hormones in Adult Male Rats. *Armaghane danesh.*2009; 14:63-68.