




Becker's Nevus with Lichen Simplex Chronicus Limited to the Nevus Lesion: A Case Report

Samer Mriani¹, Bandar Tammar¹, Hasan Maghrabi¹, Khalid Al About ^{2,*}, Waleed Yamani², Zaher Al Asmary², Hamdan Al Osaimi², Hasan Al Qurashi², Adnan Al Ehibi², Faisal Alfeliyet², Awatif Al Subyani², Hanan Barnawi², Ahlam Al Hakami² and Saleh Al Muntashiri³

¹Department of Administration, King Faisal Hospital, Makkah, Saudi Arabia

²Department of Dermatology and Public Health, King Faisal Hospital, Makkah, Saudi Arabia

³Alkhadra Primar Care Center, Makkah, Saudi Arabia

*Corresponding author: Department of Dermatology and Public Health, King Faisal Hospital, P. O. Box 5440, Makkah, Saudi Arabia. Email: amoa65@hotmail.com

Received 2019 October 02; Revised 2019 December 28; Accepted 2020 January 01.

Abstract

Becker's nevus is an uncommon hamartomatous skin lesion. Many dermatoses and, rarely, abnormal systemic findings have been reported in association with Becker's nevus. The occurrence of lichen simplex chronicus (LSC) is rare in Becker's nevus. In this case report, we share our observation of a 23-year-old Bengali male with LSC in association with Becker's nevus.

Keywords: Disease, Nevus, Skin

1. Introduction

Becker's nevus is a hamartomatous hyperpigmented patch, first reported in 1948 by an American dermatologist, Samuel William Becker (1894 - 1964) (1). Several dermatoses have been reported in association with Becker's nevus. Box 1 shows a select list of these skin conditions (1-8).

Box 1. Selected Skin Conditions Reported in Association With Becker's Nevus, Listed Alphabetically

Skin Conditions
Acne
Desmoid tumor
Eczema
Hypohidrosis
Leiomyoma cutis
Lichen planus
Lymphomatoid papulosis
Plexiform neurofibroma
Prurigo nodularis
Scleroderma

Systemic abnormalities, such as ipsilateral limb shortening and breast hypoplasia, can also occur with this nevus

(9). Lichen simplex is a localized area of chronic, lichenified eczema/dermatitis. There can be a single plaque or multiple plaques. It is also called neurodermatitis (10).

To our knowledge, the co-occurrence of LSC with Becker's nevus has not been reported. We share our observation of a young man with LSC limited to Becker's nevus.

2. Case Presentation

A 23-year-old healthy Bengali male, working as a cleaner, presented with pruritic lichenified papules in a dark spot on his left forearm persisting for several weeks (Figure 1). He had no known medical problems and was not on any medication. He had noted the dark hyperpigmentation and the increased hairiness of this patch since late childhood. He was diagnosed with Becker's nevus. Several months ago, he developed severe scratching that was limited to this patch, but he received no treatment for this itchiness.

There were no other skin lesions. A 4-mm punch biopsy (performed after obtaining informed consent from the patient) from a pruritic papule demonstrated thick hyperkeratosis and epidermal acanthosis, which were consistent with the clinical diagnosis of LSC. The patient was managed with a psychodermatological approach. He was advised to

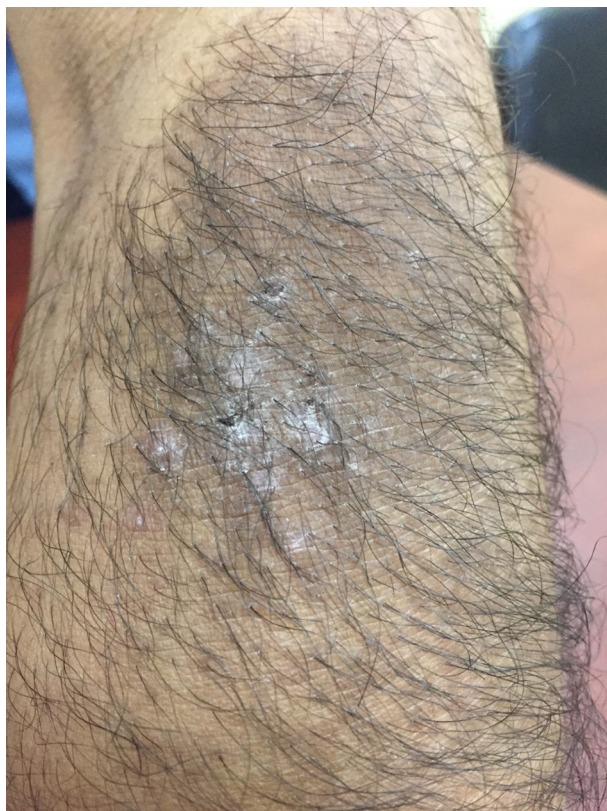

Figure 1. Lichenified papules of lichen simplex chronicus occurring in Becker's nevus

trim his nails, avoid scratching, distract his attention to the lesion, and avoid stresses in general.

He was prescribed a two-week course of topical betamethasone 1% ointment to be applied twice daily, and chlorpheniramine maleate (Histop) as a 4-mg tablet to be taken orally three times daily. He is being followed up clinically, but he has not visited the clinic.

3. Discussion

Various hypotheses and pathological mechanisms have been discussed to explain the occurrence of coexisting abnormalities in Becker's nevus (2). For instance, an increase in androgen receptors in Becker's nevus might contribute to the development of acneiform eruption and breast hypoplasia. Hypohidrosis that colocalizes with Becker's nevus is considered to be related to genetic mutation or mosaicism (2).

Wolf's isotopic response, which is the occurrence of a new unrelated disease at the same location as a previously healed disease, was also considered as a possible explana-

tion. Because underlying Becker's nevus lesion continues to exist, several groups believe that this association of dermatoses with Becker's nevus is not exactly consistent with the definition of Wolf's isotopic response. Thus, they feel that Wolf's isotopic response-like phenomenon is a better term (2).

As a chronic skin condition, LSC is linked to emotional factors that are the sources of intense pruritic sensation (10). That pruritic lesions in our case were recurrent and always localized to the hyperpigmented patch suggests that the coexistence of these two conditions is more than a mere coincidence. Nonetheless, we could not verify the exact cause of the association of LSC with Becker's nevus in our case. However, as a possibility, anxiety generated by the shape of the nevus precipitated the LSC. The abnormal neural component of the hamartomatous lesion of Becker's nevus might be another factor in the development of LSC.

Footnotes

Authors' Contribution: All the authors (Samer Mriani, Bandar Tammar, Hasan Maghrabi, Khalid Al Aboud, Waleed Yamani, Zaher Al Asmary, Hamdan Al Osaimi, Hasan Al Qurashi, Adnan Al Ehibi, Faisal Alfeliyet, Awatif Al Subyani, Hanan Barnawi, Ahlam Al Hakami, and Saleh Al Muntashiri) have contributed equally to all parts of the article.

Conflict of Interests: All the authors have no conflict of interests in this submission.

Funding/Support: None of the authors received any funds for this submission.

Informed Consent: Written informed consent was obtained from the patient.

References

1. Santos-Juanes J, Galache C, Curto JR, Carrasco MP, Ribas A, Sanchez del Rio J. Acneiform lesions in Becker's nevus and breast hypoplasia. *Int J Dermatol.* 2002;**41**(10):699-700. doi: [10.1046/j.1365-4362.2002.01393-2.x](https://doi.org/10.1046/j.1365-4362.2002.01393-2.x). [PubMed: [12390199](https://pubmed.ncbi.nlm.nih.gov/12390199/)].
2. Lee JS, Park HS, Yoon HS, Cho S. Becker's nevus with recurrent eczema limited to the nevus lesion. *Ann Dermatol.* 2018;**30**(1):83-6. doi: [10.5021/ad.2018.30.1.83](https://doi.org/10.5021/ad.2018.30.1.83). [PubMed: [29386838](https://pubmed.ncbi.nlm.nih.gov/29386838/)]. [PubMed Central: [PMC5762483](https://pubmed.ncbi.nlm.nih.gov/PMC5762483/)].
3. Lee DJ, Kang HY. Eczema confined to Becker's nevus on the Face: The behavior of melanocytes during inflammation. *Ann Dermatol.* 2012;**24**(1):99-100. doi: [10.5021/ad.2012.24.1.99](https://doi.org/10.5021/ad.2012.24.1.99). [PubMed: [22363167](https://pubmed.ncbi.nlm.nih.gov/22363167/)]. [PubMed Central: [PMC3283863](https://pubmed.ncbi.nlm.nih.gov/PMC3283863/)].
4. Sciallis GF, Sciallis AP. Becker nevus with an underlying desmoid tumor: a case report and review including Mayo Clinic's experience. *Arch Dermatol.* 2010;**146**(12):1408-12. doi: [10.1001/archdermatol.2010.369](https://doi.org/10.1001/archdermatol.2010.369). [PubMed: [21173323](https://pubmed.ncbi.nlm.nih.gov/21173323/)].
5. Do JE, Kim YJ, Kang HY. Hypohidrosis colocalized with Becker's naevus. *Br J Dermatol.* 2007;**156**(4):766-7. doi: [10.1111/j.1365-2133.2006.07723.x](https://doi.org/10.1111/j.1365-2133.2006.07723.x). [PubMed: [17263814](https://pubmed.ncbi.nlm.nih.gov/17263814/)].

6. Terheyden P, Hornschuh B, Karl S, Becker JC, Bröcker EB. Lichen planus associated with Becker's nevus. *J Am Acad Dermatol.* 1998;**38**(5):770-2. doi: [10.1016/s0190-9622\(98\)70211-7](https://doi.org/10.1016/s0190-9622(98)70211-7).
7. Buder K, Wendel AM, Cerroni L, Goebeler M, Kerstan A. A case of lymphomatoid papulosis limited to Becker's melanosis. *Dermatology.* 2013;**226**(2):124-7. doi: [10.1159/000346752](https://doi.org/10.1159/000346752). [PubMed: [23548991](https://pubmed.ncbi.nlm.nih.gov/23548991/)].
8. Lockshin BN, Brogan B, Billings S. Eczematous dermatitis and prurigo nodularis confined to a Becker's nevus. *Int J Dermatol.* 2006;**45**(12):1465-6. doi: [10.1111/j.1365-4632.2006.02971.x](https://doi.org/10.1111/j.1365-4632.2006.02971.x). [PubMed: [17184268](https://pubmed.ncbi.nlm.nih.gov/17184268/)].
9. Glinick SE, Alper JC, Bogaars H, Brown JA. Becker's melanosis: Associated abnormalities. *J Am Acad Dermatol.* 1983;**9**(4):509-14. doi: [10.1016/s0190-9622\(83\)70161-1](https://doi.org/10.1016/s0190-9622(83)70161-1).
10. Voicu C, Tebeica T, Zanardelli M, Mangarov H, Lotti T, Wollina U, et al. Lichen simplex chronicus as an essential part of the dermatologic masquerade. *Open Access Maced J Med Sci.* 2017;**5**(4):556-7. doi: [10.3889/oamjms.2017.133](https://doi.org/10.3889/oamjms.2017.133). [PubMed: [28785363](https://pubmed.ncbi.nlm.nih.gov/28785363/)]. [PubMed Central: [PMC5535688](https://pubmed.ncbi.nlm.nih.gov/PMC5535688/)].