Uncorrected Proof

Multidiscip Cardio Annal. 2024 January; 15(1): e142048. https://doi.org/10.5812/mca-142048.

Published online: 2024 March 16. **Case Report**

ECG Changes in a Young Lady Candidate for In Vitro Fertilization Due to Left Ventricular Hemangioma

Azin Alizadehasl [1], Pegah Salehi [2], Masoud Sayad [1], Alia Bahramnejad [1,*], Azam Yalameh [1], Mina Mohseni [1], Amir Dousti [3]

[1] Cardio-Oncology Research Center, Rajaie Cardiovascular Medical and Research Center, Iran University of Medical Sciences, Tehran, Iran
[2] Echocardiography Research Center, Rajaie Cardiovascular Medical and Research Center, Iran University of Medical Sciences, Tehran, Iran
[3] Interventional Cardiology Research Center, Rajaie Cardiovascular Medical and Research Center, Iran University of Medical Sciences, Tehran, Iran

[*] *Corresponding author:* Cardio-Oncology Research Center, Rajaie Cardiovascular Medical and Research Center, Iran University of Medical Sciences, Tehran, Iran. Email: aaly_brnj@yahoo.com

Received 2023 October 14; **Accepted** 2023 October 16.

Abstract

Cardiac hemangioma is a rare cardiac tumor which may have a spectrum of signs and symptoms; here we would like to present a case of asymptomatic cardiac hemangioma that was discovered by an ECG.

Keywords: Cardiac Neoplasm, Cavernous Hemangioma, Benign Tumor

1. Introduction

Cardiac hemangioma was an extremely rare cardiac tumor. Previous research found hemangioma in only 2.8% of all primary heart tumors, with women being somewhat more affected than males (1); in around one-third of instances, it is found in the right ventricle. One-third of the instances were documented in the left ventricle, 23% in the right atrium chamber, and 7% in the left atrium chamber (2).

According to vascular classification in pathology, hemangiomas are categorized as follows: 1. Cavernous tumor 2. arteriovascular tumor 3. Capillary and 4. mixed type (2, 3).

Hemangioma symptoms include outflow tract obstruction, arterial compression, cardiac dysrhythmias, embolization, syncope, and sometimes rapid death in the first presentation, among others. Depending on the anatomical location and size of the tumor (3-6) due to the vascular nature and hemodynamic consequences of hemangioma surgery, the course is very unpredictable and surgery is only recommended for symptomatic cases (7).

2. Case Presentation

A 26-year-old woman, who was a candidate for in vitro fertilization (IVF) due to infertility, referred to the cardiology clinic for permission to perform the procedure. According to the changes in the electrocardiogram (ECG), the patient was referred for echocardiography. The patient was clinically asymptomatic and the physical examination was normal (Figure 1).

Copyright © 2024, Multidisciplinary Cardiovascular Annals. This open-access article is available under the Creative Commons Attribution-NonCommercial 4.0 (CC BY-NC 4.0) International License (https://creativecommons.org/licenses/by-nc/4.0/), which allows for the copying and redistribution of the material only for noncommercial purposes, provided that the original work is properly cited.

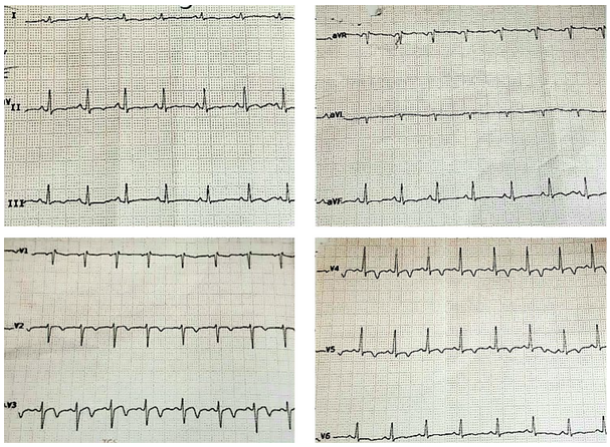

Figure 1. Electrocardiogram (ECG) showed normal sinus rhythm, sinus tachycardia, narrow QRS, ST depression and T inversion in II, III, avF, biphasic T waves in V2 - V5.

Transthoracic and transesophageal echocardiography revealed normal LV size with minor LV systolic dysfunction (EF = 50%), adequate contractility of the LV base and mid, but mildly impaired contractility of the LV at the site of LV mass. A large hyperechoic and encapsulated vascular mass (3.5 × 2.4 cm) without mobility was seen in the left ventricle in the apicoanterior segment. The mass had resulted in left ventricular apical hypokinesia (Figures 2 and 3).

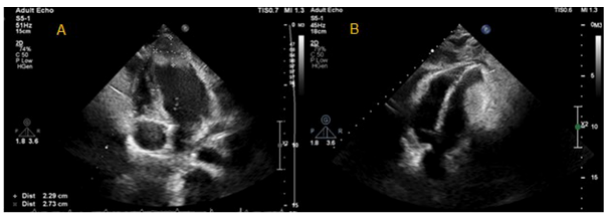

Figure 2. Transthoracic echocardiography. large hyperechoic and encapsulated vascular mass (3.5 × 2.4 cm) without mobility was seen in the left ventricle in the apicoanterior segment.

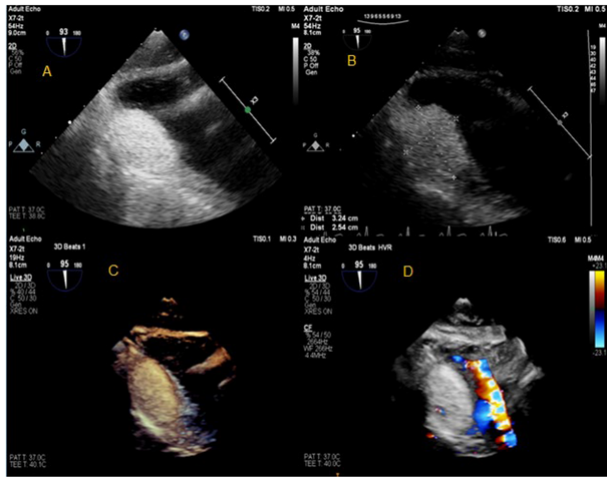

Figure 3. Transesophageal echocardiography. Large hyperechoic and encapsulated vascular mass (3.5 × 2.4 cm) without mobility was seen in the left ventricle in the apicoanterior segment.

Cardiac magnetic resonance imaging (cardiac MRI) showed normal LV and RV size and function. A large mass lesion is seen in the LV apex. In the STIR/T2 weighted-sequences, the mass is ISO to high intention. In the T1 weighted-sequences with fat suppression images, the mass is ISO signal. The mass has avid perfusion during the first pass perfusion sequence. The mass is enhanced with early-enhancement imaging. The mass has been enhanced in the late-enhancement sequences. Due to MRI tissue characterization criteria: cardiac hemangioma is the most probable diagnosis (Figures 4 and 5)

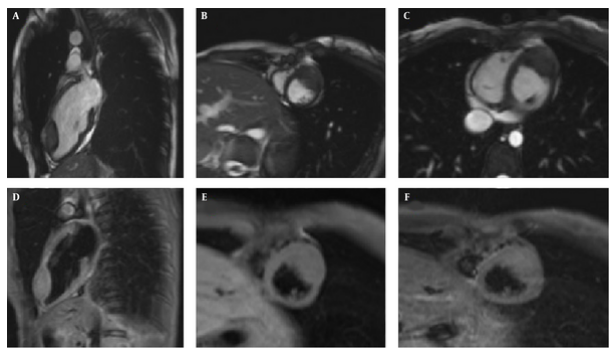

Figure 4. Cardiac magnetic resonance imaging (cardiac MRI). A - C: 2 ch LV, short axis and axial SSFP sequence show iso-signal intensity mass at the apex of LV. D - F: 2 ch LV and Short axis STIR sequence show high signal intensity mass at the apex of LV.

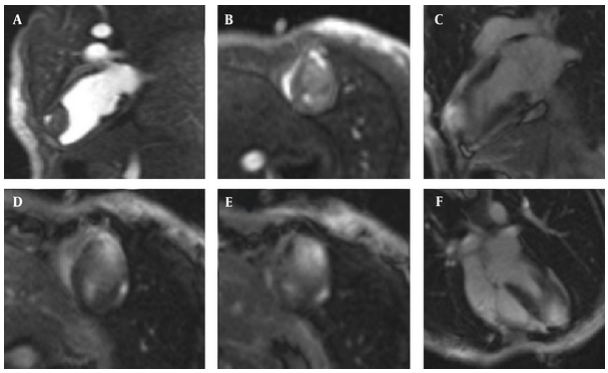

Figure 5. A and B: 2 ch LV and short axis early first pass perfusion sequence shows a portion of tumor rapidly enhance. C - F: 2 ch LV, short axis and 4 ch LV LGE sequence show intense enhancement of the LV apex mass.

According to the evidence of cardiac hemangioma in cardiac MRI, the patient was discharged and allowed to undergo IVF.

3. Discussion

Hemangioma is caused by hyperplasia of the endothelium of blood vessels, including arterioles, tiny veins, and capillaries, and it can arise from all three layers of the endocardium, myocardium, and epicardium of the heart, but it is usually benign (2).

Imaging modalities, which include ECG and echocardiography as initial diagnostic evaluations and further computed tomography (CT), CMR, and angiography evaluations, are an essential element of its diagnosis process (8).

Some examples of ECG alterations in hemangioma have been described, which are often cases of intramuscular hemangioma and vary depending on the location of the hemangioma. For instance, in another case of hemangioma in the left ventricular apicoseptal region, the changes were in the form of T-inversion in the anterior and lateral leads (9).

In addition, echocardiography has a diagnostic accuracy of 81% for the diagnosis of cardiac tumors (8).

Ct is generally used for CMR contraindication where the mass appears as a hyper-enhanced lesion due to hyper vascularity.

Coronary angiography is seldom used for the diagnosis of hemangioma because of the appearance of tumor blush and determination of blood supply of the tumor (9, 10).

CMR plays an important role in diagnostic of hemangioma and the characteristics of signal intensity include iso-signal or hyper-signal of the mass in T1-weighted or T2-weighted imaging and rapid enhancement during the first pass-phase after gadolinium injection, indicating the high vasculature nature of the mass in favor of hemangioma, as in our patient, CMR findings were strongly in favor of hemangioma, including: In the STIR/T2 weighted-sequences, the mass is iso to high intention. In the T1 weighted-sequences with fat suppression images, the mass is iso-signal.

In the first pass perfusion sequence, the mass has an avid perfusion. And also in the early and late enhancement sequence, the mass shows enhancement.

Other tumors, however, such as pheochromocytoma, angiosarcoma, myxoma, and rhabdomyosarcoma, exhibit similar characteristics in CMR and can be identified from one another based on the patient's age, clinical manifestation, and tumor site. In addition, tumor mobility is assessed in steady-state free precession (SSFP). Therefore, according to previous studies, hemangioma can be diagnosed with CMR alone or together with other imaging methods Such as CT, echocardiography and angiography (11-13).

The natural course of hemangioma is very variable and it may be nested, stop growing or multiply. Surgery should be conducted if there are symptoms or if the diagnosis is questionable concerning the type of the tumor. Also, tumor recurrence after surgery has been reported, so follow up is required (14).

Medical treatment with radiation or corticosteroids and interferon alpha, as well as some anti-cancer drugs such as vincristine, cyclophosphamide, rapamycin, and bevacizumab, are among the treatment options for hemangioma, but the data is obviously insufficient and has not been supported by controlled studies (5, 15-17).

Since our patient was asymptomatic, a conservative management was decided upon and the patient was closely followed to inspect for symptoms and indication of surgical treatment.

Footnotes

Authors' Contribution: Study concept and design: Pegah Salehi; acquisition of data: Mina Mohseni; analysis and interpretation of data: Azam Yalameh; drafting of the manuscript: Alia Bahramnejad; critical revision of the manuscript for important intellectual content: Amir Dousti; administrative, technical, and material support: Masoud Sayad; study supervision: Azin Alizadehasl.

Conflict of Interests: The authors reported no conflicts of interests.

Data Availability: The dataset presented in the study is available on request from the corresponding author during submission or after publication. The data are not publicly available due to patient's privacy.

Ethical Approval: This study was approved by our ethical committee. We accepted/committed/considered all rights/rules/regulations of the Helsinki Protocol in our study.

Funding/Support: There was no funding.

Informed Consent: It has not been declared by the authors.

References

1. Miao H, Yang W, Zhou M, Zhu Q, Jiang Z. Atrial Hemangioma: A Case Report and Review of the Literature. *Ann Thorac Cardiovasc Surg*. 2019;**25**(2):71-81. [PubMed ID: 30890668]. [PubMed Central ID: PMC6477455]. https://doi.org/10.5761/atcs.ra.18-00207.
2. Abuharb MYI, Bian XM, He J. Epicardial cardiac cavernous Haemangioma-a case report. *BMC Cardiovasc Disord*. 2019;**19**(1):179. [PubMed ID: 31357944]. [PubMed Central ID: PMC6664696]. https://doi.org/10.1186/s12872-019-1156-6.
3. Yusuf SW, Reardon MJ, Banchs J. Cardiac tumors. *Cardiology*. 2014;**129**(3):197-8. [PubMed ID: 25341877]. https://doi.org/10.1159/000368074.
4. Wang Y, Liu S, Yang J, Gu T, Zhang L. Cardiac hemangioma caused ventricular arrhythmia: A rare case and literature review. *J Electrocardiol*. 2017;**50**(5):667-70. [PubMed ID: 28506600]. https://doi.org/10.1016/j.jelectrocard.2017.04.014.
5. Li W, Teng P, Xu H, Ma L, Ni Y. Cardiac Hemangioma: A Comprehensive Analysis of 200 Cases. *Ann Thorac Surg*. 2015;**99**(6):2246-52. [PubMed ID: 25921258]. https://doi.org/10.1016/j.athoracsur.2015.02.064.
6. Parkash O, Ying GW, Ram A, Vemireddy LP, Zahra F. A Rare Case of Cavernous Hemangioma of the Mitral Valve Presenting As Multifocal Embolic Brain Infarcts. *Cureus*. 2021. https://doi.org/10.7759/cureus.17721.
7. Aletaha M, Salour H, Bagheri A, Raffati N, Amouhashemi N. Oral propranolol for treatment of pediatric capillary hemangiomas. *Journal of ophthalmic & vision research*. 2012;**7**(2):130.
8. Esmaeilzadeh M, Jalalian R, Maleki M, Givtaj N, Mozaffari K, Parsaee M. Cardiac cavernous hemangioma. *Eur J Echocardiogr*. 2007;**8**(6):487-9. [PubMed ID: 16935564]. https://doi.org/10.1016/j.euje.2006.07.004.
9. Al Umairi RS, Sabek S. Left Ventricle Intramuscular Haemangioma: A case report and review of literature. *Sultan Qaboos Univ Med J*. 2021;**21**(2):e316-9. [PubMed ID: 34221483]. [PubMed Central ID: PMC8219323]. https://doi.org/10.18295/squmj.2021.21.02.024.
10. Cresti A, Chiavarelli M, Munezero Butorano MAG, Franci L. Multimodality Imaging of a Silent Cardiac Hemangioma. *J Cardiovasc Echogr*. 2015;**25**(1):31-3. [PubMed ID: 28465926]. [PubMed Central ID: PMC5353457]. https://doi.org/10.4103/2211-4122.158427.
11. Moniotte S, Geva T, Perez-Atayde A, Fulton DR, Pigula FA, Powell AJ. Images in cardiovascular medicine. Cardiac hemangioma. *Circulation*. 2005;**112**(8):e103-4. [PubMed ID: 16116060]. https://doi.org/10.1161/CIRCULATIONAHA.104.487645.
12. Alizadehasl A, Maleki M. Echocardiography in benign cardiac tumors (diagnosis, approach, and follow-up). *Multimodal Imaging Atlas of Cardiac Masses*. 2023. p. 101-29. https://doi.org/10.1016/b978-0-323-84906-7.00012-1.
13. Liu Y, Maureira P, Selton-Suty C, Folliguet T, Marie PY, Mandry D, et al. Small cardiac hemangioma: a challenge for diagnosis and dilemma for management. *Ann Thorac Surg*. 2014;**97**(1):e11-3. [PubMed ID: 24384214]. https://doi.org/10.1016/j.athoracsur.2013.07.104.
14. Gribaa R, Slim M, Neffati E, Boughzela E. Conservative Management of Cardiac Hemangioma for 11 Years. *Tex Heart Inst J*. 2015;**42**(5):450-3. [PubMed ID: 26504439]. [PubMed Central ID: PMC4591885]. https://doi.org/10.14503/THIJ-14-4121.
15. Wilson MW, Hoehn ME, Haik BG, Rieman M, Reiss U. Low-dose cyclophosphamide and interferon alfa 2a for the treatment of capillary hemangioma of the orbit. *Ophthalmology*. 2007;**114**(5):1007-11. [PubMed ID: 17337066]. https://doi.org/10.1016/j.ophtha.2006.11.031.
16. Lawley LP, Siegfried E, Todd JL. Propranolol treatment for hemangioma of infancy: risks and recommendations. *Pediatr Dermatol*. 2009;**26**(5):610-4. [PubMed ID: 19840322]. https://doi.org/10.1111/j.1525-1470.2009.00975.x.
17. Wang P, Chapman D, Siddiqui F. A Rare Cardiac Cavernous Hemangioma Treated with Radiotherapy. *Case Rep Vasc Med*. 2022;**2022**:5698475. [PubMed ID: 36105488]. [PubMed Central ID: PMC9467735]. https://doi.org/10.1155/2022/5698475.