

Unilateral Ultrasound-Guided Transversus Abdominis Plane Block After Nephrectomy; Postoperative Pain and Use of Opioids

Nessn H. Azawi,^{1,*} Karina Sif Sondergaard Mosholt,¹ and Mikkel Fode¹

¹Department of Urology, Roskilde Hospital, Roskilde, Denmark

*Corresponding author: Nessn H. Azawi, Department of Urology, Roskilde Hospital, Roskilde, Denmark. Tel: +45-26393034, E-mail: nessn@regionsjaelland.dk

Received 2015 December 08; Revised 2016 January 10; Accepted 2016 January 26.

Abstract

Background: Pain has a wide spectrum of effects on the body and inadequately controlled postoperative pain may have harmful physiologic and psychological consequences and increase morbidity. In addition, opioid anesthetic agents in high doses can blunt endocrine and metabolic responses following surgery and are associated with side effects including dizziness, nausea, vomiting, constipation, and respiratory depression.

Objectives: The current study aimed to investigate if unilateral ultrasound-guided transverse abdominal plane block (TAP-block) could reduce pain and postoperative use of patient requested analgesics following nephrectomy compared to local injection of the same ropivacaine dose in the surgical wound.

Patients and Methods: Retrospective chart reviews were performed in 42 consecutive patients who received TAP-block in conjunction with nephrectomy from November 2013 to August 2014 (group A). For comparison, data were used from 40 other nephrectomy patients registered as part of a previous study (group B). In this group the patients had received local ropivacaine injection in the surgical wound. On univariate analyses, the groups were compared by t-test and the Fisher exact test. Multivariate analyses were conducted by multiple linear regression.

Results: Mean surgical time was 162 minutes in group A and 92 minutes in group B ($P < 0.0001$). The means of visual analogue scale (VAS) were 3.05 and 1.55 in A and B groups, respectively ($P = 0.001$). The means of morphine consumption were 5.2 mg and 5.9 mg in groups A and B, respectively ($P = 0.58$); while the means of sufentanil use were 9.8 μ g and 6.0 μ g in groups A and B, respectively ($P = 0.06$). When controlling for age, tumor size and American society of anesthesiologists classification (ASA) score on multivariate analysis, TAP-block was associated with a significant increase in VAS (+1.4 [95% CI, 0.6 - 2.3], $P = 0.001$) and sufentanil use (+6.2 μ g [95% CI, 2.3 - 10.2], $P = 0.003$). There was no difference in morphine use on multivariate analysis ($P = 0.99$).

Conclusions: TAP-block in conjunction with laparoscopic nephrectomy did not reduce pain or opioid consumption. On the contrary, it seemed to prolong surgical time.

Keywords: Laparoscopic Nephrectomy, Postoperative Pain Management, TAP-Block

1. Background

Pain has a wide spectrum of effects on the body and inadequately controlled postoperative pain may have harmful physiologic and psychological consequences, which may increase morbidity (1, 2). In addition, opioid anesthetic agents in high doses can blunt endocrine and metabolic responses following surgery and are associated with side effects including dizziness, nausea, vomiting, constipation, and respiratory depression (3, 4).

Ultrasound-guided transversus abdominis plane (TAP) block is a relatively new technique to infiltrate regional anesthesia in which local routine anesthetics are injected between the internal oblique and transverse abdominal muscles (Figure 1). The purpose is to provide analgesia to the parietal peritoneum as well as the skin and muscles of the anterior abdominal wall (5). In general, the method has shown promising results in abdominal surgery. How-

ever, studies comparing the method to other forms of local anesthetics are scarce (6). Specifically, only two studies investigated TAP-block in conjunction with nephrectomy (7, 8). These are both well designed randomized trials, but none of them included an active control group. Thus it is unknown if TAP-block confers an advantage over routine wound infiltration with local anesthetics in this patient group.

2. Objectives

The current study aimed to investigate if the single point unilateral ultrasound-guided TAP-block could reduce pain and use of opioids in the postoperative care unit following radical nephrectomy compared to routine infiltration of local anesthetics in the subfascial area at the site of surgical incisions.

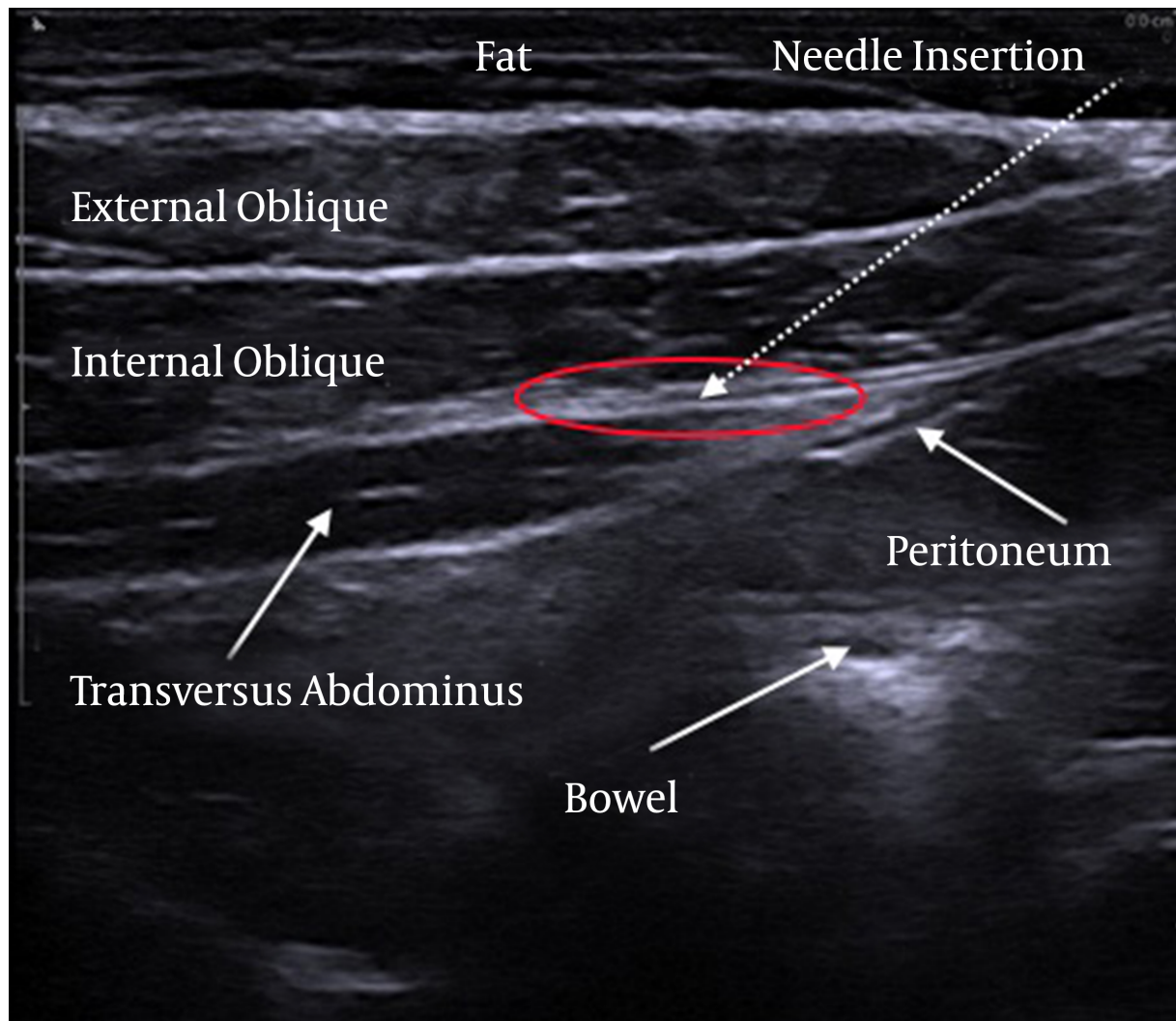


Figure 1. Ultrasound Representation of the Abdominal Wall Muscles and Needle Insertion to Accomplish a Transversus Abdominis Plane Block

3. Patients and Methods

Data were collected retrospectively from the electronic medical records of 42 consecutive patients who received ultrasound guided TAP-block in conjunction with a radical nephrectomy from November 2013 to August 2014 (group A). Forty patients who participated in another study aimed at reducing the postoperative hospital stay following radical nephrectomy (ClinicalTrials.gov identifier: NCT02295982) and received wound infiltration with local anesthetics served as a control group (group B). All patients underwent surgery at the department of urology, Roskilde hospital.

Preoperative analgesics in the form of Gabapentine® 600 mg, acetaminophen 1330 mg, and dexamethasone 8

mg were administered two hours before surgery. Unilateral single point TAP-block was performed immediately prior to radical nephrectomy by ultrasound guided injection of 20 mL of 7.5% ropivacaine through a 50 or 80-mm needle (SonoPlex Stim cannula®, Pajunk, GmbH, Germany) by the same two anesthesiologists or under their supervision. Twenty milliliters of 7.5% ropivacaine was administered as wound infiltration anesthetics in group B. Age, tumor size, American society of anesthesiologists' physical status (ASA) score and surgical time were recorded for all patients. Visual analogue scale score for pain (VAS) was collected one hour after admission to the postoperative care unit and the total amounts of opioids administered during the first postoperative hour were recorded.

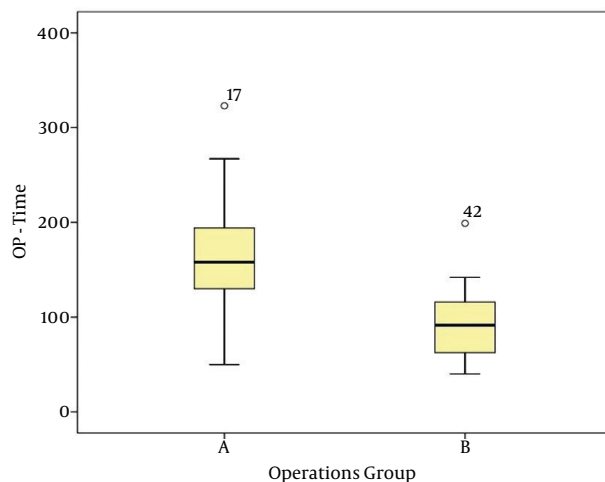
On univariate analyses, continuous variables were compared by the unpaired t-test; while categorical variables were compared with the Fisher exact test. Multivariate analyses controlling for age, tumor size and ASA score were conducted by multiple linear regression and multiple logistic regression, respectively. The surgical time was not included in the multivariate analyses as a significant increase was caused by the TAP-block administration itself. Statistical analyses were conducted using SAS version 9.2 (Institute Inc. Cary, NC, USA). The study was approved by the Danish data protection agency in accordance with Danish law (SN-43-2012).

4. Results

There were no significant differences in age ($P = 0.434$) or tumor size ($P = 0.218$) between the groups. However, the ASA score was higher in group A ($P = 0.029$) (Table 1). No patients suffered major complications from the TAP-block administration as assessed by the Clavien Dindo classification (9).

The mean surgical time was 162 minutes in group A and 92 minutes in group B ($P < 0.0001$) (Figure 2). The mean of VAS was 3.05 [95% CI, (2.39 - 3.70), SE 0.325] in group A and 1.55 [95% CI, (.99 - 2.11), SE, 0.275] in group B ($P = 0.001$) (Figure 3). The means of morphine consumption were 5.2 mg and 5.9 mg in groups A and B, respectively ($P = 0.58$), while the means of sufentanil use were 9.8 μg and 6.0 μg in the 2 groups A and B, respectively ($P = 0.06$).

Figure 2. Distribution of Surgery Time Between Groups A and B



OP-time = surgery time in minutes.

When controlling for age, tumor size, and ASA score on multivariate analyses, TAP-block was associated with a sig-

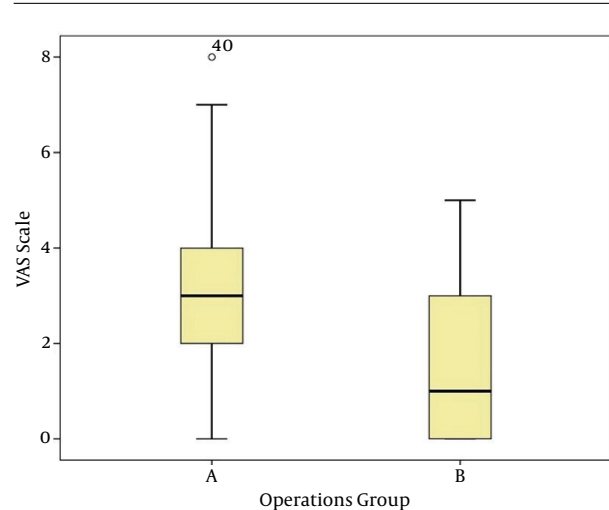


Figure 3. Distribution of VAS-Score Between Groups A and B

nificant increase in VAS (+1.4 [95% CI, 0.6 - 2.3], $P = 0.001$) and sufentanil use (+6.2 μg [95% CI, 2.3 - 10.2], $P = 0.003$). There was no difference in morphine use on multivariate analysis ($P = 0.99$).

5. Discussion

According to a Cochrane review published in 2010, TAP-block resulted in a significantly smaller morphine requirement in the first 48 postoperative hours compared with no TAP-block or saline placebo (mean difference -28.50, 95% CI, -38.92 to -18.08) while it reduced pain at rest in 2/3 studies. However, the authors concluded that there was only limited evidence to support the use of TAP-block and that further studies comparing TAP-block to other local anesthetic approaches were needed. Moreover, none of the individual studies had looked at patients undergoing nephrectomy.

Since the publication of the Cochrane review, an abundance of TAP-block studies have appeared and its effectiveness compared to placebo has been confirmed (10). In addition, a number of studies have compared the method to other forms of local anesthetics. Some of these have pointed to an advantage of TAP-block over wound site infiltration after gynecological procedures and hernia repair in children (11, 12). Meanwhile other studies suggest that wound site infiltration is either superior or at least equivalent to the more complicated TAP-block in gynecologic laparoscopy, gastric-bypass surgery, inguinal hernia repair, laparoscopic cholecystectomy and after open radical prostatectomy (13-15).

However, to date only two studies have investigated TAP-block in conjunction with nephrectomy, both utiliz-

Table 1. Demographic and Perioperative Outcome After Nephrectomy

	Mean \pm SE	95% Confidence Interval for Mean		P Value
		Lower Bound	Upper Bound	
Age				
A	61.21 \pm 2.237	56.70	65.73	0.434 ^a
B	59.25 \pm 1.018	57.19	61.31	
VAS scale				
A	3.05 \pm 0.325	2.39	3.70	0.001 ^b
B	1.55 \pm 0.275	0.99	2.11	
ASA				
A	2.14 \pm 0.094	1.95	2.33	0.029 ^b
B	1.90 \pm 0.070	1.76	2.04	
Tumor size, mm				
A	57.89 \pm 3.850	50.09	65.69	0.218 ^a
B	64.63 \pm 3.818	56.90	72.35	
OP-Time, min				
A	162.43 \pm 8.594	145.07	179.79	< 0.001 ^b
B	92.10 \pm 5.629	80.71	103.49	
Morphine, mg				
A	5.24 \pm 0.702	3.82	6.65	0.581 ^a
B	5.93 \pm 1.033	3.84	8.01	
Sufentanil, μ g				
A	9.76 \pm 1.465	6.80	12.72	0.057 ^b
B	6.00 \pm 1.268	3.43	8.57	

Abbreviations: ASA, American society of anesthesiologists' physical status; OP-Time, surgery time in minutes; Vas, visual analogue scale score for pain.

^aP > 0.05 is non-significant.

^bP < 0.05 is significant.

ing a placebo control group (7, 8). In the first study by Hosgood et al. (7), the authors found that single site TAP-block with bupivacaine (0.375%) incurred a reduction in early morphine use (up to six hours after surgery, $P = 0.015$) but not in overall morphine use ($P = 0.771$) when compared to saline TAP-block injection. Meanwhile the method resulted in significantly less pain on postoperative days one ($P = 0.003$) and two ($P = 0.031$). Likewise, the second study by Parikh et al. (8), found that ultrasound guided bupivacaine TAP-block at the end of surgery reduced postoperative tramadol consumption compared to saline injection ($P < 0.05$). It also reduced the VAS score up to 12 hours postoperatively with the largest benefit observed at 30 minutes after the surgery (0.77 vs. 3.23, $P < 0.05$).

The current study is the first to compare the effects of preoperative TAP-block to wound infiltration with local anesthetics. Considering the relative success with TAP-block reported in the literature the current study results

were somewhat disappointing. Thus, unilateral TAP-block seemed inferior to local wound infiltration. In spite of these disappointing results, it should be noted that TAP-block is not an insufficient pain killer per say as the mean VAS score was still relatively low and as most of the patients undergoing nephrectomy in the current study were kept under the critical pain level. In addition, it is important to consider the possibility of other TAP-block protocols. The current study used unilateral single point TAP-block immediately prior to surgery. Meanwhile, bilateral dual TAP-block in the postoperative care unit has previously shown to reduce pain and opioid use (16). While it seems somewhat illogical that bilateral TAP-block would in itself improve pain control after a unilateral procedure, the timing of the administration may be crucial. Thus, the half-life of ropivacaine is approximately two hours. Although the same drug was used in the control group, the mean surgical time of 162 minutes in group A could mean that the

effects had begun to wear off in the current study, meaning that postoperative TAP-block administration may be the optimal choice. Likewise, it is possible that other drugs may be better suited for TAP-block and it is suggested that the addition of other drugs such as dexamethasone (17, 18), hyaluronidase, and epinephrine may enhance the analgesic effects. In any case, more research is clearly needed to establish the optimal drug regimen.

As an additional finding, the current study noted that the operation time was significantly increased due to the time spent on the TAP-block administration. This factor is not well described in the literature and, although the administration time may decrease with experience, it is certainly worth more attention in future studies. The current study did not find any other adverse effects of TAP-block and generally, few side effects of TAP-block were cited in the literature. However, potentially toxic blood concentrations of ropivacaine are found in the patients' blood following the procedure and seizures were reported (19, 20).

The most important limitation of the current study was that it only recorded pain and morphine consumption for the first postoperative hour. However, based on the preceding nephrectomy studies the benefits are unlikely to improve over time. Other limitations include the retrospective nature of the study and the fact that the control group was derived from another study aimed at reducing the postoperative hospital stay following radical nephrectomy. However, when controlling the possible confounders on multivariate analyses, the differences between the groups were only attenuated. Small sample size is another limitation of this study. Although there may be unrecognized confounding factors, it is therefore unlikely that the administration of unilateral single point TAP-block is superior to wound infiltration with local anesthetics in the early postoperative phase as hypothesized. Certainly, the current study findings do not justify the increased surgical time and potential risk of seizures with TAP-block.

The current study did not show a benefit of single point unilateral TAP-block compared to routine wound infiltration with local anesthetics in the early postoperative phase. Thus, the method cannot be recommended based on the obtained results. Based on the literature as a whole, TAP-block in conjunction with nephrectomy should be considered experimental at this stage. In future studies, it is important to consider alternative TAP-block protocols in order to secure optimal results.

Footnote

Authors' Contribution: Study concept and design: Nessn H. Azawi; analysis and interpretation of data: Nessn H.

Azawi; drafting of the manuscript: Nessn H. Azawi, Mikkel Fode and Karina Sif Sondergaard Mosholt; critical revision of the manuscript for important intellectual content: Nessn H. Azawi, Mikkel Fode; statistical analysis: Nessn H. Azawi; study supervision: Mikkel Fode.

References

- Joshi GP. Multimodal analgesia techniques and postoperative rehabilitation. *Anesthesiol Clin North America*. 2005;**23**(1):185–202. doi: [10.1016/j.atc.2004.11.010](https://doi.org/10.1016/j.atc.2004.11.010). [PubMed: [15763418](https://pubmed.ncbi.nlm.nih.gov/15763418/)].
- Liu SS, Carpenter RL, Mackey DC, Thirlby RC, Rupp SM, Shine TS, et al. Effects of perioperative analgesic technique on rate of recovery after colon surgery. *Anesthesiology*. 1995;**83**(4):757–65. [PubMed: [7574055](https://pubmed.ncbi.nlm.nih.gov/7574055/)].
- Reier CE, George JM, Kilman JW. Cortisol and growth hormone response to surgical stress during morphine anesthesia. *Anesth Analg*. 1973;**52**(6):1003–10. [PubMed: [4357065](https://pubmed.ncbi.nlm.nih.gov/4357065/)].
- Benyamin R, Trescot AM, Datta S, Buenaventura R, Adlaka R, Sehgal N, et al. Opioid complications and side effects. *Pain Physician*. 2008;**11**(2 Suppl):S105–20. [PubMed: [18443635](https://pubmed.ncbi.nlm.nih.gov/18443635/)].
- McDonnell JG, O'Donnell BD, Farrell T, Gough N, Tuite D, Power C, et al. Transversus abdominis plane block: a cadaveric and radiological evaluation. *Reg Anesth Pain Med*. 2007;**32**(5):399–404. doi: [10.1016/j.rapm.2007.03.011](https://doi.org/10.1016/j.rapm.2007.03.011). [PubMed: [17961838](https://pubmed.ncbi.nlm.nih.gov/17961838/)].
- Charlton S, Cyna AM, Middleton P, Griffiths JD. Perioperative transversus abdominis plane (TAP) blocks for analgesia after abdominal surgery. *Cochrane Database Syst Rev*. 2010(12):CD007705. doi: [10.1002/14651858.CD007705.pub2](https://doi.org/10.1002/14651858.CD007705.pub2). [PubMed: [21154380](https://pubmed.ncbi.nlm.nih.gov/21154380/)].
- Hosgood SA, Thiagarajan UM, Nicholson HF, Jeyapalan I, Nicholson ML. Randomized clinical trial of transversus abdominis plane block versus placebo control in live-donor nephrectomy. *Transplantation*. 2012;**94**(5):520–5. doi: [10.1097/TP.0b013e31825c1697](https://doi.org/10.1097/TP.0b013e31825c1697). [PubMed: [22902793](https://pubmed.ncbi.nlm.nih.gov/22902793/)].
- Parikh BK, Waghmare VT, Shah VR, Mehta T, Butala BP, Parikh GP, et al. The analgesic efficacy of ultrasound-guided transversus abdominis plane block for retroperitoneoscopic donor nephrectomy: A randomized controlled study. *Saudi J Anaesth*. 2013;**7**(1):43–7. doi: [10.4103/1658-354X.109808](https://doi.org/10.4103/1658-354X.109808). [PubMed: [23717232](https://pubmed.ncbi.nlm.nih.gov/23717232/)].
- Dindo D, Demartines N, Clavien PA. Classification of surgical complications: a new proposal with evaluation in a cohort of 6336 patients and results of a survey. *Ann Surg*. 2004;**240**(2):205–13. [PubMed: [15273542](https://pubmed.ncbi.nlm.nih.gov/15273542/)].
- De Oliveira GJ, Castro-Alves LJ, Nader A, Kendall MC, McCarthy RJ. Transversus abdominis plane block to ameliorate postoperative pain outcomes after laparoscopic surgery: a meta-analysis of randomized controlled trials. *Anesth Analg*. 2014;**118**(2):454–63. doi: [10.1213/ANE.0000000000000066](https://doi.org/10.1213/ANE.0000000000000066). [PubMed: [24445643](https://pubmed.ncbi.nlm.nih.gov/24445643/)].
- Aydogmus M, Sinikoglu S, Naki M, Ocak N, Sanli N, Alagol A. Comparison of analgesic efficiency between wound site infiltration and ultra-sound-guided transversus abdominis plane block after cesarean delivery under spinal anaesthesia. *Hippokratia*. 2014;**18**(1):28–31. [PubMed: [25125948](https://pubmed.ncbi.nlm.nih.gov/25125948/)].
- Sivapurapu V, Vasudevan A, Gupta S, Badhe AS. Comparison of analgesic efficacy of transversus abdominis plane block with direct infiltration of local anesthetic into surgical incision in lower abdominal gynecological surgeries. *J Anaesthesiol Clin Pharmacol*. 2013;**29**(1):71–5. doi: [10.4103/0970-9185.105807](https://doi.org/10.4103/0970-9185.105807). [PubMed: [23493578](https://pubmed.ncbi.nlm.nih.gov/23493578/)].
- Albrecht E, Kirkham KR, Endersby RV, Chan VW, Jackson T, Okrainec A, et al. Ultrasound-guided transversus abdominis plane (TAP) block for laparoscopic gastric-bypass surgery: a prospective randomized controlled double-blinded trial. *Obes Surg*. 2013;**23**(8):1309–14. doi: [10.1007/s11695-013-0958-3](https://doi.org/10.1007/s11695-013-0958-3). [PubMed: [23591549](https://pubmed.ncbi.nlm.nih.gov/23591549/)].

14. El Hachem L, Small E, Chung P, Moshier EL, Friedman K, Fenske SS, et al. Randomized controlled double-blind trial of transversus abdominis plane block versus trocar site infiltration in gynecologic laparoscopy. *Am J Obstet Gynecol.* 2015;**212**(2):182 e1-9. doi: [10.1016/j.ajog.2014.07.049](https://doi.org/10.1016/j.ajog.2014.07.049). [PubMed: [25088860](https://pubmed.ncbi.nlm.nih.gov/25088860/)].
15. Petersen PL, Mathiesen O, Stjernholm P, Kristiansen VB, Torup H, Hansen EG, et al. The effect of transversus abdominis plane block or local anaesthetic infiltration in inguinal hernia repair: a randomised clinical trial. *Eur J Anaesthesiol.* 2013;**30**(7):415-21. doi: [10.1097/EJA.0b013e32835fc86f](https://doi.org/10.1097/EJA.0b013e32835fc86f). [PubMed: [23549122](https://pubmed.ncbi.nlm.nih.gov/23549122/)].
16. Borglum J, Maschmann C, Belhage B, Jensen K. Ultrasound-guided bilateral dual transversus abdominis plane block: a new four-point approach. *Acta Anaesthesiol Scand.* 2011;**55**(6):658-63. doi: [10.1111/j.1399-6576.2011.02430.x](https://doi.org/10.1111/j.1399-6576.2011.02430.x). [PubMed: [21463262](https://pubmed.ncbi.nlm.nih.gov/21463262/)].
17. Akkaya A, Yildiz I, Tekelioglu UY, Demirhan A, Bayir H, Ozlu T, et al. Dexamethasone added to levobupivacaine in ultrasound-guided transversus abdominis plain block increased the duration of postoperative analgesia after caesarean section: a randomized, double blind, controlled trial. *Eur Rev Med Pharmacol Sci.* 2014;**18**(5):717-22. [PubMed: [24668714](https://pubmed.ncbi.nlm.nih.gov/24668714/)].
18. Kitayama M, Wada M, Hashimoto H, Kudo T, Takada N, Hirota K. Effects of adding epinephrine on the early systemic absorption kinetics of local anesthetics in abdominal truncal blocks. *J Anesth.* 2014;**28**(4):631-4. doi: [10.1007/s00540-013-1784-4](https://doi.org/10.1007/s00540-013-1784-4). [PubMed: [24474619](https://pubmed.ncbi.nlm.nih.gov/24474619/)].
19. Torup H, Mitchell AU, Breindahl T, Hansen EG, Rosenberg J, Moller AM. Potentially toxic concentrations in blood of total ropivacaine after bilateral transversus abdominis plane blocks; a pharmacokinetic study. *Eur J Anaesthesiol.* 2012;**29**(5):235-8. doi: [10.1097/EJA.0b013e328350b0d5](https://doi.org/10.1097/EJA.0b013e328350b0d5). [PubMed: [22450529](https://pubmed.ncbi.nlm.nih.gov/22450529/)].
20. Weiss E, Jolly C, Dumoulin JL, Meftah RB, Blanie P, Laloe PA, et al. Convulsions in 2 patients after bilateral ultrasound-guided transversus abdominis plane blocks for cesarean analgesia. *Reg Anesth Pain Med.* 2014;**39**(3):248-51. doi: [10.1097/AAP.0000000000000088](https://doi.org/10.1097/AAP.0000000000000088). [PubMed: [24682078](https://pubmed.ncbi.nlm.nih.gov/24682078/)].