

Insertion of Intraprostate Gold Fiducial Markers in Prostate Cancer Treatment

Joaquín Ulises Juan Escudero^{1*}, Jorge Pastor Peidro², Macarena Ramos de Campos¹, Jose Lopez Torrecilla², Emilio Lopez Alcina¹, Pedro Navalón Verdejo¹, Milagros Fabuel Deltoro¹, Emilio Marques Vidal¹

¹Departement of Urology, Consorcio Hospital General de Valencia, Valencia, Spain

²Departement of Radiotherapeutic Oncology, ERESA, Valencia, Spain

Abstract

Background and Aims: Surgery and radiotherapy continue to be the treatments of choice for localised and locally advanced prostate cancer. In recent years, we have witnessed significant development in radiotherapy techniques in order to increase the dose on the target volume and diminish side effects. In the following work, we describe the technique of insertion of gold fiducial markers (gold seeds) as well as their application and usefulness in the treatment of localized and locally advanced prostate adenocarcinoma with image guided radiotherapy (IGRT) by means of the Exac Trac® system.

Methods: We did a prospective descriptive study including consecutive patients undergoing IGRT in our hospital. Patients were reviewed one week after the insertion of the markers and in each radiotherapeutic session. Between October 2005 and June 2007, we carried out a total of 126 procedures using this technique. Each patient was interviewed in each radiotherapeutic session. Three or four gold intraprostatic fiducial markers were implanted in each patient by transrectally and ultrasound guided. We reported patients tolerance of this technique by a satisfaction questionnaire, as well as the early and late complications derived from the insertion of the markers in the clinical interview. We collected the movements of the gold seeds.

Results: Complications observed were: urinary infection in 4 cases (3.2%), prostatitis in 2 cases (1.6%), slight pelvic pain in 6 patients (4.8%) and self-limited rectal bleeding in 8 patients (6.4%). None of the patients presented hematuria. Loss of 1 marker was registered in 7 patients (5.5%) and loss of 2 markers in 2 patients (1.6%).

Conclusions: Insertion of fiducial markers for prostate cancer treatment is a technique of very simple execution, easy to reproduce almost free of adverse effects, which is able to reduce toxicity derived from radiotherapy and allows dose escalation in radiotherapy.

Keywords: Fiducial Markers, Image-Guided Radiotherapy, Prostate Cancer, Treatment

Introduction

Prostate cancer causes almost 9% of the deaths from cancer recorded in men. The appearance of PSA has led to an increase in the diagnosis of this disease, as well as a migration towards its diagnosis in earlier stages, which translates as an increase in the number of patients that may be offered a potentially

**Correspondence:*

Joaquín Ulises Juan Escudero
Avenida Juan Carlos I, 7
03370 Redován (Alicante), Spain.
Tel: +98+34657500969
E-mail: chimojuan@hotmail.com
Received: 29 Jun 2009
Accepted: 19 Jul 2009

curative therapy.

In the absence of randomised studies that compare radical prostatectomy and radiotherapy, the National Institutes of Health (NIH) consensus of 1988 still holds, proposing that radiotherapy obtains the same results in terms of long term survival as surgery, and in addition offers a quality of life at least as good as does surgery (1).

It is more than two decades since the first results of three-dimensional conformal radiotherapy (3D-CRT) in prostate cancer were described. Later, in the 1990s, 3D-CRT evolved towards intensity modulated radiotherapy (IMRT), which enables a greater precision and optimisation of the treatments with a reduction in the dose administered to the organs at risk and therefore a reduction in toxicity. This has led to improved results in control of the disease by means of dose escalation. However, this eagerness to increase the dose given led to two problems: the first is that the prostate moves, reaching displacements of up to 5mm¹⁰, the second is the difficulty in protecting the rectum from the high doses due to its mobility and the need for greater margins due to the mobility of the prostate. Therefore, we know that in order to scale dosage, we must reduce margins by means of an increase in the precision of treatments and monitoring of prostate displacements. This has been achieved through the development of image guided radiotherapy systems (IGRT). There are different devices and techniques to carry out IGRT, one of the possibilities being intraprostate insertion of radio-opaque gold fiducial markers and the verification and correction of their position by means of Kilo-voltage X rays. One of these positioning systems, the ExacTrac-X Ray 3.5 from Brain LAB, has been installed in our center.

Since the use of these markers is beginning to spread in our country, we want to describe the insertion technique and use of intraprostate gold fiducial markers, as well as analysing the most common complications arising from implants that

we have observed in our center.

Materials and Methods

The inclusion criteria for the treatment with IGRT were men diagnosed with localised or locally advanced prostate adenocarcinoma, having been informed previously about the different therapeutic options available. All the markers were implanted by four urologists. Once the technique was applied, the patients were told to go to the emergency service of our center in the event of urinary symptoms, hematuria, rectal bleeding or moderate or severe pain. In the radiotherapeutic oncology visit, the complications observed by the patient, as well as the treatment used and its duration, were taken into account. The possible complications about which the patient was questioned were: hematuria, rectal bleeding, pain, fever and urinary symptoms. In addition, in each planning CT as well as in each pair of images obtained with the ExacTrac system, the presence of the 4 markers is checked, recording the cases in which a loss of these markers.

Marker insertion technique description

Detailed anamnesis, physical exploration and coagulation study were performed pre-operatively. If the patient was in anticoagulation treatment, it was withdrawn and replaced by low molecular weight heparin for seven days prior to intervention. If they were on antiaggregant treatment, the medication was suspended 3-7 days before implanting. The day before insertion of the markers, prophylaxis was performed with 500mg of oral ciprofloxacin followed by another dose on the morning of the intervention and 500mg every 12 hours until completing eight doses. Also, prior to implant, the patient was given an enema of 250ml and 575mg of oral metamizol. Fifteen minutes before beginning, 25gr of lidocaine and clorhexidine intrarectal gel was applied (Cathejell®).

To proceed with the insertion of the markers, the patient was placed in lithotomy position and a

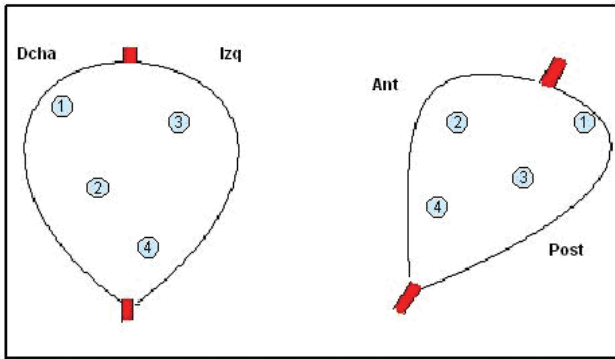


Figure 1. Coronal and sagittal sight of the position of the markers in the prostate

rectal ultrasound transducer introduced (Aloka SSD-1400), with a guide for implantation of the markers. Each marker is cylindrical and with a rough surface, 3mm in length and 1mm in diameter. In a first step, the distal end of a 18 Gauge braquitherapy needle (Oncura® 20 cm in length) is obturated with bone wax so that when the marker is introduced it is not lost by this end. The marker is inserted in the needle and fastener. Once insertion of the needle is checked by ultrasound, the marker is implanted by pushing it with the fastener, and this way, the exit through the end of the needle of the fiducial marker can be verified by means of the transrectal ultrasound scan. The gold fiducial markers are hyperecogenic compared with prostate tissue and, contrary to what would be expected; instead of shade they have a posterior enhancement, making it easy to distinguish their typical shape and brightness upon exit. Once the marker is out of the needle we have to wait for 20 seconds before withdrawing it so that the wax is liquefied and does not drag the seed through the insertion passage.

The 4 markers were implanted successively in the following manner: The first two in the right lobe and other two in the left lobe, as asymmetrically as possible. The first marker is the one that is inserted more cranially, in the base of the prostate in the most posterior aspect. The second marker, also in the right lobe, is located in the middle third of the prostate, to approximately the same depth as the first. The third

marker is deposited cranially in the left lobe, but in a more caudal and more anterior position than the first marker. The fourth marker is inserted more apically, trying to get as close as possible to the urethra while taking care not to puncture it, because of the risk of hematuria and seed migration (Figure 1).

Immobilisation, CT scan and treatment

After a period of 7 days for the possible prostate oedema caused during the insertion to disappear, the patient is immobilised in the supine position with a pelvic immobilisation device (alpha-cradle), a support located in popliteal cavity and a foot locking device. The same day, a planning CT with a thickness and separation between cuts of 3mm is carried out. After outlining of the organs at risk and target volumes, the virtual planning of the treatment is carried out, followed by verification of the same on a dummy with radiographic films.

On the first day of the treatment, the patient is placed in 0.0.0 position of the planning CT on the basis of the cutaneous and alpha-cradle references. The required displacements to transfer the patient to the treatment isocenter are made and 1 pair of images is obtained with the ExaTrac X Ray system from BrainLab with which the markers are located. Depending on their position, the treatment isocenter is corrected (Figure 2).

After the first session of treatment, another pair of images was taken to evaluate prostate movement during the session. During all posterior sessions, a pair of pre-treatment images was obtained, to be used for correction of the interfraction movement and another pair of post-treatment images that enabled evaluation of the intrafraction motion. This evaluation was taken during the first 5 days and if displacements greater than 6mm in any of the measurements, it is prolonged for another 5 days, and if this variation persists, it is necessary to plan again with new margins. Pre-treatment check for correction of the interfraction movement was carried out

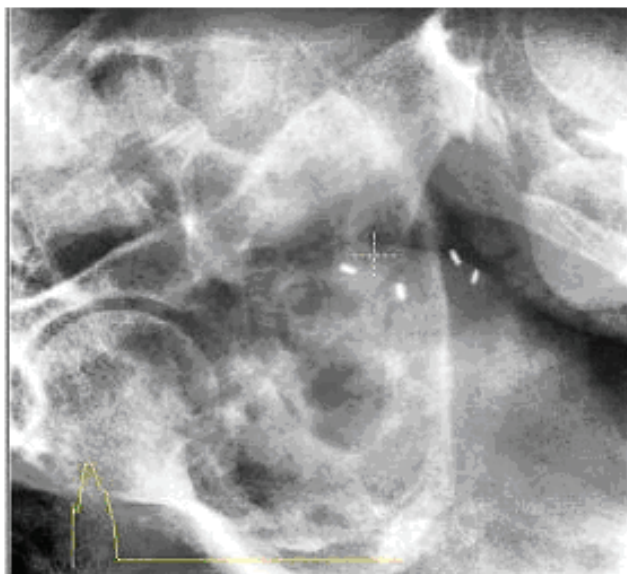

Figure 2. Image obtained with the Exa-Trac system showing the final position of the four fiducial markers

daily.

Results

Between October 2005 and June 2007, we carried out a total of 126 treatments with IGRT in patients with ages from 58 to 72 years of age. The mean age was 67 years. Three markers were inserted in the first ten patients, and four in the rest. In all the patients, we obtained the complications secondary to the insertion as well as the loss of the markers.

All the patients presented good tolerance to implantation of the markers and no complications were reported during the technique. It took a mean of 13 minutes to perform the procedure (range 9-22 minutes).

Complications: The complications observed were: 4 cases (3.2%) of symptomatic urinary infection which was treated in all cases with empirical oral antibiotic therapy under outpatient regime. In all of them, the duration of urinary tract symptom was shorter than 5 days. In one of these cases, the patient had not correctly completed the antibiotic prophylactic guideline indicated.

On the other hand, there were 2 cases (1.6%) of infectious prostatitis with associated fever which were treated with antibiotic (levofloxacin) and became asymptomatic in a period shorter than 10 days. In one of them, the symptoms appeared at 9 days after insertion, 2 days after the planning CT in which the patient was fitted with a urinary probe for the contrast injection into the bladder. We considered that the urinary manipulation during probing could be related with the prostatitis.

None of the patients presented hematuria, and eight patients (6.4%) presented self-limited rectal bleeding without clinical relevance, which in all cases disappeared in the first few hours after insertion and in no case required medical or surgical intervention or blood transfusion.

Six patients (4.8%) presented slight pelvic-prostate pain between the next day and the 7 days following insertion. In no case analgesic use was needed.

All the complications presented were treated in outpatient regime. Of all the patients, only in the 2 who presented prostatitis was there a delay in starting the radiotherapy for this reason, which did not exceed 12 days as of the date anticipated.

Loss of markers: Three markers were inserted in the first 10 patients. Of these, at the moment of the planning CT, the loss of 1 marker was observed in one and 2 in the other, which meant that in these 2 cases the ExacTrac system could not be used. The insertion of 4 markers in the other 116 patients was decided. In the planning CT for these patients, losses of 1 marker in 6 patients and 2 in 1 patient were detected. In the 6 patients with the loss of one marker, it was possible to perform the ExacTrac position correction technique since the system requires a minimum of three markers. So, the marker loss rate observed was 5.5 % for loss of a single marker and 1.6 % for the loss of two markers.

When carrying the planning CT, it was appreciated that in 1 case the migrated marker was located in the

bladder, in another case in the peritoneal cavity, and in the remaining cases the markers were not located, which lead us to conclude that they were expelled by rectal or urinary tract.

During treatment, no marker loss was observed in the daily checking of the position of the markers with the ExacTrac system.

Discussion

Recent years have witnessed a clear technological advancement of radiotherapy with the aim of improving the precision of treatments, which enables a reduction in its toxicity and so allows an increase in the dose administered. This dose escalation, as it is known, improves control of the disease (2-5). However, in this eagerness to improve precision, one of the main problems that arises is the movement of the prostate that occurs both during the radiotherapy sessions (intrafraction motion) and between each of the fractions (interfraction movement) and which is responsible, among other factors, for the toxicity appearing from this technique due to the radiation dose that reaches the adjacent normal organs (6). The movement of the prostate during the course of radiotherapy treatment for cancer has therefore been a long standing object of study (7) and, as mentioned previously, even more so recently with the dose escalation of RTC-3D, IMRT and IGRT. Interfraction movement rates of the prostate with respect to the bony structures in the cranial-caudal axis of up to 15mm have been described; in the lateral plane, the prostate presents displacements of much fewer significance (8). Numerous parameters affect the movement of the gland during radiotherapy. Factors such as bladder filling and rectal repletion or respiratory movements have been implicated in the imprecision of the location of the gland in relation to the bony structures (7, 9). In this sense, several authors have published their experiences with the use of radio-opaque markers as fiducials for location of the gland (6, 10, 11).

The insertion of intraprostate gold fiducial

markers constitutes a technique relatively simple to accomplish, especially for the urologist related with transrectal ultrasound scan and prostate biopsy. We believe that for these reasons it is easily reproducible (12).

Since only four injections are made and most of the patients have already undergone biopsy with at least ten, we differ from others authors (13) on the need for local anaesthetic in the prostatic pedicle. In our experience, the technique was very well tolerated by all the patients and no additional analgesia to the 575mg of metamizol administered pre-operatively was required, which is why we believe that this procedure can be performed without local anaesthesia and in outpatient regime (14). However, we consider antimicrobial prophylaxis prior to execution of the technique necessary, as in prostate biopsies, following the same guidelines with which the biopsies (15) were performed, as well as withdrawal of the anti-thromboembolic therapy in view of the hemorrhage risk.

Complications observed in our analysis were urinary infection in 3.2%, prostatitis in 1.6%, pelvic pain in 4.8%, and rectal bleeding in 6.4%, with no hematuria in any case. We consider that the absence of hematuria may be due to the interest in not damaging the urethra with the insertion manipulation, since, in all the cases the technique was performed by urologists.

There are few studies in which the toxicity of intraprostate gold fiducial marker insertion is described. In the study published in 2007 by Langenhuijsen et al (15) in 209 patients, where 4 markers were inserted by endorectal route and guided by ultrasound, the following complications were reported: hematuria in 3.8%, hematospermia in 18.5%, rectal bleeding in 9.1% and pain requiring analgesics in 2.9%.

In 2004, Henry et al (16) published the results of the insertion of 3 intraprostatic gold fiducial markers in 12 patients, but by transperineal route. They reported hematuria in 3 patients, hematospermia in one and rectal bleeding in another one and severe pain in 3

were observed, requiring analgesics in one case. No infection was detected.

In 2003, Denhad (8) published the results of the ultrasound guided insertion of a maximum of three markers in 10 patients. Transitory presence of hematuria was observed in the first 24 hours in 3 patients and some episodes of rectal bleeding were reported in 7 patients.

Therefore, if we consider our results and those of the study with the largest number of patients, that of Langenhuijsen et al (15) with 236 patients, we may affirm that insertion of the intraprostate gold markers has a low rate of complications, notably below that was observed in prostate biopsies.

None of our patients presented significant rectal bleeding requiring endoscopic evaluation or treatment, as opposed to that reported in a series of prostate biopsies, where Figures of up to 1% are reached, with no patients presenting hematuria, surely due to the eccentric positioning of the markers with respect to the urethra (17, 18).

Considering the number of markers inserted, most authors recommend implantation of three (14, 19, 20). Initially, in the first 10 patients 3 markers were implanted, which is the minimum number required by the ExacTrac fusion software. However, in 2 cases, due to the loss of some of the markers, the correction with ExacTrac could not be carried out. This is one of the reasons that the use of 4 markers was decided, as in this way the risk of being left with less than three markers in the event of loss of one of them is reduced. The other reason is that the fusion software can give erroneous results if one of the markers is too far from its expected position or if it mistakenly identifies a different seed. Using 4 markers, decreases the risk of these problems, and this procedure is encouraged by the Exac Trac system manufacturer. We were also able to observe that the use of 4 seeds does not significantly increase the morbidity or entail an important increase in insertion time.

When three markers were inserted, its location

was in base, middle third and apex, or two in base and one in apex. In our study, we decided on the location (much more eccentric) because, as noted previously, the location of the seeds in planes as different as possible is important, which is why we tried to avoid the specular locations by modification of the implantation depth, height and laterality, although this is not always possible, especially in smaller sized prostates.

The seed loss rate in our case was 5.5% for loss of 1 marker and 1.6% for the loss of 2 markers. The highest percentage of losses was observed in the first 30 patients, which could be attributed to the learning curve of the different urologists trained to carry out this technique. With the exception of one case where the migrated seed was located in the bladder, and in another one in the peritoneal cavity, in the rest they could not be located, so we assume that these were expelled rectally or eliminated in the urine. Our rate of losses is within the percentages described in other series where it is described as oscillating between less than 1% and 8% (13).

Although it was not the aim of this work, we observed that throughout the radiotherapy treatment, the markers presented very few intraprostate migratory movements (20), the distance between them tending to diminish in most cases (8, 20). The presence of inflammation secondary to the implantation process may contribute to these movements, as may growth of the tumour in the tissue response to radiotherapy (9), as well as the adjuvant hormonal treatment.

The minimum migratory movement of the markers makes it a practical and effective technique for the visualisation and referencing of the prostate during radiation, as well as enabling the opportune corrections to be made during treatment. Verification of the position before the beginning of the session can substantially reduce the interfraction variations compared with other position checking techniques (8).

Conclusions

Transrectal implantation of intraprostate gold

fiducial markers to check the prostate position on a daily basis and is a minimally invasive technique with fast mechanics, well-known to urologists and is easily reproducible. Moreover, the morbidity related to the insertion technique is very low or tolerable.

It is one of the prostate position verification techniques that enables us to perform an IGRT. This means greater precision in radiotherapy treatment, resulting in a reduction of the toxicity related to it in the adjacent organs, the narrowing of safety margins, and therefore the possibility of scaling the dose on the treatment more safely.

Conflict of Interest

None declared.

References

1. Heidenreich A, Aus G, Bolla M, et al. EAU guidelines on prostate cancer. *Eur Urol*. 2008;53:68-80.
2. Dearnaley DP, Hall E, Lawrence D, et al. Phase III pilot study of dose escalation using conformal radiotherapy in prostate cancer: PSA control and side effects. *Br J Cancer*. 2005;92:488-98.
3. Peeters ST, Heemsbergen WD, Koper PC, et al. Dose-response in radiotherapy for localized prostate cancer: results of the Dutch multicenter randomized phase III trial comparing 68 Gy of radiotherapy with 78 Gy. *J Clin Oncol*. 2006;24:1990-6.
4. Pollack A, Zagars GK, Starkschall G, et al. Prostate cancer radiation dose response: results of the M. D. Anderson phase III randomized trial. *Int J Radiat Oncol Biol Phys*. 2002;53:1097-105.
5. Zietman AL, DeSilvio ML, Slater JD, et al. Comparison of conventional-dose vs high-dose conformal radiation therapy in clinically localized adenocarcinoma of the prostate: a randomized controlled trial. *JAMA*. 2005;294:1233-9.
6. Crook JM, Raymond Y, Salhani D, Yang H, Esche B. Prostate motion during standard radiotherapy as assessed by fiducial markers. *Radiother Oncol*. 1995;37:35-42.
7. Dawson LA, Litzenberg DW, Brock KK, et al. A comparison of ventilatory prostate movement in four treatment positions. *Int J Radiat Oncol Biol Phys*. 2000;48:319-23.
8. Dehnad H, Nederveen AJ, van der Heide UA, van Moorselaar RJ, Hofman P, Lagendijk JJ. Clinical feasibility study for the use of implanted gold seeds in the prostate as reliable positioning markers during megavoltage irradiation. *Radiother Oncol*. 2003;67:295-302.
9. Malone S, Crook JM, Kendal WS, Szanto J. Respiratory-induced prostate motion: quantification and characterization. *Int J Radiat Oncol Biol Phys*. 2000;48:105-9.
10. Litzenberg D, Dawson LA, Sandler H, et al. Daily prostate targeting using implanted radiopaque markers. *Int J Radiat Oncol Biol Phys*. 2002;52:699-703.
11. Wu J, Haycocks T, Alasti H. Positioning errors and prostate motion during conformal prostate radiotherapy using on-line isocentre set-up verification and implanted prostate markers. *Radiother Oncol*. 2001;61:127-33.
12. Balter JM, Lam KL, Sandler HM, Littles JF, Bree RL, Ten Haken RK. Automated localization of the prostate at the time of treatment using implanted radiopaque markers: technical feasibility. *Int J Radiat Oncol Biol Phys*. 1995;33:1281-6.
13. Poggi MM, Gant DA, Sewchand W, Warlick WB. Marker seed migration in prostate localization. *Int J Radiat Oncol Biol Phys*. 2003;56:1248-51.
14. Kupelian PA, Willoughby TR, Meeks SL, et al. Intraprostatic fiducials for localization of the prostate gland: monitoring intermarker distances during radiation therapy to test for marker stability. *Int J Radiat Oncol Biol Phys*. 2005;62:1291-6.
15. Langenhuijsen JF, van Lin EN, Kiemeney LA, et

- al. Ultrasound-guided transrectal implantation of gold markers for prostate localization during external beam radiotherapy: complication rate and risk factors. *Int J Radiat Oncol Biol Phys.* 2007;69:671-6.
16. Henry AM, Wilkinson C, Wylie JP, Logue JP, Price P, Khoo VS. Trans-perineal implantation of radio-opaque treatment verification markers into the prostate: an assessment of procedure related morbidity, patient acceptability and accuracy. *Radiother Oncol.* 2004;73:57-9.
17. Sieber PR, Rommel FM, Theodoran CG, Hong RD, Del Terzo MA. Contemporary prostate biopsy complication rates in community-based urology practice. *Urology.* 2007;70:498-500.
18. Ghani KR, Dundas D, Patel U. Bleeding after transrectal ultrasonography-guided prostate biopsy: a study of 7-day morbidity after a six-, eight- and 12-core biopsy protocol. *BJU Int.* 2004;94:1014-20.
19. Chung PW, Haycocks T, Brown T, et al. On-line aSi portal imaging of implanted fiducial markers for the reduction of interfraction error during conformal radiotherapy of prostate carcinoma. *Int J Radiat Oncol Biol Phys.* 2004;60:329-34.
20. Pouliot J, Aubin M, Langen KM, et al. (Non)-migration of radiopaque markers used for on-line localization of the prostate with an electronic portal imaging device. *Int J Radiat Oncol Biol Phys.* 2003;56:862-6.