

Leiomyoma of the Urinary Bladder - A Case Report and Brief Review of Literature

Syed Sajjad Nazir*, Aakifa Maqbool, Muneer Khan

Department of Surgery and Urology, Government Medical College Srinagar, Kashmir, India

Abstract

Bladder leiomyomas are rare benign mesenchymal tumors which account for less than 0.43 % of all bladder tumors with approximately 200 cases described in the literature. A case of urinary bladder leiomyoma is presented that was initially diagnosed to have bladder carcinoma on account of one week history of gross painless hematuria. The clinical presentation, imaging findings and management of this rare benign tumor is described.

Keywords: Leiomyoma, Urinary Bladder, Benign Neoplasm

Introduction

Leiomyoma of the bladder is an uncommon benign tumor; however, it is the most frequent benign neoplasm accounting 0.43 % of bladder tumors (1). The majority of the patients (about 75 %) are young and middle aged (2). Common presenting features are usually obstructive in nature.

We describe here a case of urinary bladder leiomyoma in a young female with gross painless hematuria. Although not initially suspected, the diagnosis of the urinary bladder leiomyoma was subsequently histologically confirmed. Thus leiomyoma should be considered in differential diagnosis of any bladder tumor.

Case report

A 30-years old married female presented with gross painless total hematuria with amorphous type of clots of one week duration. She also complained of frequency and urgency for past 3 months. Physical examination revealed that patient was grossly pale,

anemic, dyspneic and went into acute urinary retention prior to admission. Routine blood examination showed Hb 6.4 g/dl, blood leucocytes 7,800/mm³ and Platelet count 151,000/mm³. Urine examination showed RBC full field. Blood urea / serum creatinine were within normal limits. Ultrasonography revealed a large mixed echogenic mass in the bladder posteriorly almost occupying whole of the bladder. Patient was stabilised and received 4 units of blood over a period of 2 days. CECT abdomen and pelvis showed a large bladder mass arising from the fundus and protruding into the bladder lumen (Fig 1). Cystoscopy was performed for clot retention and after clot evacuation findings revealed a large nodular whitish grey mass protruding into the bladder lumen from the fundus while rest of the bladder was normal and a biopsy was taken at the end of the procedure. The biopsy

*Correspondence:

Syed Sajjad Nazir, MD

R/o 171, Rawalpura housing colony, Sanant Nagar Srinagar
Kashmir, Jammu & Kashmir, India

Email: drsyedsajjad@yahoo.co.in

Received: 16 Apr 2009

Accepted: 21 Apr 2009

of the tissue fragments revealed inflammation of the mucosa and scanty smooth muscle cells without atypia suggestive of Leiomyoma. Although initially thought that it is a carcinoma of the bladder but biopsy revealed leiomyoma. The patient underwent partial cystectomy due to the large size of the tumor, which revealed a large intraluminal mass with intact mucosa with several blood clots in the bladder arising from the fundus and anterior wall of the bladder.

HPE findings were suggestive of leiomyoma (Fig 2). Post operative period was uneventful and at the last follow up after 1 year, the patient was doing well.

Discussion

Equal incidence in men and women have been reported (3) as well as female prepondence (4) which may be attributed to the increase use of pelvic sonography in female patients (1). The etiology of these tumors remains unknown. It is proposed that leiomyomas may arise from chromosomal abnormalities (1), hormonal influences, bladder musculature infection, perivascular inflammation or dysontogenesis (5). Leiomyomas may be asymptomatic but usually present with obstructive symptoms (49%), irritative symptoms (38%) and hematuria (11%) (5). These tumors may be classified into three different locations, Endovesical, Intramural and Extravesical. Endovesical is the most common

form, corresponding to 63–86% of the cases, while intramural occurs in 3–7% and extravesical in 11–30 % (3, 5). Based on cystoscopy findings, an intramural leiomyoma can be distinguished from an endovesical tumor. Endovesical tumors refer to the submucosal growth of leiomyoma, first described by Campbell and Gislason (6), are usually pedunculated or polypoid while intramural myomas are usually well encapsulated and surrounded by bladder wall muscle. The endovesical form usually causes irritative or obstructive symptoms or gross hematuria (2) that results in detection (1) as in our case. Intramural form especially small tumor may not produce symptoms.

Radiologically, the appearance of these tumors on US, mainly those with endovesical growth, is very characteristic. They appear as a homogenous smooth mass with peripheral hyperechogenicity (4, 7). CT scans can accurately locate these neoplasms, but are inadequate to clarify the liquid or solid nature of the lesion, and its relation with surrounding structures. Conversely, MRI can show more specific signs of a mesenchymal tumor and clearly depict its relation to the bladder wall (8). Not diagnostic, leiomyomas are characterized on MRI as low intensity masses both on T1 and T2 weighted sequences with smooth surfaces that resemble uterine leiomyoma. Variable pattern of

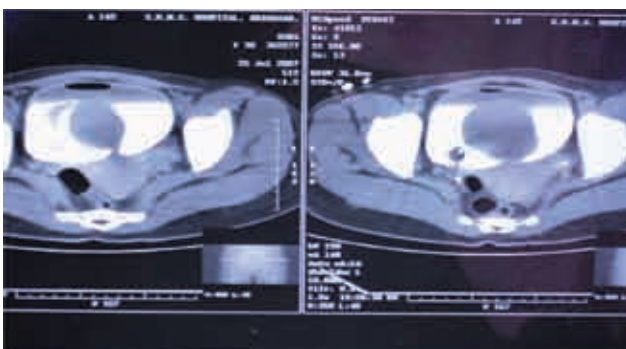


Figure 1. Contrast enhanced CT Scan of the pelvis shows intraluminal polypoidal enhancing mass projecting into the bladder lumen.

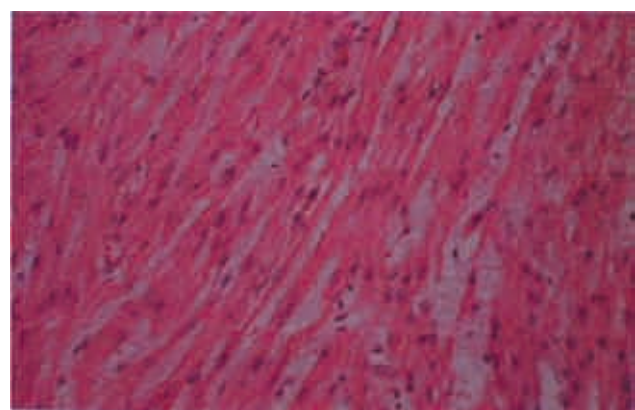


Figure 2. H/E (magnified x 400) revealed interlacing fascicles of spindle cells with usual cellularity & focal hyaline degeneration with eosinophilic fibrillar cytoplasm & uniform vesicular & bilateral blunt nuclei.

enhancement is observed after injecting gadolinium, some leiomyomas are homogenously enhanced, while others are not (2, 9, 10). Areas of cystic degeneration may appear as hyperintense signal on T2 and do not enhance with contrast. Anyway no imaging technique can safely exclude malignancy and so histological characterization should always be attempted prior to invasive therapeutic procedures.

Intramural tumors may be managed according to their size & location. Small easily accessible tumors may be treated with TURBT, while unfavourable positioning & recognition difficulties may require segmental resection as in our case or laparoscopic partial cystectomy (11).

Histopathologically, leiomyoma of the bladder is composed of fascicles of smooth muscle fibres separated by connective tissues, are noninfiltrative smooth muscle tumor lacking mitotic activity, cellular atypia and necrosis.

Treatment is delivered primarily by their size and anatomical location (7). In Golusoff et al review, 62% were treated with open resection while 38% were treated with TURBT (10).

18% necessitated reoperation due to incomplete resection in TURBT group, while none required a second procedure in open group.

Although bladder leiomyomas are rare, they should be discarded in patients with a prolonged history of urinary tract symptoms. In symptomatic patients surgery is a very effective treatment, associated with the low reoperation rate and absence of recurrence. Benign nature and excellent prognosis of bladder leiomyoma after surgical excision leaves the patient asymptomatic (7).

References

1. Cornella JL, Larson TR, Lee RA, Magrina JF, Kammerer-Doak D. Leiomyoma of the female urethra and bladder: report of twenty-three patients and review of the literature. *Am J Obstet Gynecol.* 1997 Jun;176(6):1278-85.
2. Chen M, Lipson SA, Hricak H. MR imaging evaluation of benign mesenchymal tumors of the urinary bladder. *AJR Am J Roentgenol.* 1997 Feb;168(2):399-403.
3. Knoll LD, Segura JW, Scheithauer BW. Leiomyoma of the bladder. *J Urol.* 1986 Oct;136(4):906-8.
4. Kabalin JN, Freiha FS, Niebel JD. Leiomyoma of bladder. Report of 2 cases and demonstration of ultrasonic appearance. *Urology.* 1990 Mar;35(3):210-2.
5. Goluboff ET, O' Toole K, Sawczuk IS. Leiomyoma of bladder: report of case and review of literature. *Urology.* 1994 Feb;43(2):238-41.
6. Campbell EW, Gislason GJ. Benign mesothelial tumors of the urinary bladder: review of literature and a report of a case of leiomyoma. *J Urol.* 1953; 70(5):733.
7. Soloway D, Simon MA, Milikowski C, Soloway MS. Epithelioid leiomyoma of the bladder: an unusual cause of voiding symptoms. *Urology.* 1998 Jun;51(6):1037-9.
8. Sundaram CP, Rawal A, Saltzman B. Characteristics of bladder leiomyoma as noted on magnetic resonance imaging. *Urology.* 1998 Dec;52(6):1142-3.
9. Wong-You-Chong, JJ, Woodward PJ, Manning MA, Sesterhenn IA. From the archives of the AFIP: Neoplasm of the bladder: Report of two cases and demonstration of ultrasonic appearance. *Urology* 1990;35(3):210-12.
10. Wong FK, Wong YFM, Ma KF, Lui CY. Urinary bladder leiomyoma. *J HK Coll Radiol.* 2002; 5:193-6
11. Lyons TL, Lee T, Winer WK. Laparoscopic removal of a bladder leiomyoma. *J Am Assoc Gynecol Laparosc.* 1998 Nov;5(4):423-6.