



Botulinum toxin-A injections in children with neurogenic bladder

Pawel Kroll ¹, Andrzej Jankowski ¹, Jolanta Soltysiak ², Marek Murias ³, Magdalena Skrzypczak ⁴,
Jacek Zachwieja ^{2*}

¹ Department of Pediatric Surgery, Traumatology and Urology, Poznan University of Medical Sciences, Szpitalna, Poznan, Poland

² Department of Pediatric Nephrology, Poznan University of Medical Sciences, Szpitalna, Poznan, Poland

³ Department of Toxicology, Poznan University of Medical Sciences, Szpitalna, Poznan, Poland

⁴ Department of Human Biological Development, Institute of Anthropology, Szpitalna, Poznan, Poland

ARTICLE INFO

Article Type:
Original Article

Article history:
Received: 27 July 2010
Revised: 27 Aug 2010
Accepted: 4 Sep 2010

Keywords:
Neurogenic bladder
Botulinum toxin
Urodynamics

ABSTRACT

Background: Botulinum-A toxin (BTX) administration appears to be useful in patients with high pressure neurogenic bladder.

Objectives: The aim of this study was to evaluate the usefulness of cystoscopic injections of BTX in the detrusor wall in the treatment of children with overactive neurogenic bladder dysfunctions.

Patients and Methods: The prospective, non-placebo controlled study was conducted with the approval of Local Ethics Committee. The study group consisted of 31 girls and 34 boys with neurogenic bladder overactivity, aged from 1 to 14 and treated with Botulinum-A toxin (Dysport, Ipsen).

Results: Both values of volumes of the catheterized urine and bladder volumes in urodynamic studies increased significantly after the therapy and it proved that the younger patient the more effective the percentage of volumes growth.

Conclusion: The results showed that endoscopic administration of BTX improved functional parameters of urinary bladder in cases of children with neurogenic bladder and the method might represent an alternative approach to operative reduction of intravesical pressures.

© 2011 Kowsar M.P.Co. All rights reserved.

► Implication for health policy/practice/research/medical education:

Discussing about the best method of treatment in patients with neurogenic bladder created lots of challenges among researchers in the field. This manuscript tries to declare one of the treatment method in a sample of patients.

► Please cite this paper as:

Kroll P, Jankowski A, Soltysiak J, Murias M, Skrzypczak M, Zachwieja J. Botulinum toxin-A injections in children with neurogenic bladder. *Nephro-Urol Mon.* 2011;3(2):125-128.

Background

The proper function of the lower urinary tract involves periodic and planned urination in amounts appropriate for a patient's age while preserving continence in the storage phase. In case of children with neurogenic bladder, decreased functional bladder capacity is related to detrusor overactivity, low bladder compliance and incompetent function of urethral sphincters (1). The low bladder capacity may be accompanied by additional symptoms, such as urgency, frequency, nocturia, day time urine incontinence or nocturnal enuresis. If bladder overactivity is associated with high

intravesical pressure, additional complications may develop, such as recurrent urinary tract infections or secondary anatomic lesions in urinary tract (bladder diverticula, megaureter or vesico-ureteric reflux) (1-4). Abnormal function of the lower urinary tract may be caused by congenital malformations or acquired diseases of the nervous system and in such cases the term of neurogenic bladder is used. Non-neurogenic dysfunctions are recognized if no neurological cause or defect in the nervous system can be detected. In cases of children, neurogenic bladder develops most frequently due to dysraphic malformations of spinal cord and both result in significant decrease in sensation of the bladder and in the sensation of the urethra. Therefore, the patient loses control over function of his/her urinary tract, which is manifested by his/her inability to void effectively urine in a single large portion and, on the other hand, by uri-

* Corresponding author at: Jacek Zachwieja, Department of Pediatric Nephrology, Poznan University of Medical Sciences, Szpitalna, Poznan, Poland.

E-mail address: j.zachwieja@mp.pl

© 2011 Kowsar M.P.Co. All rights reserved.

nary incontinence. In patients suffering from the above presented neurogenic dysfunctions, the treatment is based on clean intermittent catheterization and pharmacological correction of bladder overactivity, together with a reduction of the intravesical pressure (1). Pharmacotherapy of the overactive bladder takes advantage of oral anti-cholinergic drugs. Nevertheless, in cases of some children, such an approach fails to decrease the detrusor pressure, and/or patient complains of troublesome side effects. In such cases, low bladder capacity and, linked to it, the urinary incontinence persists (2, 4-7). Moreover, when the conservative approach gives no improvement, complicated surgical procedures aimed at the reconstruction of the urinary system are suggested to the patients. At present, augmentation of urinary bladder with intestinal walls is believed to represent the most effective way of surgical correction of the urinary bladders' functional parameters, of increasing its capacity and decreasing intravesical pressure. With the cases of younger children, the procedure of operative cystostomy provides an effective way to decrease intravesical pressures (1, 3, 8). During the last few years many reports appeared on favourable results of Botulinum-A toxin (BTX) administration in patients with high pressure neurogenic bladder. Most of these reports are related to the treatment of adult patients (2, 9-12).

Objectives

The aim of this study was to evaluate the usefulness of cystoscopic injections of Botulinum-A toxin (BTX) in the detrusor wall in the treatment of children with overactive neurogenic bladder dysfunctions.

Patients and Methods

The prospective, non-placebo controlled study was conducted with the approval of Local Ethics Committee. After the urodynamic investigations, all the children were formerly treated conservatively using clean intermittent catheterization and oral oxybutynine. Children with neurogenic bladder where no improvement was noted were qualified for the procedure of endoscopic injections of BTX. The lack of improvement was concluded when high detrusor Leak Point pressures (above 40 cm H₂O) and low urinary bladder capacity (below 70% of the age-appropriate value) were documented in urodynamic tests. Sixty-five children with neurogenic bladder overactivity were included in this study. The group consisted of 31 girls, and 34 boys, aged 1 to 14. Body weight was ranged between 8.5 and 46.5 kg. Sixty-one of them had been previously operated myelomeningocele, 3 of them had sacral agenesis in 1 bladder dysfunction caused by cerebral palsy. In those cases, neuro-urologic examination and urodynamic investigations were performed. In all cases decreased bladder capacity and detrusor overactivity with urine incontinence was estimated despite of oral oxybutynin treatment. Cystometries were performed in a routine due to the recommendation of the Committee on Standardisation of the I.C.S. Five to eight French; double lumen catheters were used according to the age of a child for filling the bladder and measuring Pves. Subsequently, Pabd was controlled with the rectal manometric line. The Hjalmas rule: Vol = 30 + (age x 30), was applied to assess the maximal capacity of the bladder (13). The maximal dose of Botulinum-A toxin (Dysport, Ipsen) administered was 50 units per kg body weight

which was accepted by the Local Ethics Committee with the maximum dose per patient up to 500 units. The dose was diluted in 10 ml 0.9% NaCl. Cystoscopes with operative channel were used. The diameter of the instrument was adjusted appropriately to the age and size of urethra of a given patient. Size and shape of the urethra, pattern of bladder walls and morphology of ureter ostia were evaluated during cystoscopy. The bladder was partially filled with 0.9% NaCl solution. A rigid needle was introduced through the operative channel. If a child was unsettled or stated any pain during the endoscopic procedure, intravenous neuroleptoanalgesia was administered. Twenty consecutive sites of bladder dome were carefully injected each with 0.5 ml of the solution, taking care not to inject the preparation into regions of ureter ostia. Following the procedure urine was evacuated from the bladder. It was recommended to discontinue administration of oral anticholinergic drugs, and to continue intermittent bladder catheterization, to control volumes of the catheterized urine, monitoring of the "dryness" periods and incontinence episodes and to continue with antimicrobial prophylaxis. Many of the patients were previously treated with other drugs, including alpha-blockers, but in none of them the therapy of bladder dysfunction was neither changed one month before BTX injection nor during the observation time. Subsequently, the patients were monitored by phone interviews and follow-up visits to the hospital. Controlling urodynamic tests were performed 5 to 14 days after the endoscopic procedure. The changes in bladder volume and in the continence were estimated in urodynamic evaluations. As all of the patients were on clean intermittent catheterization, we did not calculate residual urine. We excluded children with vesico-ureteric reflux from this study.

Statistics

The qualitative and quantitative analyses were carried out using the Statistica 7.1 package of statistical programs (StatSoft, Inc. 2007 Statistica for Windows). Statistical analyses were performed using nonparametric tests: the Wilcoxon signed rank sum test and the U Mann-Whitney test. A p-value of less than 0.05 was considered as statistically significant.

Results

In all cases of the 65 children the procedure was performed successfully. The mean age of patients was 6.7 years (SD: 3.3; Min - Max: 1-14). The post-procedure course of all 65 patients was documented by the data of daily voiding records and urodynamic tests. The most important observations for this study were the recordings of bladder capacities at catheterization derived from "voiding diaries". The maximal catheterized bladder volume increased in 49 patients with the improvement in the continence. The values of the mean maximal catheterized volume rose from 78.3 to 118.8 ml ($p = 0.0005$) (Table 1). Urodynamic tests were also analyzed. Maximal volumes at Leak Point increased significantly in 51 children. The values of the mean maximal volume at the Leak Point rose from 79.1 ml to 123.0 ml ($p = 0.0002$) (Table 1). The increase in bladder volume was mostly caused by the inhibition of detrusor overactivity. Nevertheless, the decrease of bladder wall compliance was also seen in some cases. We also analyzed changes in Leak Point pressures. They did not change significantly in this group of patients. The effect of

bladder enlargement persisted for over 6 months in case of 47 children, and in 6 children the effect of BTX injections persisted for more than 12 months. The descriptive statistics (mean values, SD, minimum and maximum) of the analyzed parameters at baseline and after BTX treatment are presented in *Table 1*. In order to find out whether and how analyzed parameters were changing with given patients, along with treatment, therapy-related changes in these characteristics were analyzed. The Wilcoxon test results indicated significant statistical differences of the analyzed parameters between groups before and after the treatment. Values of all parameters increased significantly after therapy (*Table 1*, *Figure 1*). We are still gathering the data on the side-effects of BTX injections; however, we did not observe such typical complications as depression nor anxiety. In some cases blurred vision, while in others, weakness of extremities was observed. The most common complications seen were elevated body temperature and hematuria.

Discussion

Intradetrusor, endoscopic administration of BTX represents an alternative to operative treatment (1, 3, 6). Action of BTX involves a reversible, periodic blocking of cholinergic conductance at the myo-neural junction. The toxin penetrates the cell membrane and reaches terminals of nerve cells blocks presynaptic release of acetylcholine (2, 6, 10). Cholinergic fibres are located in high numbers in the walls of the dome of the urinary bladder - the detrusor muscle. The bladder dome is located above ureter ostia functions as the detrusor muscle. This part of the bladder controls storage of urine and at the voiding phase it participates in urine evacuation. Children, who have been qualified to receive BTX treatment, demonstrated a lack of improvement despite conservative treatment. A decreased bladder capacity used to lead to urinary incontinence, understood as leakage of urine from the bladder after less than two hours following catheterization in case of a patient drinking normal amounts of

Table 1. Urodynamic parameters at baseline and after Botulinum-A toxin treatment

Urodynamic parameters	before treatment		after treatment		Wilcoxon test	
	mean ± SE	Min-Max	mean ± SE	Min-Max	Z	p
max catheterized Vol	78.3 ± 36.4	30.0-210.0	118.8 ± 44.5	50.0-260.0	6.77	0.0005
max Vol Leak Point	79.1 ± 38.1	30.0-240.0	123.0 ± 46.9	40.0-270.0	6.77	0.0002

Table 2. Changes of bladder capacity and leak point after treatment in comparison to baseline

	Mean ± SE	Min - Max
% of growth max catheterized Vol after BTX	61.6 ± 37.4	0.0 - 140.0
% of growth max Vol Leak Point after BTX	65.0 ± 35.6	0.0 - 166.7

fluids. In the literature, the efficiency of BTX has been well documented in cases of adults with either neurogenic or non-neurogenic dysfunctions of urinary tract. In urology, Botulinum toxin has been mainly used to be injected into detrusor muscles in order to decrease intravesical pressure in the storage phase but it has also been applied to sphincters in order to abolish detrusor-sphincters dyscoordination in the voiding phase. The efficiency of BTX injections to the detrusor has been noted in 60-80% of patients (6, 7, 9-12, 14). A toxin injection is effective with detrusor-sphincter dyssynergia when injected either transurethrally or transperineally. External urethral sphincter pressure, voiding pressure and post-void residual volume decreased after the treatment. The effect lasts between 2 to 12 months depending on the number of injections. The best indications seem to be multiple sclerosis and incomplete spinal cord injury patients suffering from neurogenic detrusor overactivity and detrusor-sphincter dyssynergia (6, 9, 12). Repeated intradetrusor Botulinum toxin A injections are a valuable treatment option for the neurogenic detrusor overactivity over a period of several years. The beneficial effect of the toxin in clinical and urodynamic parameters remains constant after the repeated injections (5, 11). The reports on efficacy of BTX in the treatment of neurogenic urinary bladder in children have been far less frequent (1, 3, 5, 7, 8). The aim of our study was to evaluate the usefulness of cystoscopic injections of BTX in the detrusor wall in the treatment of children with overac-

tive neurogenic bladder dysfunctions. The BTX preparations available in the Polish market include two preparations, Dysport and Botox. They are not equivalent and it is assumed that a single unit of Botox manifests activity of 4 to 5 units of Dysport. As far as bladder overactivity in adult cases is concerned a dosage of BTX has been established at 500 to 1500 units of toxin-A of the Ipsen Company (Dysport) or 100 to 300 units of toxin-A of the Allergan Company (Botox). In cases of children, respectively 50 units/kg body weight of Dysport or 10 units/kg body weight of Botox have been used. Such a dose of the toxin is administered in separate doses into 10 to 20 sites of bladder dome, paying attention not to administer the toxin in the vicinity of ureter ostia and to avoid paralysis of the ureteral anti-reflux mechanism. The observations of bladder capacities at catheterization were derived from "voiding diaries". Maximal catheterized bladder volume increased in most patients with the improvement in the continence. This observation was also confirmed by urodynamic tests. Activity of BTX in urinary bladder has been described to persist for 6 to 9 months and even more than 12 months. This has been confirmed by our observations. The effect of bladder enlargement persisted for over 6 months in case of 47 children, and in 6 children the effect of BTX injections persisted for more than 12 months (*Figure 2*). The results are quite promising. Moreover, the procedure can be repeated. According to some reports, repeated administration of BTX has been found equally effective in its first application (5, 6,

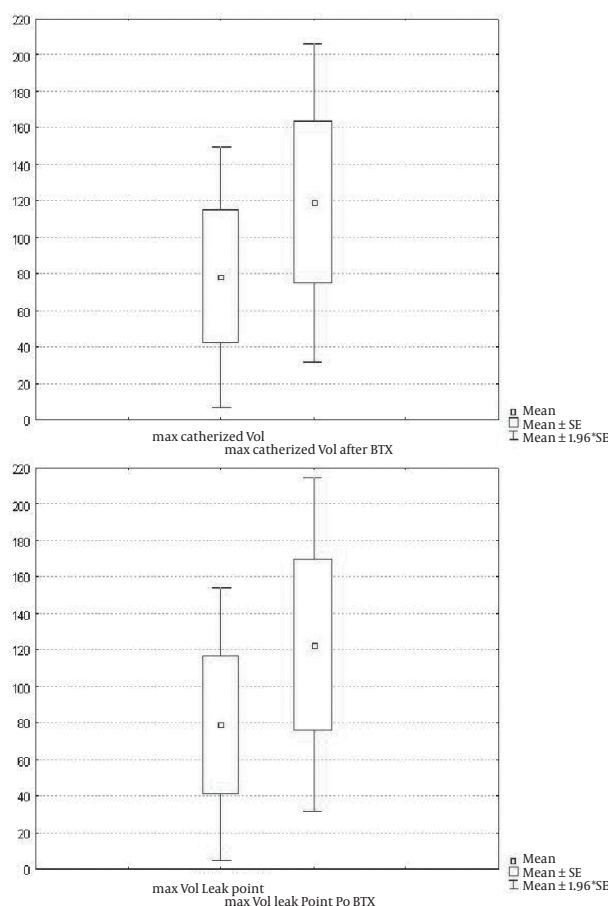


Figure 1. Basic urodynamic parameters at baseline and after Botulinum-A toxin treatment

11, 12, 14). In our opinion endoscopic administration of BTX should be considered as an alternative method in the following cases: lack of efficiency of conservative treatment, hypersensitivity to oral anti-cholinergic drugs or side effects resulting from their administration and lack of parental consent to surgical treatment (cystostomy, augmentation). If it is considered to be an alternative treatment to surgery, than the obvious limitation of this therapy is the transient effect of the endoscopic procedure (1-3). Although, many questions remain unanswered regarding the optimal use of this minimally invasive option for urologic applications, the opportunity for expanding indications will provide urologists with more options for addressing difficult challenges in voiding dysfunction (2, 14). The results obtained from the study confirmed that: 1) Endoscopic administration of Botulinum-A toxin improves functional parameters of urinary bladder in cases of children with neurogenic bladder; 2) The method may represent an alternative approach to operative reduction of intravesical pressures.

Financial support

None declared.

Conflict of interest

None declared.

Acknowledgement

None declared.

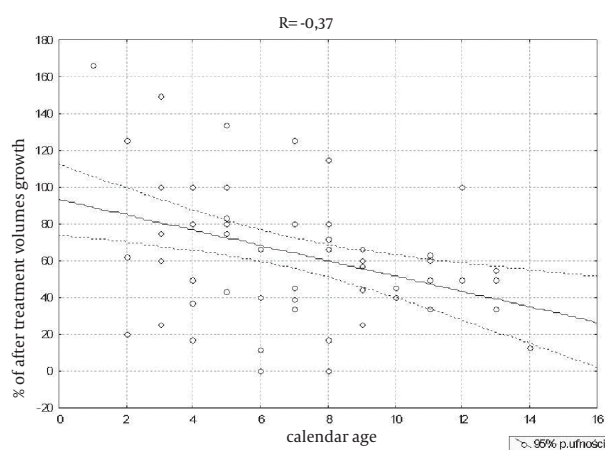


Figure 2. Correlation between patient's age and change in bladder capacity after treatment

References

- Wein AJ. Neuromuscular dysfunction of the lower urinary tract and its treatment. In: Walsh PC, editor. *Campbell's Urology*. 7th ed. Philadelphia: WB Saunders Company; 1998. p. 953-1006.
- Frenkl TL, Rackley RR. Injectable neuromodulatory agents: botulinum toxin therapy. *Urol Clin North Am*. 2005;**32**(1):89-99.
- Marte A, Vessella A, Cautiero P, Romano M, Borrelli M, Noviello C, et al. [Efficacy of toxin-A Botulinum for treating intractable bladder hyperactivity in children affected by neuropathic bladder secondary to myelomeningocele: an alternative to enterocystoplasty]. *Minerva Pediatr*. 2005;**57**(1):35-40.
- Verpoorten C, Buyse GM. The neurogenic bladder: medical treatment. *Pediatr Nephrol*. 2008;**23**(5):717-25.
- Altaweel W, Jednack R, Bilodeau C, Corcos J. Repeated intradetrusor botulinum toxin type A in children with neurogenic bladder due to myelomeningocele. *J Urol*. 2006;**175**(3 Pt 1):1102-5.
- Leippold T, Reitz A, Schurch B. Botulinum toxin as a new therapy option for voiding disorders: current state of the art. *Eur Urol*. 2003;**44**(2):165-74.
- Riccabona M, Koen M, Schindler M, Goedele B, Pycha A, Lusuardi L, et al. Botulinum-A toxin injection into the detrusor: a safe alternative in the treatment of children with myelomeningocele with detrusor hyperreflexia. *J Urol*. 2004;**171**(2 Pt 1):845-8; discussion 8.
- Schulte-Baukloh H, Michael T, Sturzebecher B, Knispel HH. Botulinum-a toxin detrusor injection as a novel approach in the treatment of bladder spasticity in children with neurogenic bladder. *Eur Urol*. 2003;**44**(1):139-43.
- Kuo HC. Effect of botulinum a toxin in the treatment of voiding dysfunction due to detrusor underactivity. *Urology*. 2003;**61**(3):550-4.
- Popat R, Apostolidis A, Kalsi V, Gonzales G, Fowler CJ, Dasgupta P. A comparison between the response of patients with idiopathic detrusor overactivity and neurogenic detrusor overactivity to the first intradetrusor injection of botulinum-A toxin. *J Urol*. 2005;**174**(3):984-9.
- Reitz A, Denys P, Fermanian C, Schurch B, Comperat E, Chartier-Kastler E. Do repeat intradetrusor botulinum toxin type a injections yield valuable results? Clinical and urodynamic results after five injections in patients with neurogenic detrusor overactivity. *Eur Urol*. 2007;**52**(6):1729-35.
- Schurch B, Hodler J, Rodic B. Botulinum A toxin as a treatment of detrusor-sphincter dyssynergia in patients with spinal cord injury: MRI controlled transperineal injections. *J Neurol Neurosurg Psychiatry*. 1997;**63**(4):474-6.
- Gierup J, Ericsson NO, von Hedenberg C. Urodynamic studies in boys with disorders of the lower urinary tract. IV. Congenital bladder neck obstruction. A pre- and postoperative study. *Scand J Urol Nephrol*. 1978;**12**(3):195-203.
- Smith CP, Nishiguchi J, O'Leary M, Yoshimura N, Chancellor MB. Single-institution experience in 110 patients with botulinum toxin A injection into bladder or urethra. *Urology*. 2005;**65**(1):37-41.