

In the name of God



Department of Internal Medicine

**Shiraz E-Medical Journal**  
**Vol. 6, No. 3 & 4, July and October 2005**

## **Viable Brain with bilateral Internal Carotid Occlusion, A Case Report.**

Kayvan Basiri \*, Farshad Ghadiri \*\*, Mohammad Saadatnia\*

\*Assistant professor, Department of Neurology, Department of Neurology, Alzahra Hospital, Isfahan University of Medical Science, Isfahan, Iran., \*\* Neurologist, Isfahan, Iran.

Correspondence: Dr. Kayvan Basiri, Department of Neurology, Alzahra Hospital, Isfahan University of Medical Science, Isfahan, Iran. E mail: [basiri@med.mui.ac.ir](mailto:basiri@med.mui.ac.ir), Telephone: +98 (913) 329-0713.

---

### **Abstract:**

Bilateral internal carotid artery (ICA) occlusion is extremely rare. The risk of stroke in patients with total ICA occlusion is significant. Outcome in patients with symptomatic ICA occlusion has not substantially improved over the years. We report a case of bilateral carotid occlusion in a middle aged woman. She was a healthy woman that was presented with slight numbness in her right hand. Duplex Ultra-sonography demonstrated a homogenous plaque in origin of Right Internal Carotid Artery (RICA) that caused 90% stenosis, and total occlusion of Left Internal Carotid Artery (LICA). Cervical Magnetic Resonance Angiography (MRA) confirmed occlusion of LICA and 90% stenosis of RICA. Patient was referred for right sided Carotid End Arterectomy(CEA).Unexpectedly in follow up Digital Subtraction Angiography (DSA), one week after surgery; total occlusion of both ICAs was observed.. After 12 months of follow up; despite bilateral ICA occlusion, she is well, active, and productive with completely normal neurological examination.

---

**Key Words: Bilateral internal carotid artery (ICA) occlusion, Stroke.**

## Introduction:

Bilateral internal carotid artery (ICA) occlusion is an extremely rare entity. Diagnosis is usually made by means of Duplex Ultrasonography (DU), Magnetic Resonance Arteriography (MRA), or by conventional or Digital Subtraction Angiography (DSA). The risk of stroke in patients with near total ICA occlusion is perceived to be high as stroke risk increases with severity of the stenosis.<sup>(1)</sup> There is a significant incidence of subsequent stroke, which seems to be related to the degree of stenosis in the contralateral internal carotid artery.<sup>(2)</sup> Patients with symptomatic ICA occlusion should be considered candidates for carotid endarterectomy (CEA).<sup>(3)</sup> When the opposite side is occluded and the stenosis is

removed ipsilaterally, a greater amount of compensatory collateral circulation can be measured on both the occluded side and the fully opened side.<sup>(4)</sup> Contra lateral CEA in patients with a symptomatic ICA occlusion induces cerebral hemodynamic improvement not only on the side of surgery but also on the side of the ICA occlusion.<sup>(5)</sup> Early stroke occurs in up to 7% of patients undergoing carotid endarterectomy.<sup>(6)</sup> Outcome in patients with symptomatic ICA occlusion has not substantially improved over the years.<sup>(7)</sup> We report a rare case of bilateral carotid occlusion in a middle aged woman without any significant consequences.

## Case Report:

A 50 years old female patient referred to our duplex Ultrasonography (DU) laboratory for evaluation of cervical vessels. She was a healthy woman that was presented with slight numbness in her right hand. Numbness began suddenly when she awaked in the morning ,ten days before examination. Sensory symptoms was not accompanied by any motor weakness. Her numbness was relived gradually during last three days. She had no history of such a problem in the past ,and also no history of other neurological deficits in other parts of the body. She never hospitalized before the present illness. She had no prior surgery, and no known drug allergies. Family history was negative. She denied smoking, and consumption of any drug or illicit substance. In review of systems, no fevers or chills were reported. The patient reported no blurry vision or double vision. She has suffered from occasional daily headaches for the last six months. She said that he had no difficulty swallowing or speaking, and had no problem in her ears and eyes. She reported no memory loss, and also no difficulty in walking and ambulation. No rashes or hair loss reported. Patient denies joint pain or swelling. Review of all other systems was

unremarkable. In physical examination she was a well nourished lady, and seems comfortable. She's pulse was 64 beats per minute, respiration rate of 18 per minute and blood pressure was 120/82 mm Hg. Sclera was not icteric, and mucus membranes had normal appearance. Neck was supple, and no thyromegaly or lymphadenopathy was detected. In Cardiovascular examination, S1 and S2 were normal with regular rate and rhythm. Auscultation of chest was clear bilaterally, with good air entry. Abdomen was soft and non tender with normal bowel sounds. In extremities no clubbing , cyanosis or rash was detected and range of motion was full. In neurological examination she was awake and alert, oriented to person, place, time and situation; and follows commands easily without hesitation. Speech was Clear and fluent with no dysarthria ; and normal repetition, comprehension, speed, volume, and prosody. Pupils were equal, round, and reactive to light. Visual fields were full to confrontation. Fundoscopic exam was normal. Extraocular movements were intact without nystagmus. Sensation was intact on both sides of the face. Facial expression was symmetric without definite weakness. Hearing

was intact to finger rub bilaterally. In GAG examination, palate was elevated in the midline without uvular deviation. Sternocleidomastoid strength 5/5 bilaterally. Tongue had no atrophy and was protruded in the midline. All muscles had normal tone and bulk. Strength was 5-/5 to 5/5 throughout, and symmetrical in all muscle groups that was tested. All tendon reflexes were 2/4, without

pathological reflexes or upper motor neuron signs. Slight sensory loss (pinprick and light touch) was detected in right hand and forearm. Finger-nose and heel-shin was normal, with no dysdiadochokinesis. Gait was intact with normal stance and arm swing. She was able to bear weight on heels and toes, and to tandem walk without difficulty. Brain CT scan was unremarkable (fig-1).

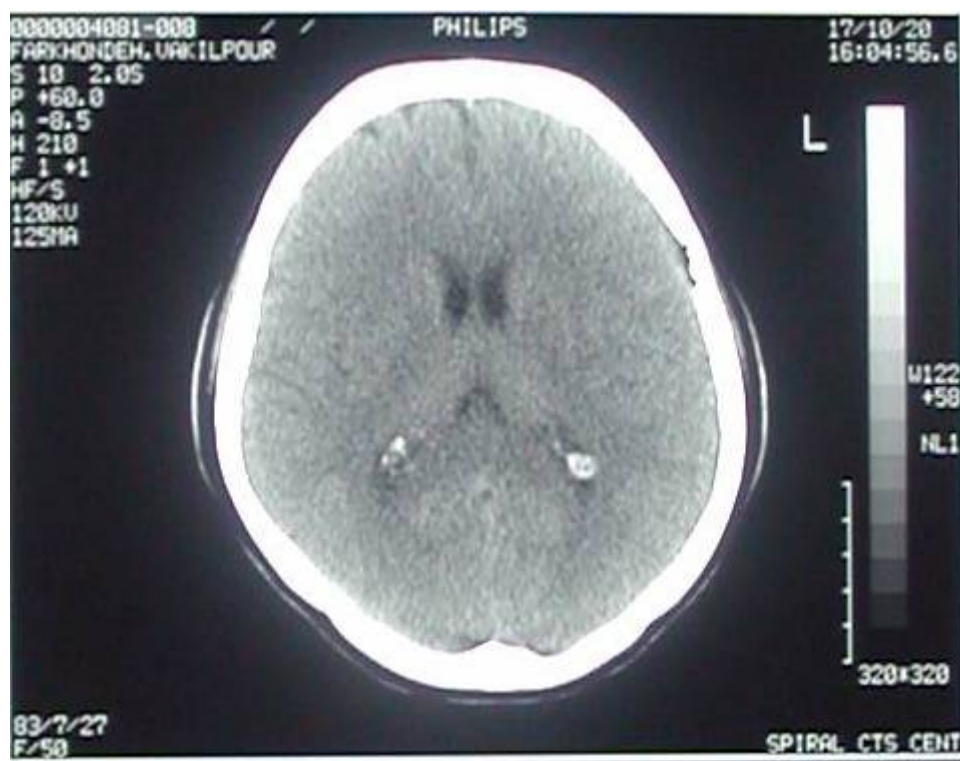

Fig-1: Normal brain CT scan.

Brain MRI revealed a small hyper intense area in left putamen and internal capsule (T2, FLAIR, and proton density); that was iso-intense in T1, and was correlated with an infarction in territory of left lenticulostriate artery (fig-2).

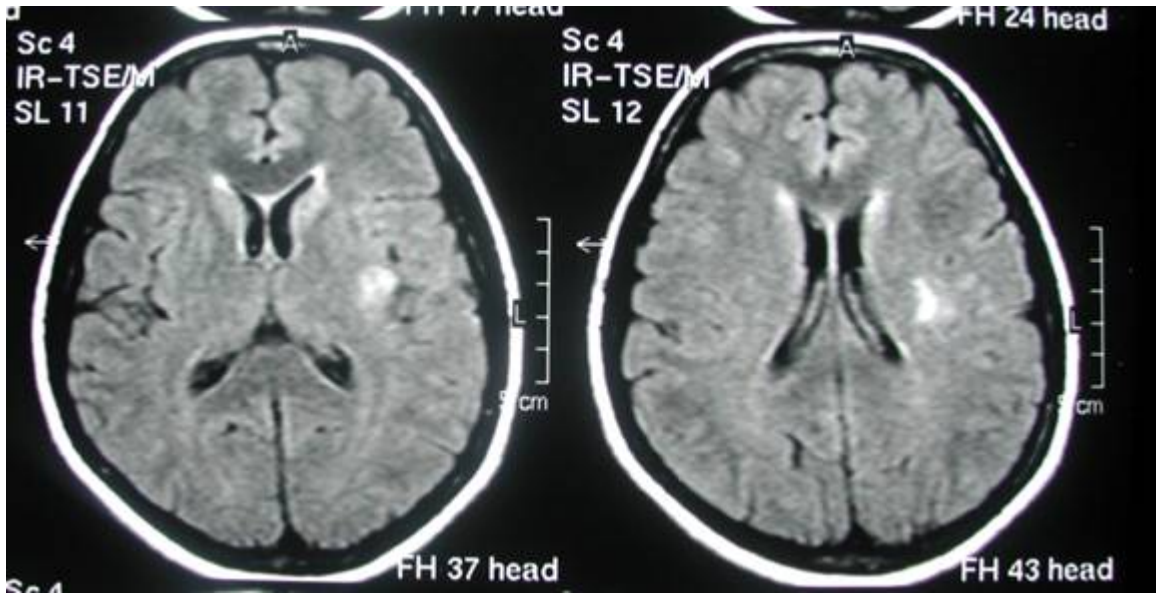


Fig-2: Hyper intense area in left basal ganglia and internal capsule (FLAIR).

Duplex Ultra-sonography demonstrated a homogenous plaque in origin of Right Internal Carotid Artery (RICA) that caused 90% stenosis, and total occlusion of Left Internal Carotid Artery (LICA) (fig3,4,5).

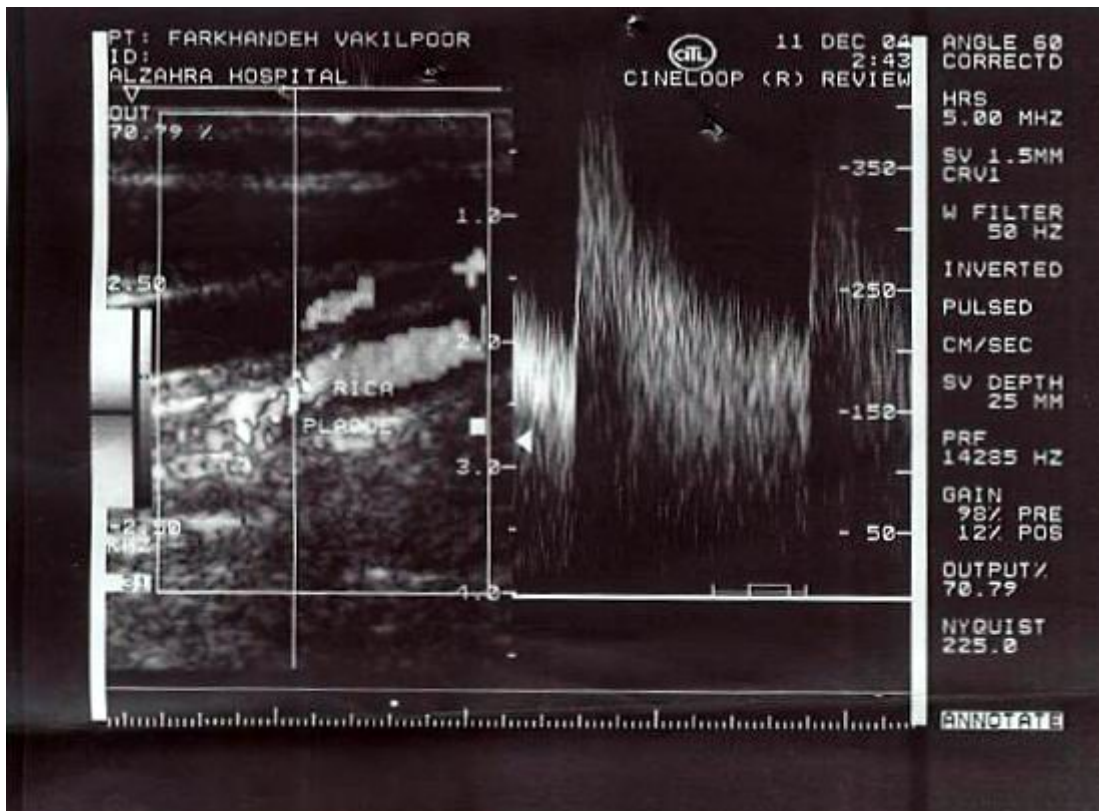


Fig-3: A homogenous plaque in origin of RICA that caused 90% stenosis

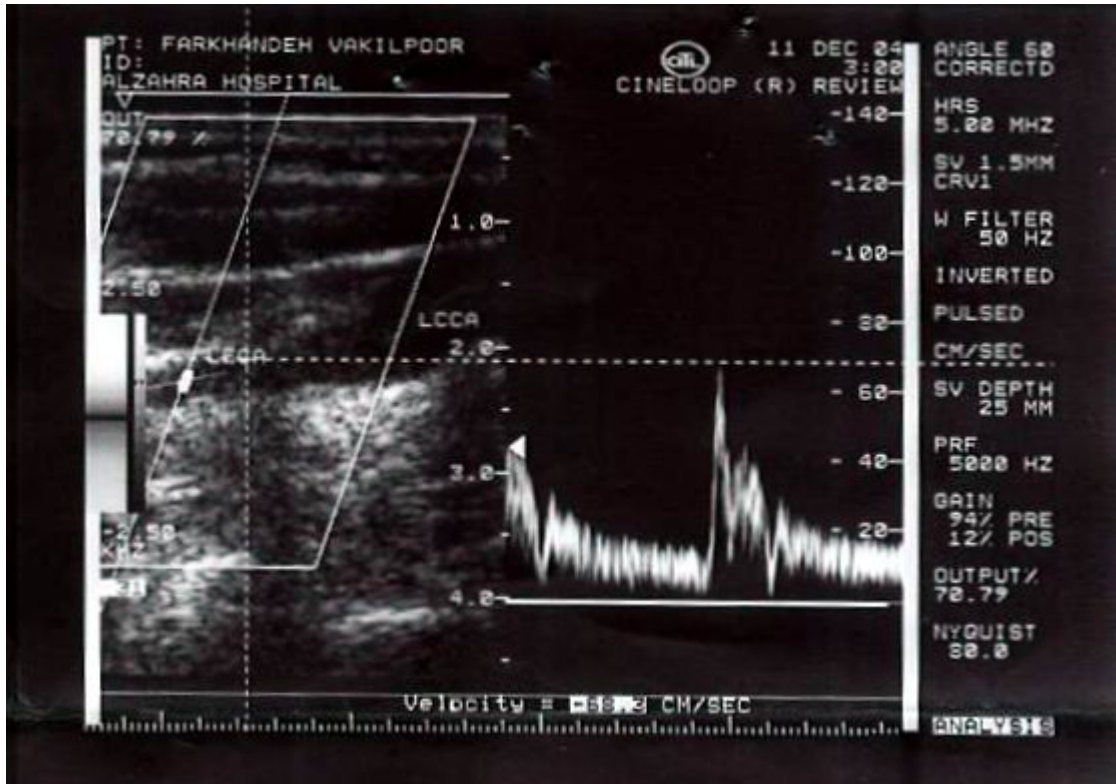


Fig-4: Normal flow pattern in Left Common Carotid Artery (LCCA), and Left External Carotid Artery (LECA); with no evidence of flow in Left Internal Carotid Artery (LICA).

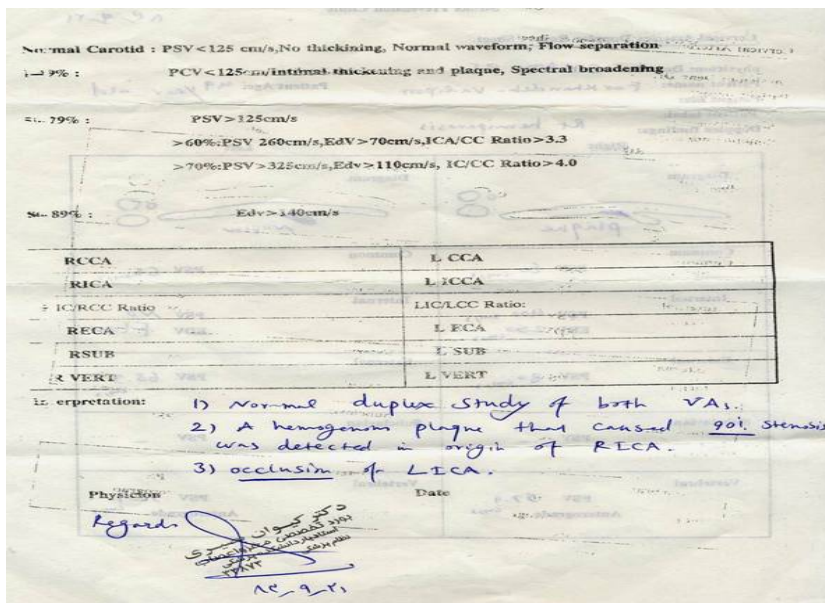


Fig-5: Duplex Ultra-sonography report.

Cervical Magnetic Resonance Angiography (MRA) confirmed occlusion of LICA and 90% stenosis of RICA (fig-6,7).

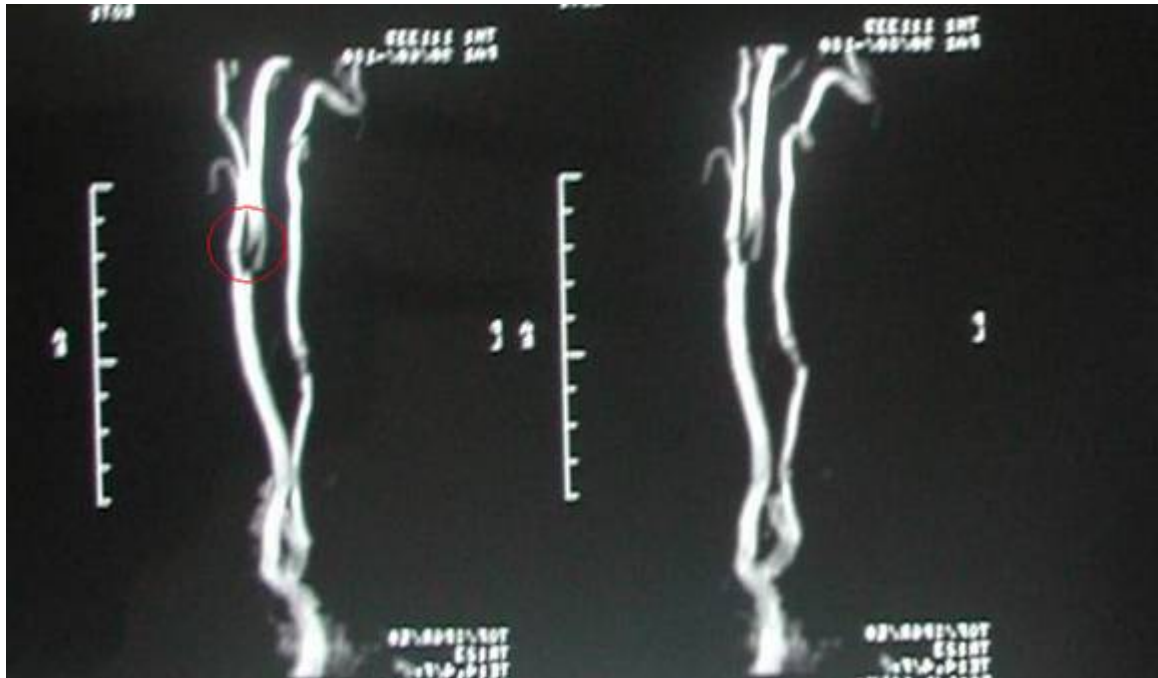

Fig-6: 90% stenosis of Right Internal Carotid Artery (RICA)

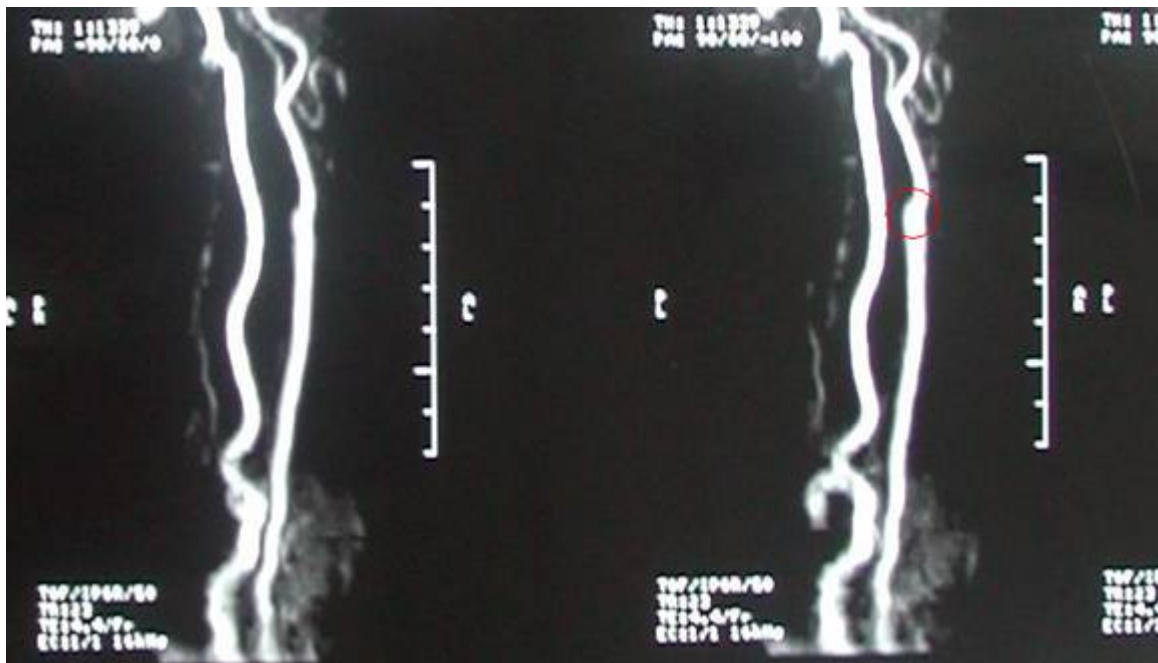


Fig-7: Total occlusion of Left Internal Carotid Artery (LICA).

Angiography of renal arteries was unremarkable. FBS, BUN, Cr, CBC, LDL, HDL, Total cholesterol, TG, and serum homocysteine level was normal; and tests for ANA, Anti-dsDNA, c ANCA, p ANCA, RF, ESR, CRP, C3, C4, CH50, LE Cell, Antiphospholipid (IgM, IgG), Anticardiolipin (IgM, IgG), and Lupus Anticoagulant was negative. Patient was referred for Carotid End Arterectomy (CEA). Right sided CEA was performed in capital of Tehran, by an experienced vascular

surgeon. Pre-operation and post-operation period was without complication and without any new clinical symptoms and signs. Unexpectedly in follow up Digital Subtraction Angiography (DSA), one week after surgery; total occlusion of both ICAs was observed. Medical treatment began and patient was followed for one year. She is well, active, and productive with completely normal neurological examination after 12 mos of follow up.

## Discussion:

This case is remarkable from several aspects. First: In this patient 90% stenosis of RICA was asymptomatic and total occlusion of LICA resulted in a minor infarction in left basal ganglia with only minimal sensory symptoms. The clinical outcome in patients with stroke associated with internal carotid artery (ICA) occlusion is poor: After a mean follow-up of 1.2 years, 45% of the patients with stroke associated with ICA occlusion had died, while 75% had died or were functionally dependent.<sup>(8)</sup> Our patient is well and asymptomatic after one year of follow up. Second: It remains a significant technical challenge for duplex ultrasound to accurately differentiate between total and near total internal carotid artery (ICA) occlusions.<sup>(9)</sup> This case is remarkable because of accurate detection of 90% stenosis in RICA, and its differentiation from total occlusion; and also correct detection of LICA occlusion (In another Duplex Study performed for the patient External Carotid Artery and one of its branches was misdiagnosed as patent Internal Carotid Artery and External Carotid Artery).

Third: Many studies have reported the benefits of carotid endarterectomy (CEA) contralateral to an occluded internal carotid artery,<sup>(10)</sup> and contra lateral carotid occlusion does not reduce the safety of CEA.<sup>(11)</sup> Therefore we referred our patient for right sided CEA. Unfortunately surgery resulted in total occlusion of previously severe stenotic vessel. The risk of stroke in patients with near total ICA occlusion is perceived to be high, as stroke risk increases with severity of the stenosis.<sup>(1)</sup> Early stroke occurs in up to 7% of patients undergoing carotid endarterectomy.<sup>(6)</sup> There is a significant incidence of subsequent stroke, which seems to be related to the degree of stenosis in the contralateral internal carotid artery,<sup>(2)</sup> but in our case despite occlusion of RICA after surgery no cerebrovascular event was occurred. Forth: This case represents great variability of cerebral hemodynamics in different patients. Her brain is viable without any perfusion from Internal Carotid Arteries; and all the brain perfusion is provided by two patent vertebral arteries (fig 8,9); and reverse flow through ophthalmic arteries from External Carotid Arteries to carotid siphons.

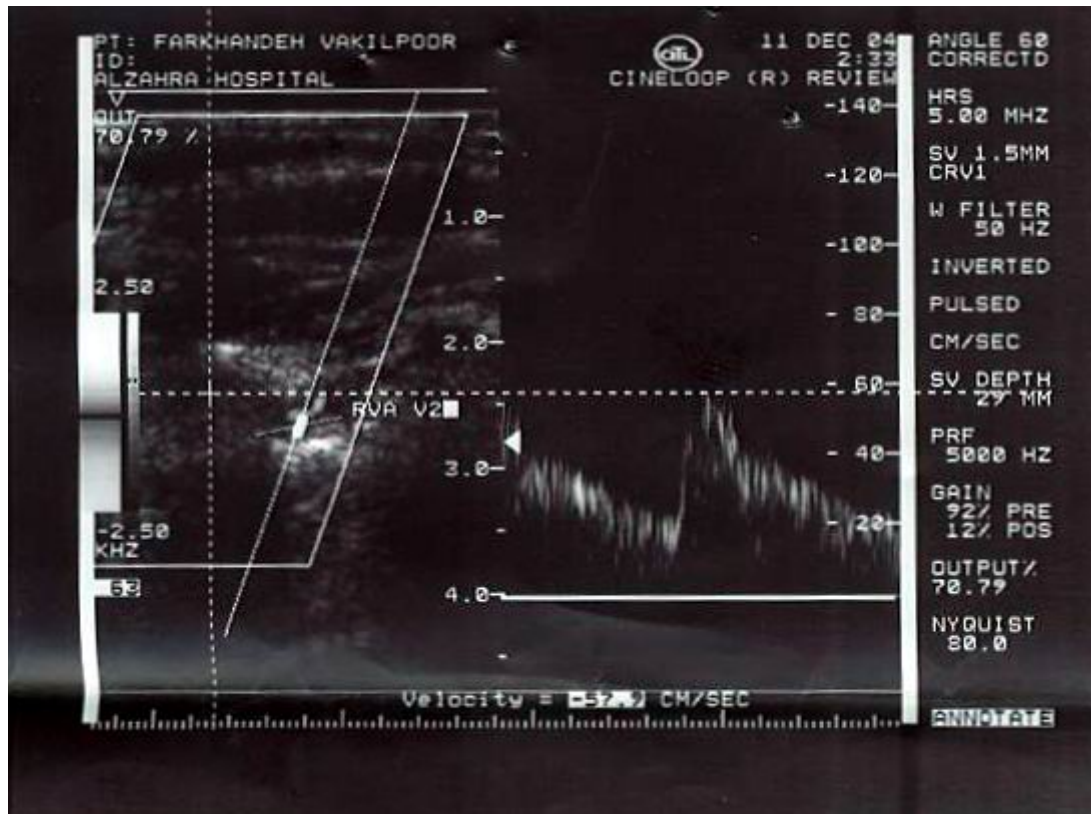


Fig-8: Normal flow through patent right vertebral artery.

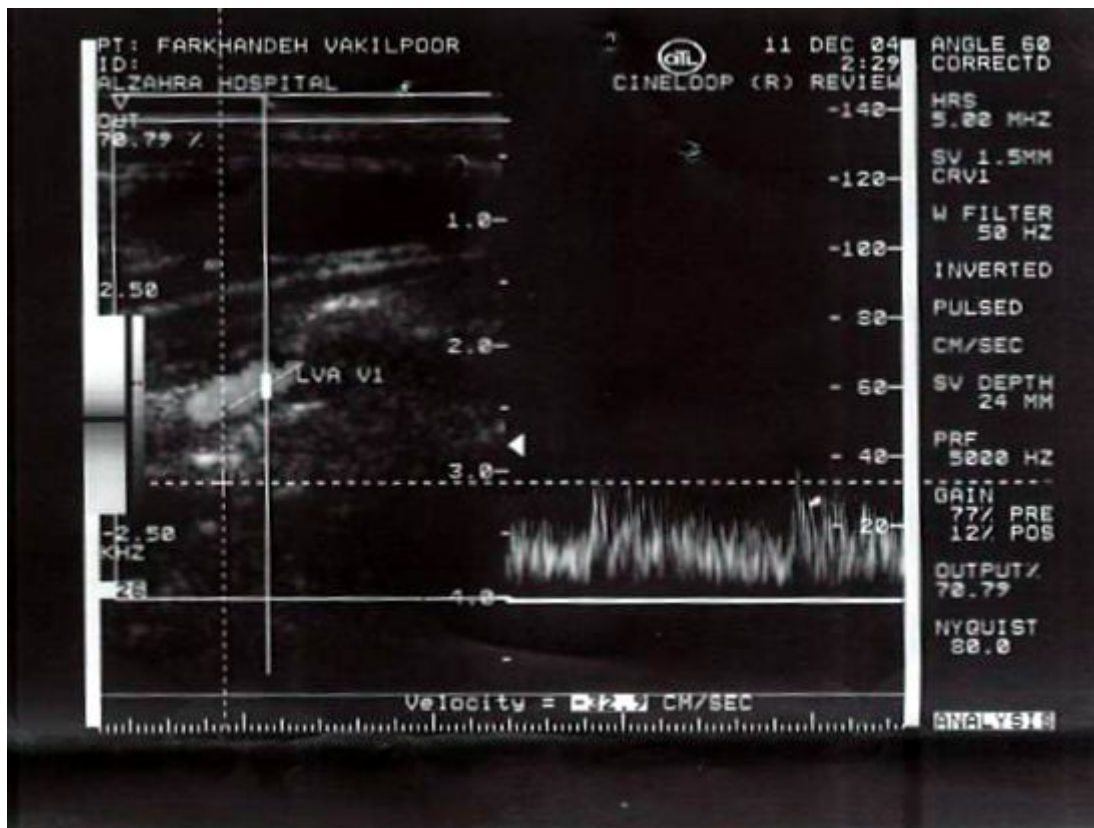


Fig-9: Normal flow through patent left vertebral artery.



## References:

- 1) [Giannoukas AD](#), [Labropoulos N](#), [Smith FC](#), [Venables GS](#), [Beard JD](#). Management of the near total internal carotid artery occlusion. Eur J Vasc Endovasc Surg. 2005 Mar; 29(3): 250-5.
- 2) Faught, W E; van Bemmelen, P S; Mattos, M A; Hodgson, K J; Barkmeier, L D; Ramsey, D E; Sumner, D S. Presentation and natural history of internal carotid artery occlusion. Journal Of Vascular Surgery, 1993 Sep; 18(3): 512-23.
- 3) [Paty PS](#), [Adeniyi JA](#), [Mehta M](#), [Darling RC 3rd](#), [Chang BB](#), [Kreienberg PB](#), [Ozsvath KJ](#), [Roddy SP](#), [Shah DM](#). Surgical treatment of internal carotid artery occlusion. J Vasc Surg. 2003 Apr; 37(4): 785-8.
- 4) [Hendrikse J](#), [Rutgers DR](#), [Klijn CJ](#), [Eikelboom BC](#), [van der Grond J](#). Effect of carotid endarterectomy on primary collateral blood flow in patients with severe carotid artery lesions. Stroke. 2003 Jul; 34(7): 1650-4. Epub 2003 May 29.
- 5) [Rutgers DR](#), [Klijn CJ](#), [Kappelle LJ](#), [Eikelboom BC](#), [van Huffelen AC](#), [van der Grond J](#). Sustained bilateral hemodynamic benefit of contralateral carotid endarterectomy in patients with symptomatic internal carotid artery occlusion. Stroke. 2001 Mar; 32(3): 728-34.
- 6) [Hingorani A](#), [Ascher E](#), [Tsemekhim B](#), [Markevich N](#), [Kallakuri S](#), [Schutzer R](#), [Jacob T](#). Causes of early post carotid endarterectomy stroke in a recent series: the increasing importance of hyperperfusion syndrome. Acta Chir Belg. 2002 Dec; 102(6): 435-8.
- 7) [Klijn CJ](#), [van Buren PA](#), [Kappelle LJ](#), [Tulleken CA](#), [Eikelboom BC](#), [Algra A](#), [van Gijn J](#). Outcome in patients with symptomatic occlusion of the internal carotid artery. Eur J Vasc Endovasc Surg. 2000 Jun; 19(6): 579-86.
- 8) [Paciaroni M](#), [Caso V](#), [Venti M](#), [Milia P](#), [Kappelle LJ](#), [Silvestrelli G](#), [Palmerini F](#), [Acciarresi M](#), [Sebastianelli M](#), [Agnelli G](#). Outcome in patients with stroke associated with internal carotid artery occlusion. Cerebrovasc Dis. 2005; 20(2): 108-13. Epub 2005 Jul 5.
- 9) [Ohm C](#), [Bendick PJ](#), [Monash J](#), [Bove PG](#), [Brown OW](#), [Long GW](#), [Zelenock GB](#), [Shanley CJ](#). Diagnosis of total internal carotid occlusions with duplex ultrasound and ultrasound contrast. Vasc Endovascular Surg. 2005 May-Jun; 39(3): 237-43.
- 10) [Ballotta E](#), [Da Giau G](#), [Baracchini C](#). Carotid endarterectomy contralateral to carotid artery occlusion: analysis from a randomized study. Langenbecks Arch Surg. 2002 Oct; 387(5-6): 216-21.
- 11) [Grego F](#), [Antonello M](#), [Lepidi S](#), [Zaramella M](#), [Galzignan E](#), [Menegolo M](#), [Deriu GP](#). Is contralateral carotid artery occlusion a risk factor for carotid endarterectomy? Ann Vasc Surg. 2005 Nov; 19(6): 882-9.