

Nasopharyngeal Mixed Tumor: A Case Report

Hamid Reza Khazraei,*¹ Soroush Amani¹

1. Department of ENT, Shar-e-Kord University of Medical Sciences, Shar-e-Kord, Iran

Article information	Abstract
<p>Article history: Received: 4 May 2013 Accepted: 10 Nov 2013 Available online: 27 Dec 2013 ZJRMS 2014 Nov; 16(11): 57-58</p> <p>Keywords: Nasopharyngeal tumor Pleomorphic adenoma Salivary gland</p>	<p>Salivary glands tumors account for less than 5% off all neoplasm in the head and neck. Pleomorphic adenoma is the most common type. Those typically arise in the palate, rarely found in the nasopharynx and nasopharyngeal tumors are usually malignant. Here we report a rare case in 61-year-old woman, who had progressive nasal obstruction for about 6 months, without any disease in the nose, but had a round nasopharyngeal mass and pathologic diagnosis as pleomorphic adenoma. Nasopharyngeal pleomorphic adenoma is a rare tumor.</p> <p>Copyright © 2014 Zahedan University of Medical Sciences. All rights reserved.</p>

Introduction

Salivary gland tumors are uncommon neoplasm's [1] that represent 6-10% of all head and neck neoplasia and 0.3-0.5% of all cancers [2, 3]. The incidence of salivary gland tumors ranges from 0.5 to 2 per 100,000 in different parts of the world [3, 4], with varied biological behavior and clinical outcome [5]. Benign tumors of nasopharynx are rare since nasopharynx is common site for malignant tumors. Pleomorphic adenoma is the most common salivary gland tumor, but is rare in nasopharynx [6].

Case Presentation

A 61 years old woman came to the office with 6-month-long progressive nasal obstruction. Anterior rhinoscopy and nasal endoscopy were normal but a round mass was seen after the choana, in the posterior wall of nasopharynx. She had hypo nasal voice. Her ears, or pharynx and neck examination were normal; she had paranasal coronal CT and MRI study with herself.

They showed single round mass in the nasopharynx. The mass respected under general anesthesia with adenotome and homeostatic very simply and we did septoplasty too. The patient visited after a week, exiled with nasal endoscopy one and 6 months later. There was not any recurrence.

Discussion

The fosse of Rosenmuller is a common site of squamous cell carcinoma of the nasopharynx and nasal obstruction, epistaxis and neck adenopathy are common symptoms of nasopharyngeal carcinoma [6].

Pleomorphic adenoma or benign mixed tumor makes up 65% of salivary gland tumors [7]. Palate, nasal cavity and nasopharynx have minor salivary glands and pleomorphic adenoma is the most common benign tumor of these glands.

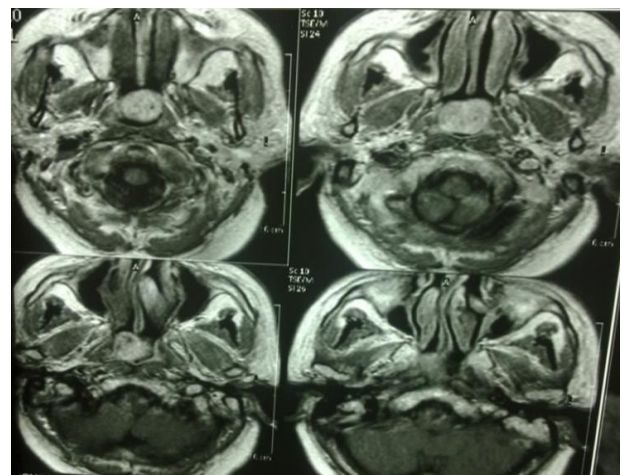


Figure 1. Mixed tumor of nasopharyngeal of the patient

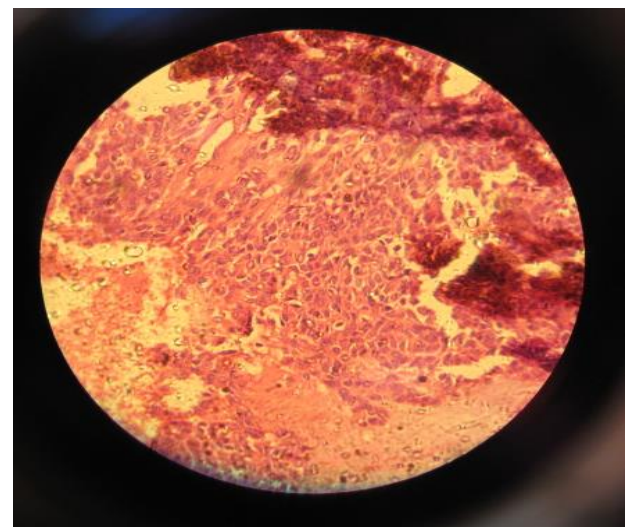


Figure 2. Microscopic view of mixed tumor of nasopharyngeal of the patient

CT scan is not significant differentiation between carcinoma ex pleomorphic adenoma and benign pleomorphic adenoma [6]. Another form of this tumor is salivary gland anlagen tumor (SGAT) of the nasopharynx that is a rare cause of neonatal airway obstruction [8].

Taker et al. reported nasopharyngeal pleomorphic adenoma in a 35 years old male; they said that they found only 5 published reports on this tumor arising from nasopharynx [6]. Lee et al. reported another case of this nasopharyngeal tumor with unilateral nostalgia, tinnitus and aural fullness and a nasopharyngeal pleomorphic adenoma that rose in the soft palate [9]. On the way review of the literature reveals that nasopharyngeal pleomorphic adenoma is rare.

Nasopharyngeal pleomorphic adenoma is a rare tumor, but it must be in mind in the differential diagnosis of

nasopharyngeal mass and nasal obstruction. The treatment is surgical removal and follow up the patient.

Acknowledgement

The authors wish to thank the Clinical Research Development Unit at Ayatollah Kashani hospital in Shahrekord for their assistance in this study.

Authors' Contributions

All authors had equal role in design, work, statistical analysis and manuscript writing.

Conflict of Interest

The authors declare no conflict of interest.

*Corresponding author at:

Department of ENT, Shar-e-Kord University of Medical Sciences, Shar-e-Kord, Iran.

E-mail: alhamid@yahoo.com

References

1. Bansal AK, Bindal R, Kapoor C, Vaidya S, Singh HP. Current concepts in diagnosis of unusual salivary gland tumors. *Dent Res J (Isfahan)*. 2012;9(Suppl 1):S9–S19.
2. Yamazaki M, Fujii S, Murata Y, Hayashi R, Ochiai A. High expression level of geminin predicts a poor clinical outcome in salivary gland carcinomas. *Histopathology*. 2010;56(7):883–92.
3. Paiva-Fonseca F, de Almeida OP, Ayroza-Rangel AL, Agustin-Vargas P. Tissue microarray construction for salivary gland tumors study. *Med Oral Patol Oral Cir Bucal*. 2013;18(1):e1–6.
4. Parkin DM, Ferlay J, Curado MP, Bray F, Edwards B, Shin HR, et al. Fifty years of cancer incidence: CI5 I-IX. *Int J Cancer*. 2010;127(12):2918–27.
5. Vargas PA, Gerhard R, Araujo Filho VJ, de Castro IV. Salivary gland tumors in a Brazilian population: a retrospective study of 124 cases. *Rev Hosp Clin Fac Med Sao Paulo*. 2002;57(6):271–6.
6. Thakur JS, Mohindroo NK, Mohindroo S, Sharma DR, Thakur A. Pleomorphic adenoma of minor salivary gland with therapeutic misadventure: a rare case report. *BMC Ear Nose Throat Disord*. 2010;10:2.
7. Kuo YL, Tu TY, Chang CF, Li WY, Chang SY, Shiao AS, et al. Extra-major salivary gland pleomorphic adenoma of the head and neck: a 10-year experience and review of the literature. *Eur Arch Otorhinolaryngol*. 2011;268(7):1035–40.
8. Herrmann BW, Dehner LP, Lieu JE. Congenital salivary gland anlage tumor: a case series and review of the literature. *Int J Pediatr Otorhinolaryngol*. 2005;69(2):149–56.
9. Lee SL, Lee CY, Silver SM, Kuhar S. Nasopharyngeal pleomorphic adenoma in the adult. *Laryngoscope*. 2006;116(7):1281–3.

Please cite this article as: Khazraei HR, Amani S. Nasopharyngeal mixed tumor: A case report. *Zahedan J Res Med Sci*. 2014; 16(11): 57-58.