

Evaluation of Panoramic Radiography at Showing Width of the Dental Follicle

S. Kamal Seyedmajidi,¹ Sina Haghanifar,² Mohammad Mehdizadeh,³ Maryam Seyedmajidi,^{*4} Ali Bijani,⁵ Nafiseh Ghasemi⁶

1. Department of Materials Engineering, Faculty of Mechanic Engineering, Babol University of Technology, Babol, Iran
2. Department of Oral and Maxillofacial Radiology, Faculty of Dentistry, Babol University of Medical Sciences, Babol, Iran
3. Department of Oral and Maxillofacial Surgery, Faculty of Dentistry, Babol University of Medical Sciences, Babol, Iran
4. Dental Materials Research Center, Faculty of Dentistry, Babol University of Medical Sciences, Babol, Iran
5. Non-Communicable Pediatrics Diseases Research Center, Babol University of Medical Sciences, Babol, Iran
6. Students Research Committee, Babol University of Medical Sciences, Babol, Iran

Abstract

Article information

Article history:

Received: 17 Jan 2014

Accepted: 8 Mar 2014

Available online: 29 Apr 2014

ZJRMS 2014 July; 16(7): 35-39

Keywords:

Impacted tooth

Dentigerous cyst

Dental follicle

Panoramic radiography

*Corresponding author at:

Dental Materials Research
Center, Faculty of Dentistry,
Babol University of medical
sciences, Babol, Iran.

E-mail:

ms_majidi79@yahoo.com

Background: Considering probable incidence of pathological changes in the follicles of impacted teeth, this study is conducted to evaluate pericoronal radiolucency of impacted third molars.

Materials and Methods: In this cross-sectional study, widths of follicular spaces of 201 impacted third molars were measured on panoramic radiographs. Under local anesthesia, the teeth along with the dental follicles were surgically removed. After routine procedure, they histopathological were examined.

Results: After evaluating 201 dental follicles it was observed that, 50.7% of cases (102 cases) showed pathological changes and all of them were dentigerous cysts. Incidence of cystic changes in the follicles of third molars of patients aged 21 years and above, is 1.465 times more than patients who were under 21 years old. Also in dental follicles of lower third molars, the incidence of pathological changes was 1.957 times more than maxilla. Cystic changes in the evaluation of follicular widths up to 1.5 mm, was observed in 48% of cases, up to 2 mm, in 73.5% of cases, up to 2.5 mm, in 87.2% of cases and up to 3 mm, in 92.1% of cases.

Conclusion: It seems that occurrence of cystic changes in dental follicles increases with increase in age and width of follicular space. However, considering the high incidence of cystic changes in pericoronal radiolucency around the impacted third molars, this study supports the prophylactic removal of impacted third molars.

Copyright © 2014 Zahedan University of Medical Sciences. All rights reserved.

Introduction

It seems that only 50% of third molars grow in mouth [1]. The most common reason for the inability to erupt is reduction in the size of arches that results lack of space for eruption [1, 2]. Third molars are the most common impacted teeth [2] which may cause several side effects such as pain, trismus and infection or even cysts and tumors [3]. It seems that 1.5 to 13.3% of the third molars are removed due to cyst formation [4, 5]. According to White's opinion, a normal follicular space should be 2-3 mm in size [6].

On the other hand, according to Wood's opinion, 80% of dental follicles with pericoronal spaces of 2.5 mm in width were not normal follicles in radiography [7]. Some researchers believe that a pericoronal space with a width greater than 2.5 mm in intraoral radiography and more than 3 mm in panoramic radiography is suggestive of cyst presence [8]. Glosser and Campbell and Mesgarzadeh et al., in their studies on impacted third molars with normal follicular space, found that amount of the pathological changes associated with impacted third molars are more than what it is seen on radiographs and that radiographic features are not reliable in the diagnosis of follicular tissue [9, 10]. On the other hand, Saghafi et al. and Werkmeister et al. found that there are little

pathological changes in the follicles of impacted third molars and these teeth are preferred not to be removed unless one or more clear indications are appeared [3, 11]. Shear believes that some of unerupted teeth show increased width in follicular space in the pre-eruptive phase; this is not a proof for the presence of cyst unless the width of its pericoronal radiolucency is at least 3-4 mm [12]. Also reported clinical studies by the National Institutes of Health, United States of America show that 1.5-13.3% of third molars are removed primarily due to the formation of cysts [5]. Despite the availability of radiographic and histological data, differentiation of small dentigerous cysts from large dental follicles, if not impossible, is difficult and nowadays it seems that assessment of cystic cavity during surgery is the only reliable way for diagnosis [13].

In previous research, we observed that 41.3% of follicles with normal radiographic appearance (follicular spaces width less than 2.5 mm), showed histopathological cystic changes [14]. Therefore, considering that determination of normal and pathological pericoronal spaces just through radiographic evaluation is difficult and several researchers believe that the radiographic data alone are insufficient for a definitive diagnosis and always histopathological

evaluation is required. Considering the high incidence of pathological changes in dental follicles of impacted third molars, this study aimed to evaluate the pericoronal radiolucency of impacted third molars histopathologically.

Materials and Methods

This cross-sectional study was performed after approval from ethics committee of Babol University of medical sciences on follicles obtained from surgical removals of impacted third molars of patients referred to department of oral and maxillofacial surgery, Babol Dentistry School during January 2010 to December 2012. Demographic data about the patient, depth and position of impacted tooth was recorded according to Pell and Gregory classification [1]. If the anterior-posterior diameter of crown is located completely in front of anterior border of ramus, the tooth is in class I relation. If the tooth is located posterior, so that almost half of the tooth is covered by ramus, tooth and ramus are in class II relation. In class III status, impacted tooth is completely located within the bone. Also if occlusal plane is near or at the same level with the occlusal plane of second molar, it is considered as class A impaction and if it is located between the occlusal plane and cervical line of second molar, it is class B impaction and if the occlusal plane of impacted tooth lies below the cervical line of second molar, it is considered as class C impaction [1]. Then in the panoramic radiograph of each patient, the measurement of mesial and distal distance between follicular crest of third molars up to height of contour and the distance between follicular crest and the cusps of third molars in occlusal area was performed by an oral and maxillofacial radiologist using a digital caliper with 0.01 mm accuracy (Guanglu-China). Each measurement was repeated twice. The highest measured width of the dental follicle of each tooth was recorded. The exclusion criterion was inability to measure the follicular space at mentioned points.

All radiographies were performed using Cranex Tome (Soredex-Finland) with a mean magnification of 1.3×. Then by an automatic processor, Hope (Dental-Max, USA), development and fixation of radiographic films was performed under standard conditions. All technical principals were taken into consideration while performing panoramic radiography. Also radiographs which had a more than 10% difference in mesiodistal width of mandibular left and right first molars were excluded. All panoramic radiographs were performed using Cranex Tome with the mean magnification of 1.3×. Surgery was performed under local anesthesia. Fixation was performed by immediate placement of removed teeth and their follicles in 10% buffered formalin solution. After going through cutting and processing of tissues and preparation of 5 micron sections from paraffined blocks, obtained microscopic slides were stained using Hematoxylin and Eosin (H & E). Prepared microscopic slides were examined by an oral and maxillofacial pathologist who was not aware of clinical and radiographic features of

lesions using Olympus BX41 (Tokyo, Japan) light microscope and the final diagnosis for each case was obtained. Collected data were analyzed by SPSS-18, Fisher's exact test, *t*-test and Logistic Regression. The difference between groups was considered statistically significant at $p < 0.05$.

Results

One hundred and two cases (50.7%) of 201 evaluated dental follicles showed pathological changes that all of them were dentigerous cyst (Fig. 1, 2). Follicular space was 0.21 to 8.8 mm. In 201 follicles of impacted third molars, 61 cases (30.3%) were obtained from male patients and 140 cases (69.7%) were from female patients. Average width of follicular spaces of male patients was 1.97 ± 1.46 and for female patients it was 1.61 ± 0.69 mm and *t*-test did not show any significant differences between the 2 genders. Incidence of cystic changes in dental follicles obtained from female patients was 1.47% (66 individuals) and in male patients it was 59% (14 individuals). According to Fisher's exact test, no significant relationship was observed between gender and pathological changes. The range of patients' age was between 15 and 57 years (with mean age 22.3 ± 4.9 years). Most of them were in their third decade of life. Thirty eight percent of patients who were younger than 21, (27 of 71) showed pathological changes in cystic formation.

However, 57.7 % of patients aged 21 and above (75 of 130 cases) showed cystic changes in dental follicles. Based on these data and Fisher's exact test, a significant correlation was found between age and pathological changes ($p = 0.008$). The incidence of cystic changes in follicles of third molars of patients aged 21 and older is 1.465 times (95% CI: 1.117-1.921) more than individuals who were aged less than 21. By comparing the mean age of two subgroups with cystic changes and without pathological changes in their follicles using *t*-test, it was concluded that the mean age of individuals with no cystic change in their follicles is 21.2 ± 3.8 years and for individuals with cystic changes in their follicles, it was 23.3 ± 5.6 years. This difference was statistically significant ($p = 0.002$). Among the evaluated cases, 169 follicles (84.1%) were from mandible and 32 follicles (15.9%) were from maxilla. Cystic changes were observed in 93 (55%) follicles of mandibular third molars, while cystic changes were seen in 9 cases of maxillary follicles. Widths of mandibular and maxillary follicular spaces were respectively 1.7 ± 1 mm and 1.7 ± 0.96 . *t*-test showed no significant differences between the two jaws in terms of width of follicular space. According to *t*-test, a significant relationship exists between the location of dental follicle (upper or lower jaw) and the incidence of pathological changes ($p = 0.007$). It could be said that the possibility of incidence of cystic changes in the mandibular third molar follicles is 1.957 times more than maxillary ones (95% CI: 1.106-3.461). In evaluation of follicles with 2.5 mm width or less we found that 89 cases (50.6%) have cystic changes. This finding reached to 13 cases in follicles with more than 2.5 mm width and no

significant difference was observed between two mentioned groups. Average width of follicular spaces in case of follicles with cystic changes and for those without pathological changes were respectively 1.17 ± 1.80 mm and 1.46 ± 0.78 mm and no significant difference was observed by *t*-test. According to findings of present study, 52% of impacted third molars with the width of normal pericoronal radiolucency of more than 1.5 mm (up to 3 mm), represent cystic changes. Follicular space width and cystic changes are showed in table 1.

Table 1. Follicular space width and cystic changes

Follicular space width (mm)	Up to 1.5 (%)	Up to 2 (%)	Up to 2.5 (%)	Up to 3 (%)
Cystic changes in the dental follicle (%)	48	73.5	87.2	92.1

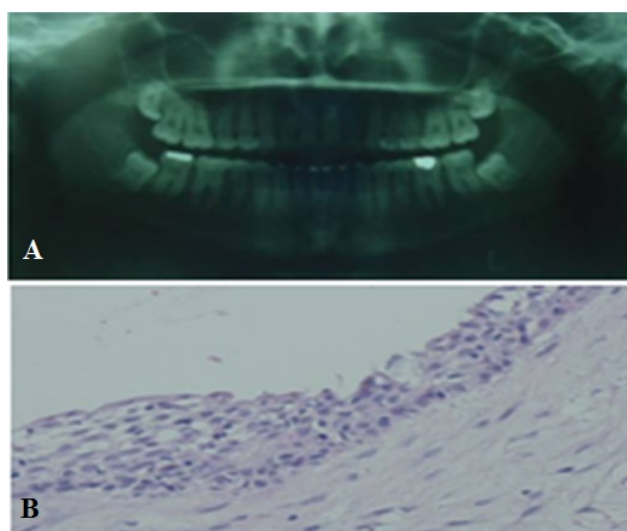


Figure 1. (A) Radiographically normal follicular space of right mandibular third molar (B) that showed cystic changes in histopathological view

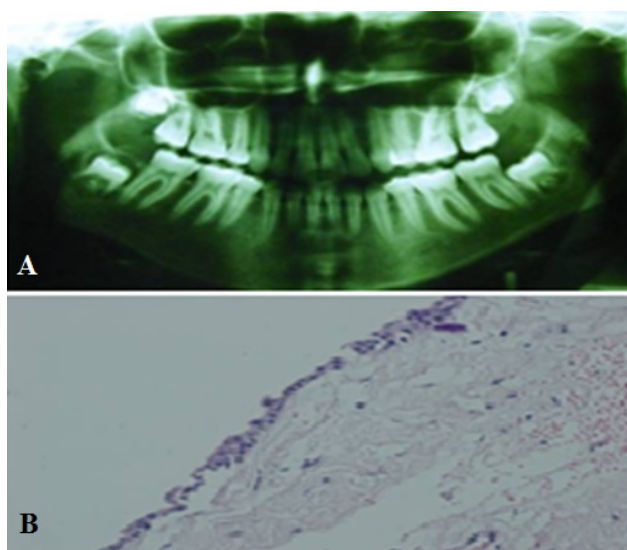


Figure 2. (A) Radiographic feature of wide follicular space of right mandibular third molar. (B) In histopathological view it was dental follicle

No significant correlation between the average width of the dental follicles and incidence of cystic changes in upper and lower jaw was found. According to the obtained findings, class A of Pell and Gregory [1] classification for impacted third molars with 44.8% (90 cases), was the most common and class B with 40.8% (82 cases) and class C with 13.4% (27 cases) in order were in following places. Pell and Gregory [1] class I with 61.7% (124 cases), was the most common and then, class II with 37.3% (75 cases) and class III with 1% (2 cases) in order following places. In evaluation of obtained Roc Curve for the width of the follicular spaces, obtained data were not considered as good indices for diagnosis of the cyst.

Discussion

In the present study, cystic changes in cases of follicular width of 2.5 and 3 mm was respectively equal to 87.2% and 92.1% which is more than obtained data in the previous studies.

After enamel formation, crown is covered by reduced enamel epithelium and ectomesenchyme. Various lesions such as cysts and odontogenic tumors can be derived from dental follicles surrounding the tooth [15]. Impacted tooth is a retained or embedded tooth that fails to erupt into the dental arch within the specific time due to a physical barrier such as adjacent teeth, dense overlying bone, excessive soft tissue or a genetic abnormality. Most often, the cause of impaction is inadequate arch length and space in which to erupt. That is why the total length of alveolar arch is smaller than the tooth arch (the combined mesiodistal width of each tooth) [2, 16, 17].

Large numbers of intraoral surgeries performed by oral and maxillofacial surgeons are removal of impacted third molars. Presence of pericoronal disease is an acceptable reason for the removal of impacted third molars. The follicles of impacted third molars may remain normal or undergo pathological changes. In the present study, the width of follicular space of 50.7% of cases of follicles surrounding impacted third molars was between 0.21-8.8 mm, histopathological changes appeared as dentigerous cyst formations. The findings of Saravana and Subhashraj's study revealed cystic changes in 46% of follicles with follicular space width less than 2.4 mm [18]. Kotrashetti et al. and Mesgarzadeh et al. also reported pathological changes in radiographically normal follicles of impacted third molars as 53% and 58.5% for follicular widths of 3 and 2.5 mm respectively [4, 10].

Due to the high incidence of formation of dentigerous cysts as cystic changes according to our findings, the necessity of evaluation of dental follicular tissues and prophylactic removal of impacted third molars is revealed. Adelsperger et al. found that incidence of pathological changes in dental follicles is significantly higher in patients who were aged more than 21 [19]. Kotrashetti et al. also revealed that aging increases the possibility of incidence of pathological changes in impacted third molars [4]. Rakprastikul also reported higher prevalence of pathological changes in the patients

who were over 20 years old [5]. In the present study, the possibility of incidence of cystic formation in patients who were 21 years old and above was higher. Present study expresses the peak incidence of cystic formation of dental follicles of impacted third molars in the third decade of patients' life. It is consistent with the results of Delay and Wysocki study [13]. In other words, the findings of this study, approves the widespread idea that correlates the risk of complications associated with impacted third molars with increase in age.

In the present study, difference between female and male patients in terms of pathological changes, around the impacted third molar were not statistically significant. The studies of Glosser and Campbell and Adelsperger et al. confirmed this finding [9, 19]. The prevalence of cystic formation was higher in the mandible compared to maxilla. This is in accord with the Glosser and Campbell findings [9]. In most studies, the thickness of normal follicular space in panoramic radiography is considered less than 2.5 mm [18, 19]. But present study discusses that the possibility of cystic formation of follicular tissues of impacted third molars with follicular space of more than 1.5 mm is 52%. On the other hand, 87.2% of follicles with more than 2.5 mm width showed cystic changes. Kotrashetti et al. in his study found that 58.5% of the dental follicles with 2-2.5 mm width of follicular space showed cystic formation [4]. Shear and Daley and Wysocki stated that the likelihood of transformation of dental follicles associated with impacted teeth to dentigerous cyst is respectively 0.1-0.6% and 1.5% [12, 13]. Leitner et al. also reported a low-grade fibrosarcoma associated with impacted third molar without clinical evidences of follicular lesions in a 23 years old woman [20].

According to above mentioned cases and high percentage of cystic changes in dental follicles and its relation with aging in the present study, remove of impacted third molars in young ages is recommended. Surgery in older ages makes difficulty in the healing process and recovery. The pathological process in older patients, takes more time to increase in size and this demands an even more extensive surgery. Also expansion of large cystic lesions in the jaws reduces the bone's mass. Given all the above, the need for early removal of third

molars is recommended even when they are asymptomatic. Considering the high incidence of cystic changes in the follicles with less than 2.5 mm width, associated with impacted third molars in this study, it is suggested that the radiographic appearances are not necessarily a reflection of the absence of the disease. Therefore, the clinician should perform clinical and radiographic evaluation for impacted third molars and after removal of follicle he should send it for histopathological evaluation. In general, it seems that the prevalence of dentigerous cyst related to impacted third molars is more than what it is predicted by radiographic evaluation.

The radiographic evaluation of pericoronal spaces for detection of normal status from pathological status is difficult and researchers believe that radiographs are insufficient for pathological evaluation and there is a need for histological diagnosis. Considering the high probability of incidence of cystic changes in the follicles of impacted third molars, even with the normal width of radiolucency, the prophylactic removal of impacted third molars is suggested, particularly, when the patient's age is 21 years or more. Study with three dimensional computed tomography to measure the exact width of follicles and its comparison with histopathological findings is recommended.

Acknowledgements

The present study is the result of research project No.731172 approved by the Research Council of Babol University of Medical Sciences. The authors would like to thank the Deputy of Research and Technology of Babol University of Medical Sciences for financial supports of this project. The authors wish to thank Mr Obeid Mohammadi for H & E staining.

Authors' Contributions

All authors had equal role in design, work, statistical analysis and manuscript writing.

Conflict of Interest

The authors declare no conflict of interest.

Funding/Support

Babol University of Medical Sciences.

References

- Miloro M, Ghali GE, Larsen PE, editors. A textbook of oral and maxillofacial surgery. 5th ed. Hamilton: B.C. Decker; 2008: 194-6.
- Neville BW, Damm D, Allen CM, editors. Oral and maxillofacial pathology. 3rd ed. St. louis: W.B. Saunders; 2009: 590-643.
- Saghafi SH, Haraji A, Zare-Mahmodabadi R and Farzanegan F. [Evaluation of histopathologic changes in impacted third molar follicles in Mashhad dental school in 2005] Persian. J Mashhad Dent Sch. 2007; 31(3): 171-6.
- Kotrashetti VS, Kale AD, Bhalaerao SS and Hallikeremath SR. Histopathologic changes in soft tissue associated with radiographically normal impacted third molars. Indian J Dent Res. 2010; 21(3): 385-90.
- Rakprasitkul S. Pathologic changes in the pericoronal tissues of unerupted third molars. Quintessence Int. 2001; 32(8): 633-8.
- White SC, Pharoah MJ. Oral radiology: Principles and interpretation. 5th ed. St. Louis: Mosby; 2004: 388, 390, 419.
- Wood NK, Goaz PW. Differential diagnosis of oral and maxillofacial lesions. 5th ed. St. Louis: Mosby; 1997: 282-3.
- Farah CS, Savage NW. Pericoronal radiolucencies and the significance of early detection. Aust Dent J. 2002; 47(3): 262-5.
- Glosser JW, Campbell JH. Pathologic change in soft tissues associated with radiographically 'normal' third

- molar impactions. *Br J Oral Maxillofac Surg.* 1999; 37(4): 259-60.
10. Mesgarzadeh AH, Esmailzadeh H, Abdolrahimi M and Shahamfar M. Pathosis associated with radiographically normal follicular tissues in third molar impactions: A clinicopathological study. *Indian J Dent Res.* 2008; 19(3): 208-12.
 11. Werkmeister R, Fillies T, Joos U and Smolka K. Relationship between lower wisdom tooth position and cyst development, deep abscess formation and mandibular angle fracture. *J Craniomaxillofac Surg.* 2005; 33(3): 164-8.
 12. Shear M. *Cysts of the oral regions.* 2nd ed. USA: Wright; 1983: 81.
 13. Daley TD, Wysocki GP. The small dentigerous cyst: A diagnostic dilemma. *Oral Surg Oral Med Oral Pathol Oral Radiol Endod.* 1995; 79(1): 77-81.
 14. Seyedmajidi M, Haghanifar S, Foroughi R, et al. Histopathologic evaluation of normal radiolucent space around impacted third molar. *J Mashhad Dent Sch.* 2011; 35(2): 99-106.
 15. Gardner DG, Radden B. Multiple calcifying hyperplastic dental follicles. *Oral Surg Oral Med Oral Pathol.* 1995; 79(5): 603-6.
 16. Chu FC, Li TK, Lui VK, et al. Prevalence of impacted teeth and associated pathologies: A radiographic study of Chinese population. *Hong Kong Med J.* 2003; 9: 158-63.
 17. Hupp JR. Principles of management of impacted teeth. In: Hupp JR, Ellis E, Tucker MR, editors. *Contemporary oral and maxillofacial surgery.* 5th ed. St. Louis: Mosby; 2008: 153.
 18. Saravana GH, Subhashraj K. Cystic changes in dental follicle associated with radiographically normal impacted mandibular third molar. *Br J Oral Maxillofac Surg.* 2008; 46(7): 552-3.
 19. Adelsperger J, Campbell JH, Coates DB, et al. Early soft tissue pathosis associated with impacted third molars without pericoronal radiolucency. *Oral Surg Oral Med Oral Pathol Oral Radiol Endod.* 2000; 89(4): 402-6.
 20. Leitner C, Hoffmann J, Kröber S and Reinert S. Low-grade malignant fibrosarcoma of the dental follicle of an unerupted third molar without clinical evidence of any follicular lesion. *J Craniomaxillofac Surg.* 2007; 35(1): 48-51.

Please cite this article as: Seyedmajidi SK, Haghanifar S, Mehdizadeh M, Seyedmajidi M, Bijani A, Ghasemi N. Evaluation of panoramic radiography at showing width of the dental follicle. *Zahedan J Res Med Sci.* 2014; 16(7): 35-39.