

Comparing the Effect of *Myristica fragrans* and Flunixin on Adjuvant-Induced Arthritis in RatHossein Najafzadeh,*¹ Saleh Esmailzadeh,² Masood Ghorbanpour,² Ahmad Farajzadeh,³ Ali Asadirad⁴

1. Department of Basic Sciences, Faculty of Veterinary Medicine, Shahid Chamran University, Ahvaz, Iran
2. Department of Pathobiology, Faculty of Veterinary Medicine, Shahid Chamran University, Ahvaz, Iran
3. Department of Microbiology, Faculty of Medicine, Joundishapour University, Ahvaz, Iran
4. Department of Clinical Sciences, Graduated from Veterinary Medicine, Faculty of Veterinary Medicine, Shahid Chamran University, Ahvaz, Iran

Article information	Abstract
<p>Article history: Received: 19 Oct 2012 Accepted: 10 Dec 2012 Available online: 21 Jan 2013 ZJRMS 2014; 16(2): 33-36</p> <p>Keywords: Nutmeg Myristica fragrans Seed extract Flunixin meglumine Arthritis Rats</p> <p>*Corresponding author at: Department of Basic Sciences, Faculty of Veterinary Medicine, Shahid Chamran University, Ahvaz, Iran E-mail: najafzadeh@scu.ac.ir</p>	<p>Background: Nutmeg, <i>Myristica fragrans</i> Houtt, has shown anti-inflammatory properties in some studies. At present experimental study, we evaluated the effect of seed extract of nutmeg on adjuvant-induced arthritis in rats in comparison with flunixin meglumine.</p> <p>Materials and Methods: Experimental study was done in six groups of Wistar rats (each group 8 rats) as following: Group 1 was kept as control under similar conditions to other groups. All other rats received complete Freund's adjuvant at dose 0.1 ml which injected under skin of foot. Group 2 was received vehicle (normal saline). Group 3 received flunixin intraperitoneally at dose of 2 mg/kg body weight of rats daily for 12 days. Group 4 to 6 received extract of nutmeg at dose 100, 200 and 300 mg/kg intraperitoneally and daily for 12 days. Four rats in each group were anesthetized and blood collected for serum analysis on 12th day. The ankle joint prepared for histopathological examination. The remained rats were kept until 21th day. Levels of the cytokine TNF-α in serum was measured using ELISA kit.</p> <p>Results: The serum levels of TNF-α in the group 2 were significantly increased; while nutmeg decreased the elevated TNF-α level in a dose-dependent manner but significantly with 300 mg/kg. The flunixin did not significantly decrease the levels of TNF-α. Nutmeg treated rats manifested pathological events in the ankle joints to a markedly lesser degree. Flunixin prevented pannus formation but it was ineffective in other lesions.</p> <p>Conclusion: Thus, nutmeg protected the joints against cartilage destruction and bone erosion in a dose-dependent manner.</p> <p>Copyright © 2014 Zahedan University of Medical Sciences. All rights reserved.</p>

Introduction

Rheumatoid arthritis (RA) is a chronic inflammatory and destructive joint disease that affect on life quality [1, 2]. It targets the synovial membrane of joints but that can also have systemic signs [3]. Although the causes of RA remain unknown, some studies have shown the key roles of cytokines, such as tumor necrosis factor- α (TNF- α), interleukin-1 β (IL-1 β), and IL-6 in the pathogenesis of RA [4, 5]. These cytokines are present in synovial fluid and joint [4]. Also these cytokines are produced through activation of T cells in RA [6, 7].

Adjuvant arthritis is an experimental disorder and occurs 10-14 days after inoculation of the animal with a suspension of adjuvant. Mycobacterial cell wall material (i.e., complete Freund's adjuvant) has been used as the adjuvant in most studies. It can be suppressed by nonsteroidal, antiinflammatory drugs, corticosteroids, or immunosuppressive agents [1-5, 8, 9].

Mace is the fleshy orange-red aril around the seed of nutmeg, *Myristica fragrans* Houtt, which belongs to the family myristicaceae [10]. The potential anti-cancer properties of mace including trans mammary modulation of xenobiotic metabolizing enzymes in the liver of mouse

pups [11], prevention of DMBA (7, 12 dimethyl benzantracene)-induced papillomagenesis in the skin of mice [12] and its modulatory effects on hepatic detoxification have been reported [13]. A number of pharmacological studies show properties of mace such as anti-inflammatory properties of myristicin from mace, antifungal, antibacterial, larvicidal and antioxidant potential [9, 14-17].

Seeds of *Myristica fragrans* Houtt are psychotomimetic and possess both stimulatory and depressant activities. Nutmeg, also possesses carminative, astringent, hypolipidaemic, antithrombotic, antiplatelet aggregation, antifungal, aphrodisiac, and anti-inflammatory activities. Fixed oil contains myristicin, myristic acid while volatile oil contains pinene, sabinene, camphene, elemicin, isoelemicin, eugenol, methoxyeugenol, isoeugenol, safrole, etc. Eugenol, the major constituent of volatile oil inhibits lipid peroxidation and maintains activities of superoxide dismutase, catalase, glutathione peroxidase, glutamine transferase, and glucose 6-phosphate dehydrogenase. Chloroform extract of nutmeg showed analgesic and anti-inflammatory activity in rodents. Although the anxiogenic principle may not find any use in

therapeutics, it can be a useful research tool in experimental pharmacology [18].

Flunixin meglumine is a non-steroidal anti-inflammatory agent. It is used for treatment of inflammatory conditions especially visceral inflammations and pain. Flunixin meglumine provided analgesia in amphotericin B-induced synovitis-arthritis in animal model [19]. This important property (visceral anti-inflammatory) of flunixin as a nonsteroidal anti-inflammatory agent conducted us to evaluation its effect on RA. At present experimental study, we evaluated seed extract of nutmeg effect on adjuvant-induced arthritis in rats in comparison with flunixin meglumine.

Materials and Methods

In this experimental study the seed of nutmeg was purchased from Ahvaz herbal shop and authentication of the seeds was done in agriculture department of Shahid Chamran University of Ahvaz. The hydro-ethanolic extract was prepared by maceration method and filtrated.

The 48 male Wistar rats were purchased from laboratory animal center of Jundishapur university. The age of rats was 7 weeks. The animals access to food and water ad libitum under 12 h light and 12 h dark conditions. The animal care was provided under the supervision of a qualified veterinarian.

This experimental animal model study was done in six groups of rats (each group 8 rats) as following: Group 1 was kept as control under similar conditions to other groups. All other rats received complete Freund's adjuvant (Difco, Germany) at dose 0.1 ml which injected under skin of foot. Group 1 intraperitoneally received normal saline (as vehicle) daily for 12 h days. Group 2 was kept without drug. Group 3 intraperitoneally received flunixin meglumine (Razak Co., Iran) at dose 2 mg/kg body weight of rats daily for 12 days. Group 4 to 6 received extract of nutmeg at dose 100, 200 and 300 mg/kg intraperitoneally and daily for 12 days. Four rats in each group were anesthetized by ketamine hydrochloride and blood collected for serum analysis on 12th day. The ankle joint of these rats prepared for histopathological examination. Other rats were kept until 21th day. Levels of the cytokines TNF- α in blood serum was measured using commercially available ELISA kit for TNF- α (Ebioscience) according to the manufacturer's recommendations.

The rats were sacrificed by ketamine hydrochloride and the hind paws were excised and placed in 10% PBS-buffered formalin. The fixed tissues of the ankle joints were then decalcified in formic acid, embedded in paraffin, longitudinally cut into 5 micron sections, and stained with hematoxylin and eosin (H&E). Grading of cellular infiltration (polymorphonuclear cells, macrophages or lymphocytes), joint space narrowing, synovial hyperplasia, pannus formation, and bone and cartilage erosion of the ankle joints were examined by light microscope.

This grading was done by using a semiquantitative scale from 0 (normal), 1 (mild changes), 2 (moderate changes),

and 3 (severe changes) based on pathological examination was done by Cai et al.

Data of serum TNF- α level were expressed as means \pm SEM. One-way analysis of variance with post hoc LSD test (SPSS-16, SPSS Inc., Chicago, IL, USA) was used to analyze differences between different groups. Statistical significance was accepted for $p < 0.05$.

Results

Levels of cytokine TNF- α in the blood serum were determined on days 12 and 21 after arthritis induction. Consistent with the joint swelling, the mean of serum TNF- α was significantly increased in the vehicle-treated rats and reached to 141 pg/ml. However, this mean was 18.5 pg/ml in normal rats (without arthritis). Treatment with nutmeg decreased the elevated TNF- α by dose-dependent effect (Fig. 1). Nutmeg at dose of 300 mg/kg administered from the day of arthritis induction (day 0) significantly ($p < 0.05$) reduced serum TNF- α levels. The flunixin did not significantly decrease the elevated serum TNF- α concentration (Fig. 1).

The histological sections of the ankle joints from normal, vehicle-treated, and nutmeg-treated rats are shown in figures 2-4. Histopathological examination of the synovial joints of the vehicle-treated rats revealed marked cellular infiltration, synovial hyperplasia, and joint space narrowing. Severe pannus formation, bone, and cartilage destruction were also observed in the synovial joints of vehicle-treated rats as compared to the synovial joints of normal rats. Nutmeg treated rats manifested these pathological events in the ankle joints to a markedly lesser degree. Further histopathological scoring demonstrated that treatments with nutmeg, on both days 12 and 21 after arthritis induction, protected the joints against cartilage destruction and bone erosion and other histopathological changes in a dose-dependent manner, but better with 300 mg/kg. Flunixin also decreased histopathological changes especially prevented pannus formation, but its effect lesser than nutmeg at dose 300 mg/kg.

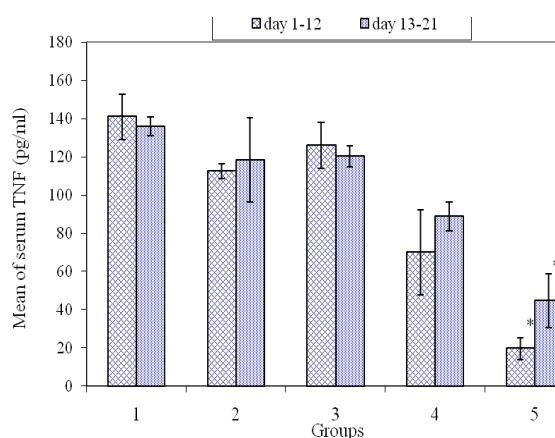


Figure 1. Mean \pm SE of serum TNF- α levels of rats; 1-5: groups of rats received adjuvant, 2: group received flunixin, 3-5: groups received nutmeg at dose 100, 200 and 300mg/kg respectively. *represent significant difference at $p < 0.05$

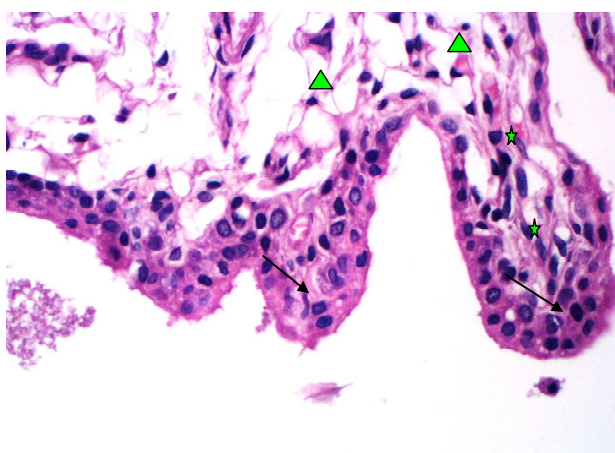


Figure 2. Illustration histopathological sections of the ankle joints of rats in control group. Flashes show cubical cells, stares show fibroblasts and triangles show fatty cells (H&E×40)

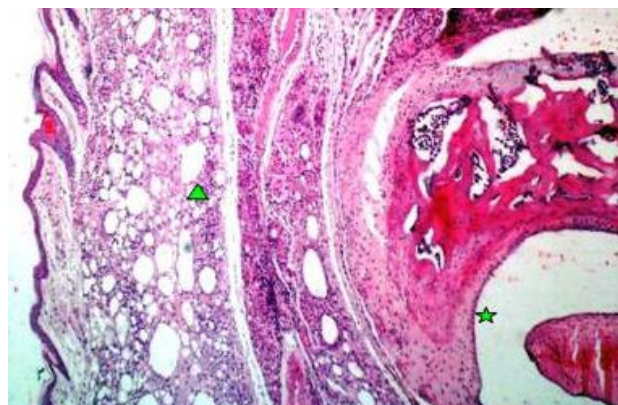


Figure 4. Illustration histopathological sections of the ankle joints of rats in group 2 received Freund's adjuvant and nutmeg (200 mg/kg) after 21 days. Stare shows normal surface of joint and triangle shows decreasing

Discussion

The results show injection of Freund's adjuvant produces experimental arthritis and elevates serum TNF- α as well as induces significant histopathological changes in ankle joints. The hydro-ethanolic extract of nutmeg has preventive and protective effect on changes of serum TNF- α and joint tissue. This extract decreased signs and inflammation in ankle joints.

RA is a chronic inflammatory and systemic autoimmune disease characterized by a number of inflammatory and destructive events such as joint pain and swelling, synovial hyperplasia, pannus formation, cartilage and bone destruction, and joint malformation [20]. Many cell populations, various cytokines, and different inflammatory mediators are involved in the generation of the pathological events characteristic of RA [21]. At present animal model study, we induced RA and demonstrated pathological changes and the level of TNF- α was elevated in vehicle- treated rats. These finding are similar to other related studies [4, 9, 22]. The inflammatory reactions especially immunological mediators such as cytokines seem to have key role at this process [5, 7]. Flunixin is anti-inflammatory agent without immunomodulatory effect, thus it could not prevent elevation of serum TNF- α levels. Therefore it cannot effective rheumatoid conditions. The effect of flunixin on RA was not evaluated by other researchers. However, indomethacin as a nonsteroidal anti-inflammatory agent had significant antirheumatoid effect in some studies including study was done by Cai et al. [9].

The extract of nutmeg had dose-dependent anti-rheumatoid effect. This efficacy may be related its immunomodulatory effect. This extract prevents both pathological changes and TNF- α elevation. This means this agent can penetrate in joint. Nutmeg shows antioxidative effect [17], the oxidative stress mediates rheumatoid pathogenesis [20], and thus it seems the effectiveness of nutmeg at present study may also relate to its antioxidative effect. Hocking et al. demonstrated

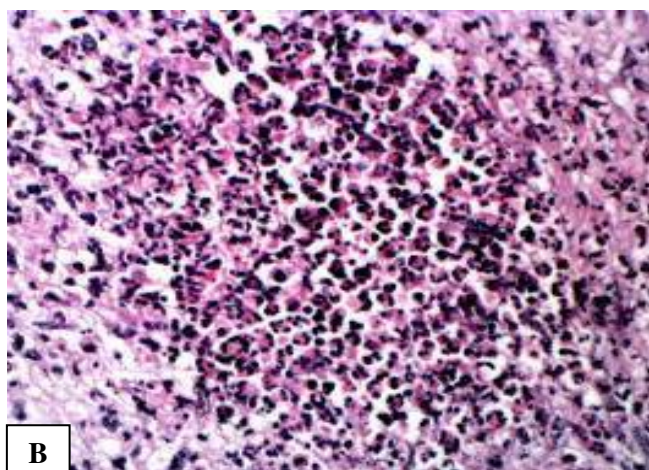
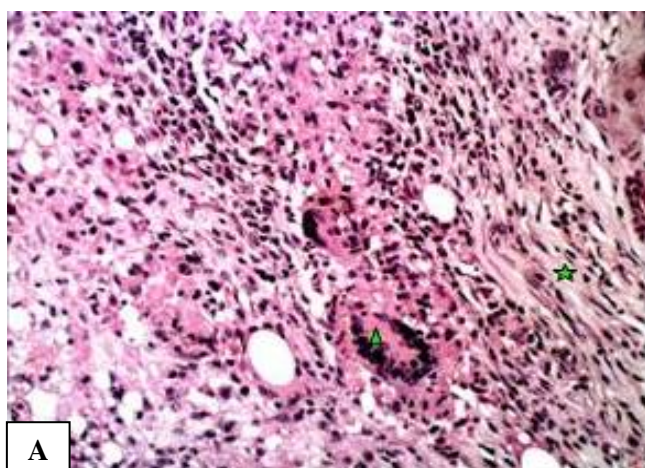


Figure 3. A. Illustration histopathological sections of the ankle joints of rats in group 2 received Freund's adjuvant and vehicle after 12 (up) and 21 (down) days. Stare shows polymorphonuclear cells and acute inflammation in left figure (H&E×40) and B. fibroblasts. Triangle shows giant cells in right figure (H&E×20)

flunixin is useful in treatment of inflammatory pain in domestic fowl using the microcrystalline sodium urate model of articular pain [23]. In conclusion, the present study indicates that nutmeg not only controls arthritis and the inflammation associated with joint synovitis, but also prevents cartilage and bone destruction of the arthritic joints of rats. Thus, Nutmeg may have potential for the further investigation in other animal models and clinical trials.

Acknowledgements

The authors wish to express their gratitude to the research council of Shahid Chamran University for their financial supports.

References

- Gabriel SE. The epidemiology of rheumatoid arthritis. *Rheum Dis Clin North Am* 2001; 27(2): 269-281.
- Pincus TE, Brooks RH, Callahan LF. Prediction of long-term mortality in patients with rheumatoid arthritis according to simple questionnaire and joint count measures. *Ann Intern Med* 1994; 120(1): 26-34.
- Firestein GS. Evolving concepts of rheumatoid arthritis. *Nature* 2003; 423(6937): 356-61.
- Feldmann M, Brennan FM, Maini RN. Role of cytokines in rheumatoid arthritis. *Annu Rev Immunol* 1996; 14: 397-440.
- Gravallese EM, Goldring SR. Cellular mechanism and the role of cytokines in bone erosions in rheumatoid arthritis. *Arthritis Rheum* 2000; 43(10): 2143-2151.
- Maruotti N, Cantatore FP, Crivellato E, et al. Angiogenesis in rheumatoid arthritis. *Histol Histopathol* 2006; 21(5): 557-66.
- Panayi GS, Lanchbury JS, Kingsley GH. The importance of the T cell in initiating and maintaining the chronic synovitis of rheumatoid arthritis. *Arthritis Rheum* 1992; 35(7): 729-735.
- Bugatti S, Codullo V, Caporali R and Montecucco C. B cells in rheumatoid arthritis. *Autoimmun Rev* 2007; 6(7): 137-142.
- Cai X, Zhou H, Wong YF, et al. Suppressive effects of QFGJS, a preparation from an anti-arthritis herbal formula, on rat experimental adjuvant-induced arthritis. *Biochem Biophys Res Commun* 2005; 337(2): 586-594.
- Orabi KY, Mossa JS, El-Ferally. Isolation and characterization of two antimicrobial agents from mace (*Myristica fragrans*). *J Nat Prod* 1991; 54(3): 856-9.
- Chhabra SK, Rao AR. Transmammary modulation of xenobiotic metabolizing enzymes in liver of mouse pups by mace (*Myristica fragrans* Houtt.). *J Ethnopharmacol* 1994; 42(3): 169-77.
- Jannu LN, Hussain SP, Rao AR. Chemopreventive action of mace (*Myristica fragrans*, Houtt.) on DMBA-induced papillomagenesis in the skin of mice. *Cancer Lett* 1991; 56(1): 59-63.
- Singh A, Rao AR. Modulatory effect of Areca nut on the action of mace (*Myristica fragrans*, Houtt.) on the hepatic detoxification systems in mice. *Food Chem Toxicol* 1993; 31(7): 517-21.
- Nakamura N, Kiuchi F, Tsuda Y and Kondo K. Studies on crude drugs effective on visceral larva migrans. V. The larvicidal principle in mace (aril of *Myristica fragrans*). *Chem Pharm Bull* 1988; 36(7): 2685-8.
- Ozaki Y, Soedigdo S, Wattimena YR and Suganda AG. Antiinflammatory effects of mace, aril of *Myristica fragrans* Houtt., and its active principles. *Jpn J Pharmacol* 1989; 49(2): 155-63.
- Saeki Y, Ito Y, Shibata M, et al. Antimicrobial action of natural substances on oral bacteria. *Bull Tokyo Dent Coll* 1989; 30(3): 129-35.
- Singh G, Marimuthu P, De Heluani Carola S and Catlan C. Antimicrobial and antioxidant potentials of essential oil and acetone extract of *Myristica fragrans* Houtt. (Aril part). *J Food Sci* 2005; 70(2): M141-8.
- Sonavane S, SarveiyaVP, Kasture VS and Kasture SB. Anxiogenic activity of *Myristica fragrans* seeds. *Pharmacol Biochem Behav* 2002; 71(1-2): 247-252.
- Schulz KL, Anderson DE, Coetzee JF, et al. Effect of flunixin meglumine on the amelioration of lameness in dairy steers with amphotericin B-induced transient synovitis-arthritis. *Am J Vet Res* 2011; 72(11): 1431-8.
- Weyand CM. New insights into the pathogenesis of rheumatoid arthritis. *Rheumatol* 2000; 39 Suppl 1: 3-8.
- Smolen JS, Steiner G. Therapeutic strategies for rheumatoid arthritis. *Nat Rev Drug Discov* 2003; 2(6): 473-488.
- Singh M, Hodges LD, Wright PF, et al. The CO₂-SFE crude lipid extract and the free fatty acid extract from *Perna canaliculus* have anti inflammatory effects on adjuvant-induced arthritis in rats. *Comp Biochem Physiol B Biochem Mol Biol* 2008; 149(2): 251-8.
- Hocking PM, Robertson GW, Gentle MJ. Effects of non-steroidal anti-inflammatory drugs on pain-related behaviour in a model of articular pain in the domestic fowl. *Res Vet Sci* 2005; 78(1): 69-75.

Authors' Contributions

All authors had equal role in design, work, statistical analysis and manuscript writing.

Conflict of Interest

The authors declare no conflict of interest.

Funding/Support

Shahid Chamran University of Ahvaz.