

## A Rare Anatomical Variation of the Brachial Plexus Characterized by the Absence of the Musculocutaneous Nerve

Alireza Ebrahimzadeh-Bideskan,\*<sup>1</sup> Mohammad Hossein Ebrahimzadeh,<sup>2</sup> Abbas Mohammadipour,<sup>1</sup> Elnaz Khordad<sup>1</sup>

1. Department of Anatomy and Cell Biology, Mashhad University of Medical Sciences, Mashhad, Iran
2. Orthopedic and Trauma Research Center, Ghaem Hospital, Mashhad University of Medical Sciences, Mashhad, Iran

Article information	Abstract
Article history: Received: 10 Nov 2012 Accepted: 5 Jan 2013 Available online: 26 May 2013 ZJRMS 2013; 15 (10): 74-77	Knowing of anatomical variations is very important during surgery, autopsy and cadaver dissection in the axillary region. In this study, a unilateral variation of the brachial nerve plexus, which is characterized by the absent of the musculocutaneous nerve (MCN), was found in the right arm of a male cadaver. The MCN normally originates from the lateral cord of the brachial nerve plexus and innervates the anterior brachial compartment muscles and lateral coetaneous of the forearm. In this case, the lateral cord of the brachial plexus was joined to the median nerve at the level of coracoid process with no evidence of any nerve braches from lateral cord to the anterior brachial compartment muscles. These muscles were innervated from some branches of median nerve directly.
Keywords: Variation Musculocutaneous nerve Brachial plexus Cadaver	

Copyright © 2013 Zahedan University of Medical Sciences. All rights reserved.

### Introduction

The brachial plexus is a somatic nerve plexus formed by intercommunications among the ventral rami of the spinal nerves C<sub>5</sub>-C<sub>8</sub> and T<sub>1</sub>. The ventral rami of C<sub>5</sub> and C<sub>6</sub> unite to form upper trunk, C<sub>7</sub> forms middle trunk and C<sub>8</sub> and T<sub>1</sub> unite to form the inferior trunk. Each of these three trunks divides into anterior and posterior divisions. All the posterior divisions unite to each other to form posterior cord. Anterior divisions of the upper and middle trunks get together to form lateral cord. The medial cord arose from anterior division of the lower trunk [1].

The median nerve is formed by gathering of two roots from the lateral (C<sub>5</sub>, C<sub>6</sub>, C<sub>7</sub>) and medial (C<sub>8</sub>, T<sub>1</sub>) cords. Usually, the medial root embraces the third part of the axillary artery and unites the lateral root to form median nerve. The median nerve enters the arm at first lateral to the brachial artery. Near the insertion of coracobrachialis muscle, it crosses in front of the brachial artery descending medial to it and enters to the cubital fossa without receiving or arising any other branch [1-3].

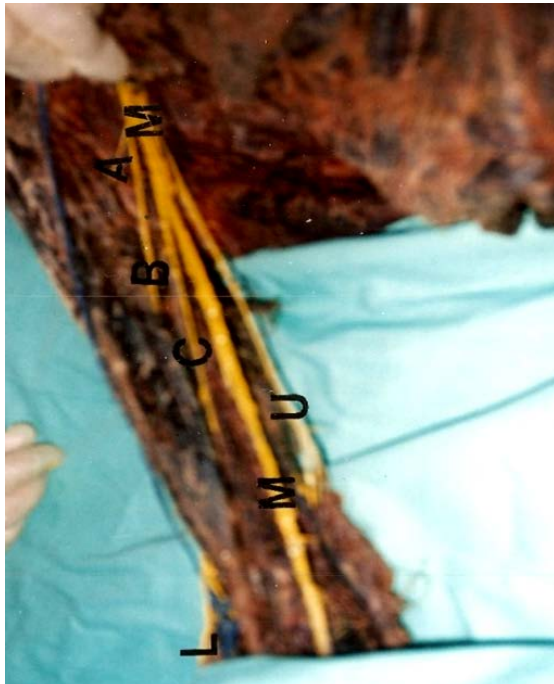
The MCN is one of the terminal branches of the lateral cord (fifth to seventh cervical ventral rami) of the brachial plexus. MCN usually pierces the coracobrachialis muscle and descends laterally between the biceps brachii and brachialis muscles and enters the front of the arm and continues as the lateral coetaneous nerve of forearm. It supplies the anterior brachial compartment muscles including bicepsbrachii, coracobrachialis and brachialis [1-3].

According to the formation pattern of the brachial nerve plexus that several spinal nerves unite and divide, the wide anatomical variations are expected [4, 5]. In this regard, some cases have reported many variations in the number of spinal nerves, communicating branches and

arising branches to form brachial nerve plexus [5]. However, there are few reports about the absence of terminal branches in brachial plexus such as MCN which are not similar to each others. Specially, the reported innervations of anterior brachial compartment muscles and their prevalence are not very clear [6]. Knowing of anatomical variations may provide valuable information about the paralysis caused by nerve impairment which helps avoiding the nerve impairment during surgery operations or the dissection of cadaver for training

### Case Presentation

During a routine anatomical dissection of a formalin-fixed Caucasian male cadaver in the students dissecting room of Mashhad University of Medical Sciences, an unusual unilateral variation was found in the right brachial nerve plexus which was characterized by the absent MCN. Generally MCN originates from the lateral cord of brachial nerve plexus and innervates the anterior brachial compartment muscles including coracobrachialis, biceps brachii, brachialis and lateral cutaneous of the forearm. In this case, lateral cord did not provide any motor branches to the anterior brachial compartment muscles and the MCN was absent completely. However, the above mentioned muscles were innervated by three motor branches of median nerve. Two out of three branches had the same origin with the upper position innervated coracobrachialis and biceps brachii muscles and the third branch had lower position rose from the median nerve for brachialis muscle (Fig. 1). Furthermore, the lateral cutaneous nerve of the forearm came from third branch of median nerve (Fig. 1).



**Figure 1.** Photograph of the anteromedial view of dissected right arm (present case). M: Median nerve, A: nerve to coracobrachialis muscle, B: nerve to bicepsbrachii muscle, C: nerve to brachialis muscle, L: lateral cutaneous of forearm. U: ulnar nerve

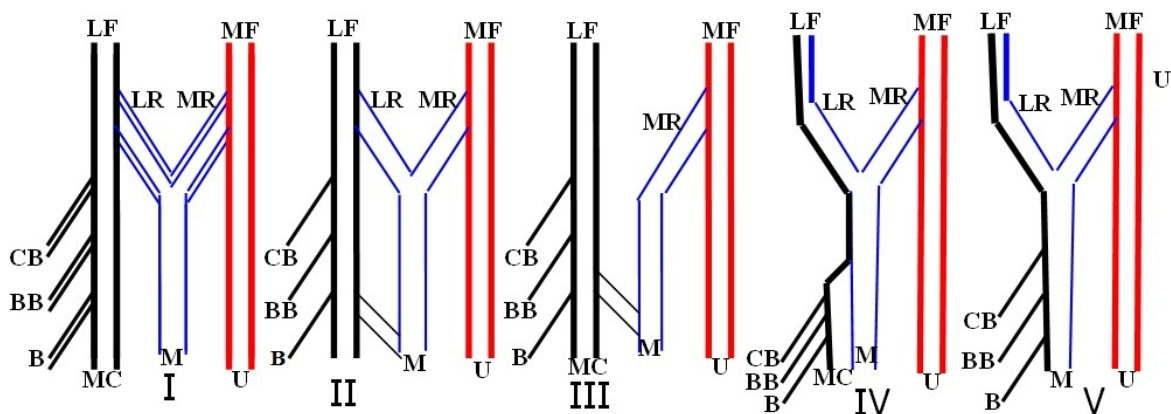
**Discussion**

Since the brachial nerve plexus is a complex structure variations in the course, its communications and distribution of its branches are common [4, 5]. The MCN is given off from lateral cord at the opposite of the lower border of the pectoralis minor muscle and pierces the coracobrachialis muscle and descends laterally between the bicepsbrachii and brachialis muscles to the lateral side of the arm. Just below the elbow it pierces the deep fascia laterally to the tendon of the biceps muscle and continuous as the lateral cutaneous nerve of the forearm [1-3, 7]. Several variations about the MCN on the basis of its origin, relations to the muscles of the arm, relations to the median nerve and its distributions have been reported by many researchers.

Regarding its origin, Tountas and Bergman reported that the MCN, in 90.5% cases, arose from lateral cord, in 4% cases from the lateral and posterior cord, in 2% from the median nerve, in 1.4% cases as two separate bundles from the medial and lateral cords and in 1.4% cases from the posterior cords [5, 8]. According to the communications pattern between the MCN and median nerve, five variations types (Fig. 2) were described and classified by Le Minor as follow:

Type 1: there is no communication between the median and MCN. Type 2: the medial root fibers of median nerve pass through the MCN and join the median nerve in the middle of the arm. Type 3: the lateral root fibers of medial root of median nerve pass through the MCN and after some distance, leave it to form the root of the median nerve. Type 4: the MCN fibers join the lateral root of the median nerve and after some distance the MCN arise from the median nerve. Type 5: the MCN is absent and the entire fibers of MCN passing through the lateral root and fibers to the muscles supplies by MCN branches arise directly from the median nerve [4, 9, 10].

Some authors such as Venieratos and Anagnostopoulou, based on the point of entry of the MCN in to the coracobrachialis, have described three variations types: Type I, in which the communication is proximal to where the MCN pierces the coracobrachialis muscle (41%); type II, communication between musculocutaneous and median nerves is distal to the point of entry in to the muscle (45.4%); and type III, in which the communication and the nerve not perforating the muscles (13%) [11-13]. According to another investigations data, these communications incidences have been 15-30%, 3-13% and 0-5% respectively [14, 15]. In addition, Loukas and Aqueelah added an additional type to Venieratos classification: type IV; communications were proximal to the point of entry of the MCN into the coracobrachialis and an additional communication took place, distally [16]. Other scientists published three types of connections between the MCN and the median nerve. Type1: Fusion of MC and median nerves. Type2: One, two or three connecting branch between the musculocutaneous and median nerves [17].

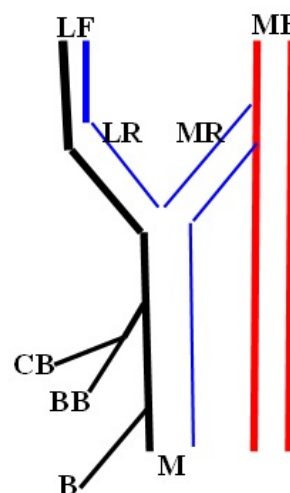


**Figure 2.** Schematic illustrations show five variation types of Le Minor classification. MF: medial cord, LF: lateral cord, MC: musculocutaneous, U: ulnar nerve, B: brachialis muscle, BB: bicepsbrachii, CB: coracobrachialis muscle

Kosugi et al. grouped the branching pattern of the MCN in to five groups including pattern without communication, communicating branch from the MCN to median nerve, a branch from median nerve to MCN, both reciprocal communication and other pattern [18]. Yang et al. arranged the innervations of biceps and brachialis muscles in to three types: Type I: a primary motor branch divided into two secondary nerve branches, each innervating the long and short head of biceps brachii, separately. Type II: two primary motor branches from the main MCN trunk. The proximal branch innervates the short head of the biceps and the distal branch innervates the long head of the biceps. Type III: primary motor branch from the main musculocutaneous nerve trunk that divides into two secondary branches to individually innervate the two heads of the biceps, plus an additional primary branch, distal to the former that innervates the distal part of the biceps at its common belly [19, 20]. When the MCN was absent, a communicating branch from the median to ulnar nerves was found in the forearm and the long thoracic nerve including the fibers from C<sub>5</sub> and C<sub>6</sub> [21]. But in the present case, there was not found any communicating branch with the ulnar nerve and the long thoracic nerve formed by the fibers from C<sub>6</sub> to C<sub>7</sub>. Other scientist stated a case in which the lateral fasciculus stabbed the coracobrachialis muscle and then one of its terminal branches joined the medial root forming the median nerve [22].

In our case, no MCN was observed. Although other scientists stated the absence of the MCN variations, but in their cases, the motor nerve to coracobrachialis arose from the lateral cord, and the motor nerves to the biceps brachii and brachialis arose from the median nerve [13]. Although above mentioned variation is similar to the present case but in the present case the entire anterior brachial compartment muscles were directly innervated by the nerve branches originated from the median nerve. The present case is comparable to the type 5 of Le Minor classification but does not completely coincide with it. In our case, we found that in the right upper limb of a male cadaver the median nerve had two roots and the MCN was absent and the entire fibers of the MCN passed through the lateral root. According to our data, we propose an additional type to the Le minor classification: type VI; the MCN is absent and the entire fibers of MCN

pass through lateral root and fibers to the muscles supplies by MCN branches, arise from the median nerve by two branches (Fig. 3).



**Figure 3.** Schematic illustration shows a suggested additional variation type to the Le Minor classification. MF: medial cord, LF: lateral cord, LAC: lateral ante brachial cutaneous nerve, MC: musculocutaneous, U: ulnar nerve, B: brachial muscle, BB: biceps brachii, CB: coracobrachialis muscle

Finally, it is concluded that there are different variations in the MCN; median nerve and anterior brachial compartment muscles innervations. Knowledge of the possible anatomical variations, especially in the brachial plexus such as absence of MCN has clinical importance especially in traumatology, in relations to repair operations, autopsy and dissection of cadaver during medical student training.

#### Authors' Contributions

All authors had equal role in design, work, statistical analysis and manuscript writing.

#### Conflict of Interest

The authors declare no conflict of interest.

\*Corresponding author at: Department of Anatomy and cell Biology, Mashhad University of Medical Sciences, Mashhad, Iran.  
E-mail: Ebrahimzadehba@mums.ac.ir

#### References

- Williams PL, Warwick R, Dyson M, editors. Gray's anatomy. 37<sup>th</sup> ed. London: Churchill Livingstone; 1999: 1130-1132.
- McMinn RM. Last's Anatomy. 9<sup>th</sup> ed. Singapore: Churchill Livingstone; 1994: 68.
- Snell RS. Clinical anatomy for medical students. 4<sup>th</sup> ed. Little Boston: Brown and Company; 1992: 442-447.
- Aydin ME, Kale A, Edizer M, et al. Absence of the musculocutaneous nerve together with unusual innervation of the median nerve. *Folia Morphol* 2006; 65(3): 228-31.
- Arota L, Dhingra R. Absence of musculocutaneous nerve and accessory head of biceps brachii: A case report. *Indian J Plast Surg* 2005; 38(2): 144-146.
- Satheesha N, Vijay PS, Nagabhooshna S. Concurrent variation of median nerve, musculocutaneous nerve and biceps brachii muscle. *Neuroanatomy* 2006; 5: 30-32.
- Jahanshahi M, Mohaaeri AR, Golalipour MJ. A variation of brachial plexus: Absence of musculocutaneous nerve. *Natl Med J India* 2003; 1(6): 87-90.
- Tountas C, Bergman R. *Anatomic variations of the upper extremity*. New York: Churchill Livingstone; 1993: 223-224.
- Le Minor JM. [Rare variations of the median and musculocutaneous nerves in man] French [Abstract]. *Arch Anat Histol Embryol* 1990; 37: 33-42.

10. Guerri-Guttenberg RA, Ingolotti M. Classifying musculocutaneous nerve variations. *Clin Anat* 2009; 22(6): 671-83.
11. Venieratos D, Anagnostopoulou S. Classification of communications between the musculocutaneous and median nerves. *Clin Anat* 1998; 11(5): 327-331.
12. Prasada Rao PV, Chaudhary SC. Communication of the musculocutaneous nerve with the median nerve. *East Afr Med J* 2000; 77(9): 498-503.
13. Prasada Rao PV, Chaudhary SC. Absence of musculocutaneous nerve: Two case reports. *Clin Anat* 2001; 14(1): 31-35.
14. Song WC, Jung HS, Kim HJ, et al. A variation of the musculocutaneous nerve absent. *Yonsei Med J* 2003; 44(6): 1110-3.
15. Jose H, Maria I, Celiana S, et al. Absence of the musculocutaneous nerve: A rare anatomical variation with possible clinical-surgical implication. *Sao Paulo Med J* 2008; 126(5): 288-90.
16. Loukas M, Aqueelah H. Musculocutaneous and median nerve connections within, proximal and distal to the coracobrachialis muscle. *Folia Morphol (Warsz)* 2005; 64(2): 101-8.
17. Choi D, Rodriguez-Niedenfuhr M, Vazquez T, et al. Patterns of connections between the musculocutaneous and median nerves in the axilla and arm. *Clin Anat* 2002; 15(1): 11-17.
18. Kosugi K, Shibata S, Yamashita H. Supernumerary head of biceps brachii and branching pattern of the musculocutaneous nerve in Japanese. *Surg Radiol Anat* 1992; 14(2): 175-185.
19. Yang ZX, Pho RW, Kour AK and Pereira BP. The musculocutaneous nerve and its branches to the biceps and brachialis muscles. *J Hand Surg Am* 1995; 20(4): 671-675.
20. Pandey SK, Shukla VK. Anatomical variations of the cords of brachial plexus and the median nerve. *Clin Anat* 2007; 20(2): 150-6.
21. Gumusburun E, Adiguzel E. A variation of the brachial plexus characterized by the absence of the musculocutaneous nerve: A case report. *Surg Radiol Anat* 2000; 22(1): 63-5.
22. Fregnani JH, Macea MI, Pereira CS, et al. Absence of the musculocutaneous nerve: A rare anatomical variation with possible clinical-surgical implications. *Sao Paulo Med J* 2008; 126(5): 288-90.

**Please cite this article as:** Ebrahimzadeh-Bideskan A, Ebrahimzadeh MH, Mohammadipour A, Khordad E. A rare anatomical variation of the brachial plexus characterized by the absence of the musculocutaneous nerve. *Zahedan J Res Med Sci (ZJRMS)* 2013; 15(10): 74-77.