

## The Effects of Hydro-Alcoholic Extract of *Zingiber Officinale* on Prevention from Plumbism in Kidney Tissue of Neonatal Rats

Habiballah Johari,<sup>\*1</sup> Fatemeh Delirnasab,<sup>2</sup> Esfandiar Sharifi,<sup>2</sup> Vahid Hemayat-Khah,<sup>3</sup> Mohammadali Pourdaneh,<sup>4</sup> Hosein Kargar,<sup>3</sup> Maryam Nikpour,<sup>5</sup> Mohammad Yazdani<sup>6</sup>

1. Department of Physiology, Darab Branch, Islamic Azad University, Darab, Iran
2. Department of Physiology, Kazeron Branch, Islamic Azad University, Kazeron, Iran
3. Department of Physiology, Jahrom Branch, Islamic Azad University, Jahrom, Iran
4. Department of Histology, Jahrom Branch, Islamic Azad University, Jahrom, Iran
5. Student Research Committee, International Branch, Shiraz University of Medical Science, Shiraz, Iran
6. Department of Agriculture, Firouz-Abad Branch, Islamic Azad University, Firouz Abad, Iran

### Article information

Article history:  
Received: 17 Oct 2011  
Accepted: 16 Nov 2011  
Available online: 30 Dec 2012  
ZJRMS 2013; 15(8): 13-17

Keywords:  
*Zingiber officinale* (ginger)  
Lead  
Kidney  
Rats  
Poisoning

\*Corresponding author at:  
Department of Physiology,  
Darab Branch, Islamic Azad  
University, Darab, Iran  
E-mail:  
hjewhary@yahoo.co.uk

### Abstract

**Background:** In the present research, the effects of hydro-alcoholic extract of *Zingiber officinale* (ginger) on treating lead-poisoned kidney of neonatal rats was studied.

**Materials and Methods:** This research was conducted as a laboratory work. The neonatal rats were divided into 7 groups of 10 samples. The first control group received no treatment. The second control group received 0.1 mg of distilled water. As an experimental group, the one received an amount of 0.6 g/l lead. The fourth group received only 2 g/kg body weight of hydro-alcoholic extract of ginger. Groups 5 to 7 each initially received 0.6 g/l lead and then amounts of 0.5, 1 and 2 g/kg hydro-alcoholic extract of ginger. The injections were administered via oral gavage during 10 consecutive days.

**Results:** According to the obtained results, the body and kidney weights showed a significant reduction in experimental groups that had received amounts of 1 and 2 g/kg in comparison with the group that had received lead. The kidney weight of the group that had received only extract showed no significant difference in comparison with the control group. As for the body weights, however, it showed a significant increase. Moreover, the body and kidney weights of the lead-injected group showed a significant increase in comparison with the control group.

**Conclusion:** Lead can cause damage to kidney tissues. Due to its antioxidant and protective effect, ginger can be a medication to nephrotoxicity of lead and prevent kidney tissues from destruction.

Copyright © 2013 Zahedan University of Medical Sciences. All rights reserved.

## Introduction

Since the primitive humans realized the value of medicinal plants, most diseases have been cured and human health ensured. In fact, the treatment of most human ailments and discomforts can be found in the nature, on which humans are dependent. Ginger is the rhizome of the plant *Zingiber officinale*, cultivation of which has been widely spread from East Asia to tropical regions of Australia.

Ginger contains several compounds such as gingerol, shogaol, zingiberene, paradol, resin, starch, volatile oil and vitamins C and A [1]. In addition, this plant contains the highest amount of antioxidant which mainly includes gingirol and shogaol [2-5]. Traditionally, ginger has been applied for treating colic, flatulence, indigestion, stomach ulcers, rheumatism, fever, joint problems, constipation, catarrh, and asthma, infectious and parasitic diseases [6-11].

Furthermore, ginger has anti-cancer, anti-inflammatory properties as well as anti-nausea/vomiting and antioxidant properties [12-17]. Ginger may contribute to coagulation by diminishing the production of thromboxane B<sub>2</sub> and

prostaglandin E<sub>2</sub> in blood platelets. It also has a deterrent effect on blood pressure drop by stimulation of muscarinic receptors and blockage of the Ca<sup>2+</sup> channel [18, 19]. Hence, it was indicated that inhibition of cyclooxygenase (COX) activity by gingerol and the related analogues is actually a mechanism the effect of which on arachidonic acid would lead to stimulation of antiplatelet activity [20, 21].

The usage of lead as a natural element almost dates back to the early human civilizations. Nowadays, lead is used to produce batteries, cable coatings, ceramics, pipelines, gasoline, etc. This natural metal can be found in water and soil. It enters the human body through either gastrointestinal or respiratory system [22]. In various ways, lead affects hematopoiesis, nervous system, reproduction, kidneys and bones. The symptoms of plumbism include gastrointestinal, colic, weight loss, weakness, anemia, brain damage, memory and learning failure, male infertility due to impaired sperm, abortion due to fetal abnormalities and kidney damage [23-25]. In comparison with other body tissues, kidney is where the

highest amount of lead is accumulated leading to certain pathobiological changes in renal structure and function. The symptoms of acute lead poisoning in kidneys include glycosuria, aminoaciduria, and phosphaturia [23, 25, 26].

In the present research, the effects of hydro-alcoholic extract of *Zingiber officinale* (ginger) on treating lead-poisoned kidney of neonatal rats was studied. Since the objective was to tackle the problem of infants, several neonatal rats were chosen to be examined.

## Materials and Methods

This research was conducted as a laboratory work in which the code of professional ethics regarding laboratory animals was entirely complied with. Therefore, a total of 70 neonatal rats, each 33 to 35 days of age, weighting 70 to 80 grams, were brought from the center for animal breeding and maintenance at Shiraz University.

In order for the samples to adapt with the environments prior to the experiments, they were all kept in an animal house at Azad University of Kazeroun for a few days. The animals were fed with compressed food products supplied by Shiraz Livestock and Poultry Co. The photoperiod was planned for 12 hours of light and 12 hours of darkness. The ambient temperature was set for  $23\pm 2^{\circ}\text{C}$  with relative humidity of 51-56%. The room air was filtered by a ventilator. The rats were placed inside special cages which were cleaned and disinfected every three days. As for preparing the ginger extract, the method designed by Samsam-zadeh was employed [27].

The rats were divided into 7 groups of 10 samples. The control group received no treatment. As an experimental group kept in the similar condition, the second one received 0.1 mg of distilled water every day. The third group received an amount of 0.6 g/l lead acetate. The fourth group received only 2 g/kg of ginger extract. The last three experimental groups initially received 0.6 g/l lead acetate and then amounts of 0.5, 1 and 2 g/kg of ginger extract.

The injection of both compounds was administered via gavage tube for 10 days. At the end of this period, each animal was weighted through a mild anesthesia. Next, the kidneys of each rat were removed and weighted by a standard procedure. The renal samples were then kept in formalin. The prepared tissue samples were sliced by a microtome with a desired thickness of 5  $\mu\text{m}$  for each section.

Having gone through the stage of tissue processing, each sample was stained by Hematoxylin and Eosin method. Finally, the isolated slides were examined through an optical microscope (Nikon 8ii, made in Japan) in terms of histological modifications. For data analysis, the statistical *t*-test was employed and  $p\leq 0.05$  was considered to be significant.

## Results

Lead acetate at the dose of 0.6 g/l resulted in a significant increase in the body and kidney weights as compared with the control group;  $p\leq 0.05$  (Table 1). Furthermore, tissue destruction was observed in the lead-injected group in contrast with the control (Fig. 1, 2).

The injection of hydro-alcoholic extract of ginger in the group that had received only extract brought about a significant decrease in the body weights in comparison with the control. As for the kidney weights, however, no significant difference was observed;  $p\leq 0.05$  (Table 1) similarly, no tissue destruction was observed in this group as compared with the control (Fig. 3).

The injection of hydro-alcoholic extract of ginger at amounts of 1 and 2 g/kg showed a significant decrease in the body and kidney weights in comparison with the lead-injected group. At amount of 0.5 g/kg, however, there was no significant body weight difference with the lead-injected group (Table 1). In these groups, tissue destruction was not observed at the dose of 2 g/kg. In contrast, there was tissue destruction at 0.5 and 1 g/kg even though with lower intensity as compared to the lead-injected group (Fig. 4, 5 and 6). Histological modification refers to apoptosis and necrosis which occur in various parts of nephrons.

## Discussion

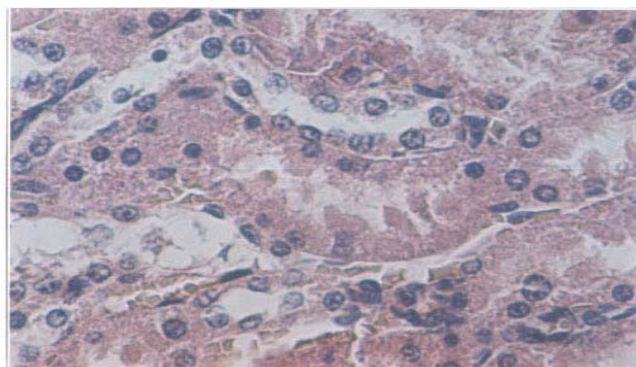
The results obtained from the present research suggest that growth and development in lead-injected rats were accompanied by body weight gain as well as significant increase in the kidney weights as compared to the control group. The weight gain in the lead-fed rats was a consequence of lead accumulation in their body organs. The kidney weight, however, originated from inflammation and cell proliferation in renal tissues [13, 22].

**Table 1.** Comparison of two control groups and five experimental groups in terms of body weight and kidney weight

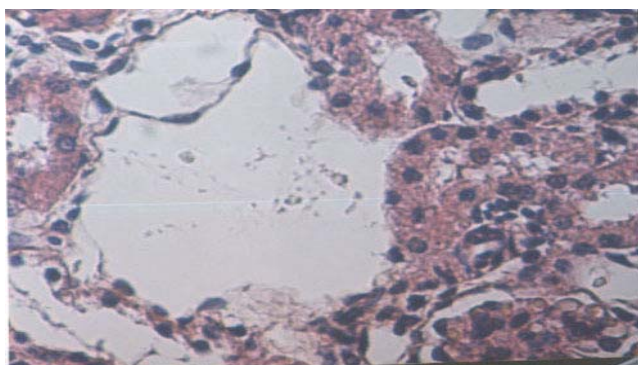
Parameter Group	Body weight (gr)	Kidney weight (gr)
Control 1	84 $\pm$ 1.194	0.5 $\pm$ 0.017
Control 2	86 $\pm$ 1.193	0.46 $\pm$ 0.015
Lead-injected (0.6 g/l)	89 $\pm$ 2.514**	0.6 $\pm$ 0.01**
Extract-injected (2 g/kg)	85 $\pm$ 1.925**	0.52 $\pm$ 0.023
Lead-injected (0.6 g/l) along with extract (0.5 g/l)	88 $\pm$ 1.505	0.58 $\pm$ 0.020
Lead-injected (0.6 g/l) along with extract (0.1 g/kg)	87 $\pm$ 1.280*	0.56 $\pm$ 0.011*
Lead-injected (0.6 g/l) along with extract (2 g/kg)	86 $\pm$ 1.013*	0.55 $\pm$ 0.018*

**Note:** The average weights marked with one asterisk (\*) represent a significant difference at  $p\leq 0.05$  in comparison with the lead-injected group. The average weights marked with two asterisks (\*\*) represent a significant difference at  $p\leq 0.05$  in comparison with the control group.

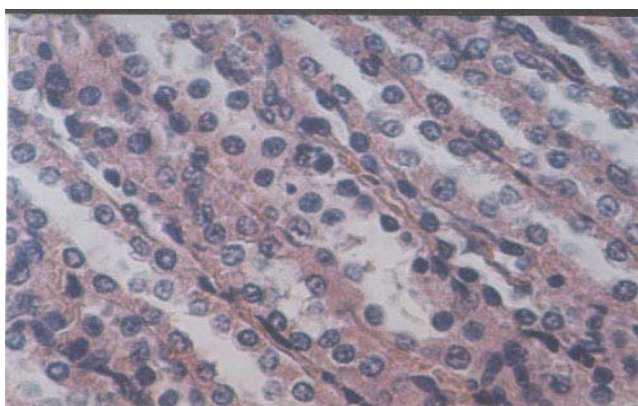




**Figure 1.** Kidney tissue in the control group (x400)



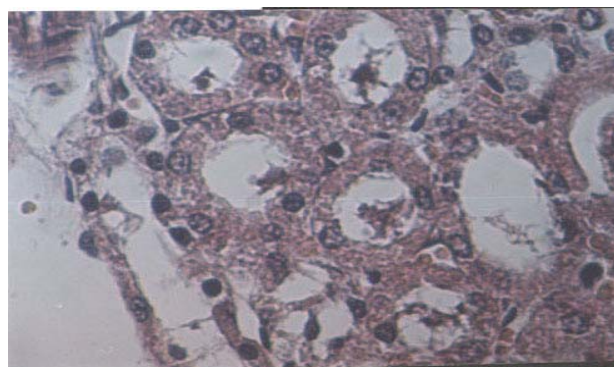
**Figure 2.** Kidney tissue in the lead-injected group (x400)



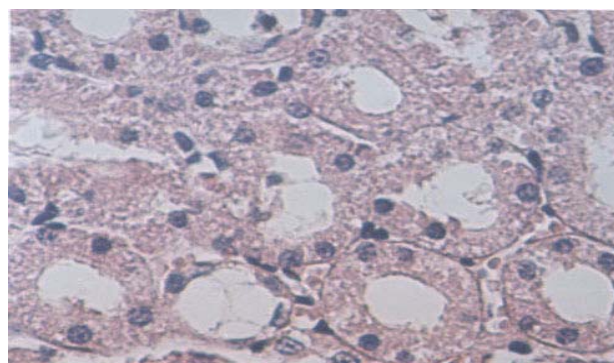
**Figure 3.** Kidney tissue in the group that received hydro-alcoholic extract of garlic at amount of 2 g/kg (x400)

Previous studies have indicated that lead competes with calcium to take over the binding sites of calcium-receptor proteins such as calmodulin, kalsmy medians, Protein kinase C, troponin, and so on. Such replacement would interfere with the receptor system. Calcium and diacylglycerols would in turn cause malfunction of kinase C enzyme activating a wide range of kinases and phosphatases, which would ultimately affect the process of cell division, proliferation, and communication [29, 30].

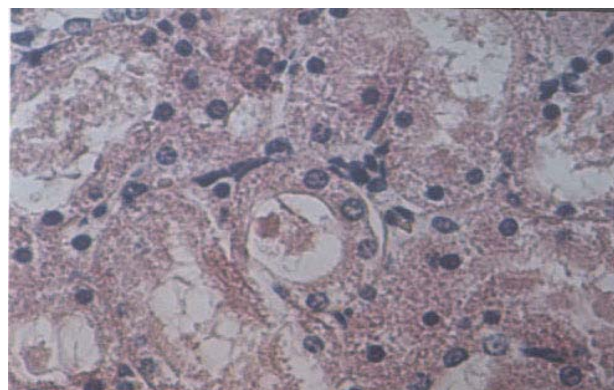
In other words, lead would most likely get involved as a consequence of kinase C enzyme malfunction and receptor system failure, which result in lesions and tissue changes of kidneys. The renal lead-binding proteins such



**Figure 4.** Kidney tissue in the lead-injected group along with 0.5 g/kg of hydro-alcoholic extract of garlic (x400)



**Figure 5.** Kidney tissue in the lead-injected group along with 1 g/kg of hydro-alcoholic extract of garlic (x400)



**Figure 6.** Kidney tissue in the lead-injected group along with 2 g/kg of hydro-alcoholic extract of garlic (x400)

as alpha-2 myoglobin induce apoptosis and necrosis in the proximal convoluted tubule of kidneys [31]. Glutathione peroxidase is an antioxidant enzyme whose increased activity would hinder the lipid peroxidation reaction. Lead would most likely deactivate such enzyme by intensification of the lipid peroxidation and free radicals, which eventually causes tissue damage. Moreover, the specific renal lead-binding proteins such as alpha-2 myoglobin pack together having a cleavage-N-terminal product. The accumulation of these proteins in the renal tubule would result in their death and tissue destruction [31, 31].

The simultaneous injection of ginger hydro-alcoholic extract reduced renal tissue destruction in comparison

with the lead-fed group, which implies that ginger extract has an antioxidant property and protective effect on renal cells against lead-caused damage. In addition, ginger contains phenolic compounds such as gingerol, gingerdiol, fene, and shogaol which have antioxidant property [4, 5]. Phenolic and ethanol compounds can protect renal cells in several ways including neutralization of the lipid peroxidation and free radicals, and instigation of renal cell repair [8, 32]. Antioxidants can decrease tissue damage through blocking the lipid peroxidation and oxidative pathways. [33] Ginger can prevent nephrotoxicity of cadmium diminishing it in the liver. The phenolic compounds of ginger have protective effects on hepatic cells treated with thioacetamide [34].

The results obtained from this research suggest that growth and development in ginger-injected rats were accompanied by weight gain in comparison with the control group. Due to its oxygen groups; ginger can act as a ligand forming metal complexes with lead, which is the possible reason why it prevents lead accumulation in kidneys [24].

Ginger contains vitamin A which contributes to regulation of body growth and fat reserves. Retinoids can result in body weight gain by storing fat as triglycerides. Ginger contains vitamin B<sub>6</sub> which can result in body weight gain by intensification of the protein synthesis [1, 35]. Since ginger induces polyphagia in the laboratory rats, there is the possibility that phenolic compounds

stimulate the feeding control in the central nervous system followed by body weight gain [35]. Concerning the histological modifications seen in the kidneys, it can be concluded that lead can cause tissue damage, while ginger, due to its antioxidant property and protective effect from phenolic and ethanol compounds oxygen groups as ligand and vitamin A, attenuates the nephrotoxicity of lead and ultimately prevents renal tissue destruction.

### Acknowledgements

The results of the present research were reported based on a Master's thesis by Ms. Masoumeh Dalirnasab, a physiology student at Islamic Azad University, Kazeroun branch. Hereby, we would like to express our gratitude to the head of physiology lab who took a part in operating this project.

### Authors' Contributions

All authors had equal role in design, work, statistical analysis and manuscript writing.

### Conflict of Interest

The authors declare no conflict of interest.

### Funding/Support

Islamic Azad University, Darab.

### References

1. Ali BH, Blunden G, Tanira MO and Nemmar A. Some phytochemical pharmacological and toxicological properties of ginger (*Zinger officinale* Roscoe): A review of recent research. *Food Chem Toxicol* 2008; 46(2):409-20.
2. Taghizadeh-Afshari A, Shirpoor A, et al. The effect of ginger on diabetic nephropathy, Plasma antioxidant capacity and lipid peroxidation in rats. *Food Chemistry* 2007; 101(1): 148-153.
3. Wang CC, Chen LG, Lee LT, et al. Effects of 6-gingerol an antioxidant from ginger, on inducing apoptosis in human leukemic HL-60 cells. *In Vivo* 2003; 17(6): 641-645.
4. Ahmed RS, Seth V, Banerjee BD. Influence of dietary ginger (*Zingiber officinales* Rosc) on antioxidant defense system in rat comparison with ascorbic acid. *Indian J Exp Biol* 2000; 38(6): 604-606.
5. Sekiwa Y, Kubota K, Kobayashi A. Isolation of Novel glucosides related to gingerdiol from ginger and their antioxidative activities. *J Agric Food Chem* 2000; 48(2): 373-377.
6. Apariman S, Ratchanon S, Wiriyasirive JB. Effectiveness of ginger for prevention of nausea and vomiting after gynecological laparoscopy. *J Med Assoc Thai* 2006; 89(12): 2003-9.
7. Chaiyakunapruk N. The efficacy of ginger for the prevention of postoperative nausea and vomiting: A meta-analysis. *Am J Obstet Gynecol* 2006; 194(1): 95-99.
8. Fuhrman B, Rosenblat M, Hayek T, et al. Ginger extract consumption reduces plasma cholesterol, inhibits LDL oxidation, and attenuates development of atherosclerosis in atherosclerotic, apolipoprotein E-deficient mice. *J Nutr* 2000; 130(5): 1124-1131.
9. Mahady GB, Pendland SL, Yun GS, et al. Ginger (*Zingiber officinale* Roscoe) and the gingerols inhibit the growth of cag A+ strains of *Helicobacter pylori*. *Anticancer Res* 2003; 23(5A): 3699-3702.
10. Willetts KE, Ekangaki A, Eden JA. Effect of a ginger extract on pregnancy-induced nausea: A randomised controlled trial. *Aust N Z J Obstet Gynaecol* 2003; 43(2): 139-144.
11. Jaw-Chyun C, Huang LJ, Wu SL, et al. Ginger and its bioactive component inhibit enterotoxigenic *Escherichia coli* heat-labile enterotoxin-induced diarrhoea in mice. *J Agric Food Chem* 2007; 55(21): 8390-8397.
12. Grzanna R, Lindmark L, Frondoza CG. Ginger- an herbal medicinal product with broad anti-inflammatory actions. *J Med Food* 2005; 8(2): 125-132.
13. Young HY, Luo YL, Cheng HY and Hsieh WC. Analgesic and anti-inflammatory activities of [6]- gingerol. *J Ethnopharmacol* 2005; 96(1-2): 207-210.
14. Bode AM, Ma WY, Surh YJ and Dong Z. Inhibition of epidermal growth factor induced cell transformation and activator protein 1 activation by 6-gingerol. *Cancer Res* 2001; 61(3): 850-853.
15. Ando T, Maeda O, Ohmiya N, et al. Ginger-molecular multitasking against gastric cancer. *Biochem Biophys Res Commun* 2007; 362(1): 218-223.
16. Manju V, Nalini N. Chemopreventive efficacy of ginger, a naturally occurring anticarcinogen during the initiation, post-initiation stages of 1,2 dimethylhydrazine-induced colon cancer. *Clin Chim Acta* 2005; 358(1-2): 60-67.
17. Portnoi G, Chng LA, Karimi-Tabesh L. Prospective comparative study of the safety and effectiveness of ginger

- for the treatment of nausea and vomiting in pregnancy. *Am J Obstet Gynecol* 2003; 189(5): 1374-1377.
18. Yonug HY, Liao JC, Chang YS, et al. Synergistic effect of ginger and nifedipine on human platelet aggregation: A study in hypertensive patients and normal volunteers. *Am J Chin Med* 2006; 34(4): 545-551.
  19. Kruth P, Brosi E, Fux R. Ginger-associated over anticoagulation by phenprocoumon. *Ann Phaymacother* 2004; 38(2): 257-260.
  20. Nurtjahia-Tjendraputa E, Ammit AJ, Roufogalis BD. Effective anti-platelet and COX-1 enzyme inhibitors from pungent constituents of ginger. *Thromb Res* 2003; 111(4-5): 259-265.
  21. Kim So, Kundu JK, Shin YK, et al. 6-gingerol inhibits COX-2 expression by blocking the activation of P38 MAP kinase and NF-kappa B in phorbol ester-stimulated mouse skin. *Oncogene* 2005; 24(15): 2558-2567.
  22. Kazantzis G. Role of cobalt, iron, lead, manganese, mercury, platinum, Seleniun, and titanium in carcinogenesis. *Environ Health Perspect* 1981; 40: 143-161.
  23. Abdelouahab N, Mergler D, Tukser L, et al. Gender differences in the effects of organochlorines, mercury, and lead on thyroid hormone levels in lake side communities of Quebec (Canada). *Environ Res* 2006; 107(3): 380-392.
  24. Telisman S, Colak B, Pizent A, et al. Reproductive toxicity of low-level lead exposure in men. *Environ Res* 2007; 105(2): 256-266.
  25. Zhu ZW, Yang RL, Dong GJ and Zhao ZY. Study on the neurotoxic effect of low-level lead exposure in rats. *J Zhejiang Univ Sci* 2005; 6B(7): 686-692.
  26. Sanchez S, Aguilar RP, Genta S, et al. Renal extracellular matrix alterations in lead- treated rats. *J Appl Toxicol* 2001; 21(5): 417-423.
  27. Samsamzade-Shariat SH. [Extraction of effective matter and methods of identification and evaluate of medical plants] Persian. Tehran: Mani Press; 1992: 14-18.
  28. Witzmann FA, Fultz CD, Grant RA, editors. Regional Protein alterations in rat kidneys induced by lead exposure. *Electrophoresis* 1999; 20(4-5): 943-51.
  29. Ni Z, Hou S, Barton CH and Vaziri ND. Lead exposure raises superoxide and hydrogen peroxide in human endothelial and vascular smooth muscle cells. *Kidney Int* 2004; 66(6): 2329-2336.
  30. Vaziri ND, Lin CY, Farmand F and Sindhu RK. Superoxide dismutase, catalase, glutathione peroxidase and NADPH oxidase in lead-induced hypertension. *Kidney Int* 2003; 63(1): 186-194.
  31. Dagget DA, Nuwaysir EF, Nelson SA, et al. Effects of triethyl lead administration on the expression of glutathione S-transferase isoenzymes and quinone reductase in rat kidney and liver. *Toxicology* 1997; 117(1): 61-71.
  32. Lee SH, Cekanova M, Baek SJ. Multiple mechanisms are involved in 6-gingerol-induced cell growth arrest and apoptosis in human colorectal cancer cells. *Mol Carcinog* 2008; 47(3): 197-208.
  33. Verma RJ, Asnani V. Ginger extract ameliorates paraben induced biochemical changes in liver and kidney of mice. *Acta Polonia Pharm Drug Res* 2007; 64(3): 217-220.
  34. Egwurugwu JN, Ufearo CS, Abanobi OC, et al. Effects of ginger (*Zingiber officinale*) on cadmium toxicity. *African J Bitlechnol* 2007; 6(18): 2078-2082.
  35. Goyall RK, Kadnur SV. Beneficial effects of *Zingiber officinale* on old thioglucose induced obesity. *Fitoterapia* 2006; 77(3): 160-163.

**Please cite this article as:** Johari H, Delirnasab F, Sharifi E, Hemayat-Khah V, Pourdaneh MA, Kargar H, Nikpour M, Yazdani M. The effects of hydro-alcoholic extract of zingiber officinale on prevention from plumbism in kidney tissue of neonatal rats. *Zahedan J Res Med Sci (ZJRMS)* 2013; 15(8): 13-17.