

Definition of Success Rate of Appendectomy without Peritoneal Lavage in Children with Generalized Appendicular Peritonitis

Mehdi Fathi,¹ Marjan Joudi^{*2} Mehran Hiraifar,² Mohammad Mehdi Kamyar,³ Maryam Joudi⁴

1. Department of Cardiac Anesthesia, Mashhad University of Medical Sciences, Mashhad, Iran
2. Department of Pediatric Surgery, Mashhad University of Medical Sciences, Mashhad, Iran
3. General Surgeon, Mashhad University of Medical Sciences, Mashhad, Iran
4. Department of Pediatrics, Zahedan University of Medical Sciences, Zahedan, Iran

Article information	Abstract
<p>Article history: Received: 30 Jan 2011 Accepted: 9 Apr 2011 Available online: 29 Dec 2011</p>	<p>Background: Peritonitis can be managed through local restoration, debridement during operation, lavage and a number of post-operative techniques such as drainage, continuous peritoneal lavage and re-operation in order to remove infective agents from the abdominal cavity as a way to prevent persistent peritonitis and sepsis. In this study, the results and complications caused by appendectomy without [diagnostic] peritoneal lavage in children with appendicular peritonitis were dealt with.</p> <p>Materials and Methods: A number of 30 children with the generalized peritonitis, a complication of perforated appendicitis, were studied. Fifty mg/kg ceftriaxone, 30 mg/kg metronidazole and sedatives were prescribed for all patients. Surgeries were performed by a single surgeon through making a small transverse incision in the right lower quadrant of the abdomen which included appendectomy and removing purulent discharges and debris collected around appendix without conducting peritoneal lavage. After surgery, the patients were examined in terms of incidence of complications, any more surgeries and treatment success for 6 weeks.</p> <p>Results: Five patients developed wound infection and three patients developed abdominal abscess. No early obstruction after surgery was seen. Peritonitis in all patients was controlled with appendectomy and antibiotic therapy and relaparotomy was not practiced for any patient.</p> <p>Conclusion: With regard to simplicity and high speed of appendectomy without cleansing peritoneum and its shorter incision and similar complications with other studies, and its considerable success to control the disease progress and unnecessary relaparotomy for the patients used this method, it seems that this method can be a good substitution for the conventional method of making long incision at midline of the abdomen and cleansing peritoneum.</p>
<p>Keywords: Appendicular peritonitis Appendectomy Relaparotomy</p>	
<p>*Corresponding author at: Department of Pediatric Surgery, Mashhad University of Medical Sciences, Mashhad, Iran. E-mail: joodim@mums.ac.ir</p>	
Copyright © 2012 Zahedan University of Medical Sciences. All rights reserved.	

Introduction

Appendicitis is the most common surgical critical condition. Rate of appendicitis for men and women are 8.7% and 6.7%, respectively in their lifetime. The disease often occurs during 12-18 years old and has been found very rarely during infancy. Like adults, children's appendicitis is treated through appendectomy [1].

The incidence of appendicitis in infants is very low [2]. Perforated appendicitis in children is accompanied with a range of symptoms which are led to the generalized purulent peritonitis. Thus, the influence of the surgical intervention and antibiotic therapy period are varied depending on perforated appendicitis appearance and in fact the extent of the inflammatory process within peritoneum varies [3].

Laparotomy with median incision, appendectomy and cleansing abdominal cavity are what is commonly done to treat generalized appendicular peritonitis; meanwhile,

abdominal drain placement and keeping wounds open for primary delayed healing are employed by many surgeons [4, 5]. Appendectomy's importance cut in terms of removing the infection source is completely clear. It has been once mentioned that any further treatment to appendectomy and debridement for children appendicular peritonitis is unnecessary [6]. The most important question of our question was that whether laparotomy with median incision and cleansing abdominal cavity is necessary? In this study we have tried to analyze the results of appendectomy without cleaning peritoneum in children with the generalized appendicular peritonitis.

Materials and Methods

It is an applied cohort study which had been executed on patients referred to emergency department of Dr. Sheikh Hospital in order to analyze the results gained from

appendectomy without cleansing peritoneum of children suffering from generalized appendicular peritonitis. Any underlying or associated disease and negative result of appendicular peritonitis diagnosis test during treatment course made volunteers unqualified to continue the process. With regard to the former information and similar studies, the sample size was set to 30 people (confidence level: 95%).

Sampling was carried out improbably and easily. Field method was used to collect data in which a number of predesigned forms were filled. When parents felt completely justified and signed written consents, a total of thirty children suffering from generalized appendicular peritonitis who have referred to the emergency department of Dr. Sheikh Hospital were selected improbably and easily. Patients were admitted and then the fluid therapy was triggered for restoration. The intravenous antibiotic therapy included 50 mg/kg per day ceftriaxone and 30 mg/kg metronidazole per day for all patients. All patients were prescribed with 0.5 mg/kg petidine. The patients were moved to operation room at the first opportunity. All patients underwent general anesthesia after taking 10 ml/kg normal saline. All patients were operated by a single surgeon.

After fulfilling surgical preparations and keeping the sterile condition, a transverse incision was made in the Right lower quadrant of the abdomen around Mcburney point. Then abdominal internal oblique muscles and abdominal transverse muscles were separated without any further incision. After that the parietal peritoneum is incised in order to open the peritoneum. When the appendix was found a tie was used for ligation of the base of it. Then appendectomy was started from the base of appendix and the appendix stump was liagted again. The free fluid within the abdomen as well as pus and debris around the place where the appendix is located (right fossa iliac) were extracted through the same incision using wet gas. Then, abdominal wall around peritoneal layers, muscles and fascia was repaired. All wounds were cleaned using saline, hypodermis was repaired and skin itself was repaired subcuticularly. When the surgery was finished, the appendix sample was sent to the lab for pathological examinations. After patients had regained consciousness, they were moved to the surgical ward and were treated with pre-operative intravenous antibiotic therapy and sedatives.

When the number of leukocytes reached normal condition and the patient experienced a feverless condition at least for 24 hours, the intravenous antibiotics were stopped and oral antibiotics, including 8 mg/kg/day cefixim and metronidazole, were started. Since the second day, the patients were allowed to start a liquid diet. Another abdominal sonography operation was tried with the aim of analyzing any formation of new abscess within the abdomen cavity. Drainage through skin should be necessary for the patient in the case of finding any type of abscess there; the drainage is conducted according to sonographic hints. After surgery, the patient was being checked two times a day in terms of vital signs, abdominal signs and symptoms. Their bandage was

replaced every day and his/her wound was examined to control viral assembly or inflammatory symptoms. In the case of observing wound infection, while the suture is fixing in its original place, where the viral assembly has been found, the incision is opened using a hemostat in order to exert drainage procedure and then the incision will be cleaned three times a day and its bandage will be renewed. If the patient becomes able to adapt the liquid diet and to reach the normal bowl movements, he/she will be discharged from hospital.

The oral antibiotics were continued until 14 days after operation. The parents of patients were instructed to the emergency department of Dr. Sheikh Hospital in the case of observing fever, or any type of abdominal symptoms such as obstruction, pain, nausea dilatation; they have been also offered to refer a clinic for 6 weeks in order to fulfill weekly visits.

All vital signs were being controlled and recorded and patient's abdomen was examined during the weekly visits. During the study, retentive for the early obstruction; percutaneous abscess drainage procedure for abdominal or pelvic abscesses and laparotomy for the early obstructions caused after surgery, for patients who had not been treated with the retentive or who suffering from undrainable abscesses, were prescribed.

Data Analysis Method

SPSS-11.5 Software was used to analyze data. The frequency of the qualitative variables including gender, complications, treatment success rate and need to relaparotomy, the mean value, dispersion indices for quantitative variables including age, and various tests such as ² and *t*-test for secondary targets such as determining age and gender distribution of patients and determining complications caused by the questioned method of the study and finally determining recovery rate for age and gender considerations separately

Results

A total of thirty patients with the generalized appendicular peritonitis were included in this study. All patients underwent pre-operative ultrasound sonography by which presence of free fluid in abdominal and pelvic cavities was approved. All patients showed the free fluid in their abdominal cavity during operation; examination of appendix verified perforation and gangrene which it had been confirmed by the histological examination of the appendix. Out of the 30 patients of the study a number of 18 (60%) and 12 (40%) patients were male and female, respectively. The age range of the subjects was 5 to 11 years, with a mean of 7.1 years, standard deviation of 1.56 and the coefficient of variation (CV) stood at 22 percent. Five (16.7%) patients got the wound infection that had been treated in two days through wound drainage, cleaning and daily bandage for three times a day while the suture was fixed there. All five cases infected with the disorder when they have been admitted for undergoing appendectomy and they were treated.

Three (10%) patients got abscess in their pelvis. All three cases were diagnosed very early through

sonography in the third day after surgery (without clinical evident or other tests). They underwent subcutaneous drainage which healed their disorder and any extra practice like percutaneous abscess drainage procedure became unnecessary. For all three cases, no secretion was reported in drains during three days of treatment. All three cases infected with the disorder when they have been admitted for undergoing appendectomy and they were treated.

No early obstruction after surgery was seen in patients up to six weeks after surgery. Generally, eight disorders were observed in five patients out of 30 patients, in other words, three patients developed wound and pelvic abscess, thus 16.7% patients got such disorders.

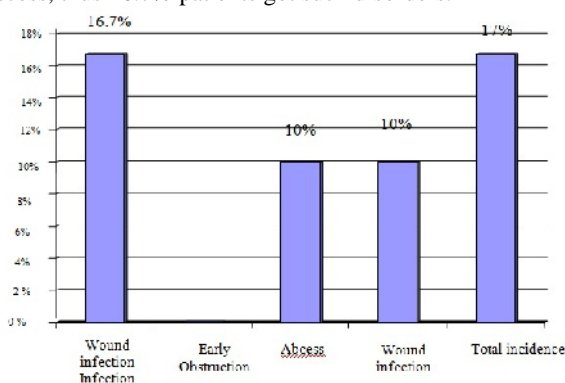


Figure 1. Incidence rate of complications in patients

The generalized appendicular peritonitis was controlled in all thirty patients (100%) of the study through only a single appendectomy and antibiotic therapy, so any further treatment to control the generalized appendicular peritonitis became unnecessary. Clearly, regarding this result, the frequencies of recovery of age and gender groups of the studied patients all were identical (100%) rather different. None of the patients needed relaparotomy to control either peritonitis or any secondary complications.

Discussion

The age mean of our subjects was 7.03 years. None of patients needed relaparotomy (because of treatment failure or incidence of complications); also, no early obstruction was seen after operation and the peritonitis did not reported for children aged less than 5 years old. The ratio of all occurred complications to our population was 26.7%. The incidence rate of abscess formation in our patients was 10%.

Small bowel obstruction (SBO) is treated as a common complication caused by appendectomy which often occurs due to adhesion in patients with the perforated appendicitis; its incidence rate is about 1-2% [1]. No early obstruction after surgery was reported in our patients. The same rate has not certainly been proposed for the appendicular peritonitis in the surgical textbooks; while the incidence rate of the early obstruction after surgery in

patients with appendicitis has been reported 2% [2]. Various rates have been reported for the abscess formation incidence in different literature and it has not been specified for the generalized appendicular peritonitis. The suggested treatment for such abscesses is percutaneous abscess drainage procedure under sonography or CT-scan guidance. According to the surgical textbooks, appendicitis is common among school children (12-18 years) [3]. Regarding this study and patients who usually refer to Dr. Sheikh Hospital, it is natural that the patients were less than 12 years. The incidence of appendicitis in infants is very low, as no case was reported in this study. In our study, the gender-based distribution was 60% male to 40% female which can be justified regarding the 8.7-percent risk of getting appendicitis in boys to 6.7-percent risk in girls. The incidence rate of formation of the abdominal or pelvic abscess after surgery has been reported 8 percent which mainly has been seen in patients with the perforated appendicitis. The incidence rate of abscess formation in our patients has been reported up to 10 percent. Likewise, according to the surgical textbooks perforation rate in children aged less than 5 years have been mentioned 82%; however, we had not any case with peritonitis who was under 5 years.

There is not considerable information about complications of appendectomy in patients with appendicular peritonitis. Kuznetsov examined a total of 976 patients with the acute appendicitis, out of which 47 patients developed diffuse peritonitis as well. He reported the total rate of complications 10.1%. The ratio of all occurred complications to our population was 26.7% which included 16.7% of patients, though this general rate has not been specified for the appendicular peritonitis. Kuznetsov has reported incidence rate of complications including abscess, wounds, obstruction, intestinal fistula and bleeding as large as 10.1% [4], while Ternovoi has specified the general rate of complications of the purulent peritonitis caused by appendicitis as large as 42% [5].

There is a difference between rate of complications caused by appendectomy in children and adults. Wound infection rate in children with non-perorated appendicitis and in those with perforated appendicitis is 2.8% and 11%, respectively [6]. Wound infection rate in our patients was 16.7%. Wound infection rates in the surgical textbook are different; as a general rate has been reported for the perforated appendicitis [7]. The wound infection rate in children's perforated appendicitis has been reported as large as 11 percent [8].

Lanz et al. analyzed the medical results about the infectious peritonitis in 28 dogs which has been closed after surgery of the abdominal wall. Regarding the same mortality of this study in comparison with the other studies, and comparing the peritonitis etiology, abdominal cytopathology, counting leukocytes and serum biomarkers with the similar previous studies, it has been concluded that blocking the abdominal wall after successful control of the infection source along with cleaning the peritoneum during operation can be proper treatment for the infectious peritonitis [9]. Toki et al. divided randomly 53

children with the perforated appendicitis into two groups A (n=29) and B (n=24) [10]. Group A was treated with surgery, complete lavage of peritoneum and post-operative antibiotic therapy (lavage group); while group B was treated with surgery, abdominal drain placement and post-operative antibiotic therapy (drainage group). They concluded that the average duration of hospitalization, the average duration of fever, need to be fast after surgery in the lavage group were meaningfully less than those in the drainage group (but it was not meaningful). They concluded that lavage of peritoneum is preferred to abdominal drain placement for treating children with the perforated appendicitis.

In a retrospective study, Brugger et al. studied 241 diffuse peritonitis cases, treatments applied to cure them and their effects. They concluded that among various treatments, surgical control of the infection sources along with the lavage of peritoneum during operation are sufficient to treat most patients suffering from the diffuse peritonitis (including appendicular) [11].

In a meta-analysis, Qadan et al. examined 23 cases of cleaning peritoneum in the empirical peritonitis (rather appendicular), they have said that cleaning peritoneum with the antibiotic-filled solutions cause decrease mortality [12]. According to Stewart et al. who have retrospectively studied 189 children with the appendicular peritonitis, cleaning peritoneum using antibiotic-filled solutions decreases considerably its complications and intestinal adhesion rather cleaning with antiseptic solutions and/or even leaving it without any kind of cleaning. They also have reported very low degrees of the remaining infection within the peritoneum and need to relaparotomy has been very low [13].

Ohno indicated that cleaning peritoneum in order to get rid of the perforated appendicitis in children decreases its bacterial population [14]. Haecker et al. studied 20 children with the perforated appendicitis. They began to check the patients' peritoneal fluid each 12 hours once for five days since surgery day. They concluded that the endotoxin level of the peritoneal fluid for 90 percent of cases was very high as has paved the way for cultivation of bacteria; however, the patients were healed very well and their infectious symptoms were cleared completely. They also concluded that there is not any relationship between the microbial load or endotoxin level of the peritoneum cavity and the clinical course of disease. Thus, the hypothesis had been posed that controlling the infection source is more effective to suppress the systemic reactions and finally will lead to removing of the infectious agents through applying endogenic mechanisms. They also stated that except appendectomy and debridement no more treatment is necessary at least for the children appendicular peritonitis [15]. 100 % of patients of the study were cured and the generalized

peritonitis was controlled through the suggested treatment in this study.

Since the similar previous studies on this issue have followed a negative approach against cleaning peritoneum, they had not addressed the successful results of treatments without cleaning peritoneum. A study which has used a similar treatment (abdominal placement of drain) achieved a 98-percent success in treating patients with the generalized appendicular peritonitis [16]. None of our patients needed relaparotomy (because of failure of treatment or occurring complications). In another similar study, the need to the relaparotomy has been reported 0.83% [17]. In another similar study, the success rate of the treatment for all people with appendicitis (including appendicular peritonitis) has been reported 99% [18].

May be it can be said that the most important limit of the study was lack of similar study and even small number of studies exerted on the children's appendicular peritonitis which made difficult designing study and comparing its results. Regarding the ethical consideration perusing a comparative study with higher volume was impossible. Likewise, the unique nature of the study in Mashhad University of Medical Sciences and patients' ethical consideration made difficult pursuing the results up to end of the plan.

Given more simplicity and speed of the appendectomy without cleaning peritoneum, its shorter incision, the similar rate of complications reported by other similar studies, 100% success of the disease control and unnecessary nature of relaparotomy, it seems that this treatment can be a proper substitution for the conventional treatment of the broad incision and voluminous cleaning of the peritoneum. This study has paved the way for the next comparative studies with more subjects and for analyzing other variables such as post-operative pain, costs and duration of hospitalization.

Acknowledgements

This study is the thesis set down by Mr. Muhammad Mahdi Kamyar (Reg. No. 2383-t) student of the Mashhad University of Medical Sciences. Hereby, the authors appreciate the Research Deputy of the Mashhad University of Medical Sciences for its assistance in this study.

Authors' Contributions

All authors contributed in all stages of the study.

Conflict of Interest

No conflict.

Funding/Support

Deputy research of mashhad university of medical sciences.

References

1. Sawin RS. Appendix and Meckel's diverticulum. In: Oldham KT, Colombani PM, Foglia RP, editors. Principles and practice of pediatric surgery. 4thed. New York: Lippincott Williams & Wilkins; 2005: 1277.
2. St. Peter SD. Appendicitis. In: Holcomb III GW, Murphy JP. Ashcraft's pediatric surgery. 5th ed. Philadelphia: WB Saunders; 2010: 549-56.

3. Jaffe BM, Berger DH. The appendix. In: Brunicaardi FC, Andersen DK, Billiar TR, editors. Schwartz's principles of surgery. 9thed. New York: Mc Graw Hill; 2010: 1083-92.
4. Kuznetsov VI, Magerramov LG. [Complications of acute appendicitis in children] Russian [Abstract]. Vestn Khir Im II Grek 1975; 114(5): 113-6.
5. Ternovoi NK, Zazirnyi IM, Kosiakov AN, et al. [Analysis of complications of operation for appendicular peritonitis in children] Russian [Abstract]. Klin Khir 2000; (6): 36-8.
6. Whiteside OJ, Tytherleigh MG, Thrush S, et al. Intraoperative peritoneal lavage: Who does it and why? Ann R Coll Surg Engl 2005; 87(4): 255-8.
7. Michailova KN, Usunoff KG. Serosal membranes (pleura, pericardium, peritoneum). 1st ed. Berlin: Springer; 2006: 15-17.
8. Fischer Df, Matthews JB. Surgical peritonitis and other diseases of the peritoneum, mesentery, omentum and diaphragm. In: Feldman M, Friedman LS, Brandt LJ, editors. Sleisenger & Fordtran's gastrointestinal and liver disease. 8th ed. Philadelphia: Saunders Elsevier; 2006: 780-4.
9. Lanz OI, Ellison GW, Bellah JR, et al. Surgical treatment of septic peritonitis without abdominal drainage in 28 dogs. J Am Anim Hosp Assoc 2001; 37(1): 87-92.
10. Toki A, Ogura K, Horimi T, et al. Peritoneal lavage versus drainage for perforated appendicitis in children. Surg Today 1995; 25(3): 207-10.
11. Brugger LE, Seiler CA, Mittler M, et al. [New approaches to the surgical treatment of diffuse peritonitis] German [Abstract]. Zentralbl Chir 1999; 124(3): 181-6.
12. Qadan M, Dajani D, Dickinson A and Polk HC Jr. Meta-analysis of the effect of peritoneal lavage on survival in experimental peritonitis. Br J Surg 2010; 97(2): 151-9.
13. Stewart DJ, Matheson NA. Peritoneal lavage in appendicular peritonitis. Br J Surg 1978; 65(1): 54-6.
14. Ohno Y, Furui J, Kanematsu T. Treatment strategy when using intraoperative peritoneal lavage for perforated appendicitis in children: a preliminary report. Pediatr Surg Int 2004; 20(7): 534-7.
15. Haecker FM, Berger D, Schumacher U, et al. Peritonitis in childhood: Aspects of pathogenesis and therapy. Pediatr Surg Int 2000; 16(3): 182-8.
16. Konovalov AK, Derzhavin VM, Ivanova MN and Gordeeva IP. [Surgical treatment of appendicular peritonitis in children] Russian [Abstract]. Khirurgiia (Mosk) 1991; (8): 29-32.
17. Tander B, Pektas O, Bulut M. The utility of peritoneal drains in children with uncomplicated perforated appendicitis. Pediatr Surg Int 2003; 19(7): 548-50.
18. Samelson SL, Reyes HM. Management of perforated appendicitis in children revisited. Arch Surg 1987; 122(6): 691-6.

Please cite this article as: Fathi M, Joudi M, Hiraifar M, Kamyar M, Joudi M. Definition of success rate of appendectomy without peritoneal lavage in children with generalized appendicular peritonitis. Zahedan J Res Med Sci (ZJRMS) 2012; 14(6): 23-27.