

Joubert Syndrome

Ali Khajeh,*¹ Mohammad Elahifar²

Article history:

Received: 1 Mar 2011

Accepted: 10 Apr 2011

Available online: 13 Feb 2012

1. Department of Pediatrics, Zahedan University of Medical Sciences, Zahedan, Iran
2. Department of Radiology, Zahedan University of Medical Sciences, Zahedan, Iran

Joubert Syndrome is a rare genetic disease [1-3]. Our patient was an 8-month-old infant who was referred due to hypotonia, abnormal breathing and abnormal eye movements. A brief review of the patient's medical history clarified that he was the fourth child of second-degree relative parents. He was born normally through natural delivery. According to his family biography, he had a completely healthy brother and sister and a brother who had died of an unknown reason at six months of age. The prenatal care information of the patient did not show any particular point. General examination indicated an abnormal weight, height and head circumference. A sunken nasal bridge and a prominent forehead were reported, but eye examination did not show any abnormality. Examination of the developmental status

showed delayed cognitive and motor development. Eye movements were abnormal; the infant failed to focus on anything, to follow mobile things and his eye movements were quick and purposeless. The patient's respiratory pattern was abnormal too and periodic attacks of hyperventilation, hypoventilation and apnea were reported irregularly.

Laboratory tests were normal. A mild PDA was seen during echocardiography. Brain MRI showed the characteristic molar tooth sign (Fig. 1).

*Corresponding author: aliyavar2005@yahoo.com

Copyright © 2012 Zahedan University of Medical Sciences. All rights reserved.

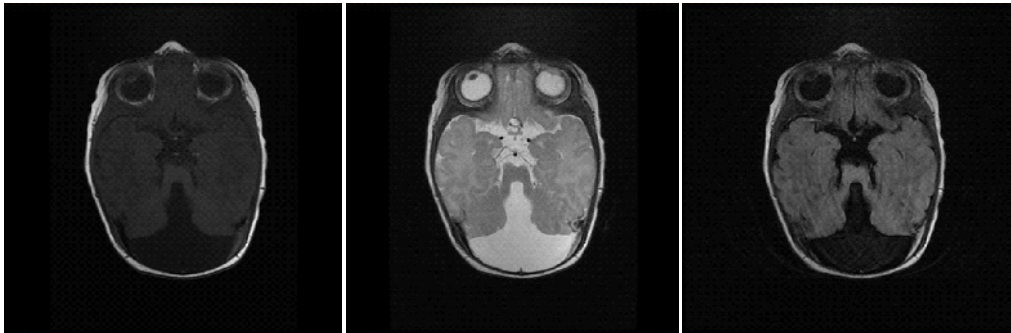


Figure 1. T1W, T2W and FLAIR images show aplasia of the vermis, thickening of the superior cerebellar peduncles and deepening of the interpeduncular sulcus (groove) "molar tooth appearance".

References

1. Zamponi N, Rossi B, Messori A, et al. Joubert syndrome with associated corpus callosum agenesis. *Eur J Paediatr Neurol* 2002; 6(1): 63-6.
2. Kumandas S, Akcakus M, Coskun A and Gumus H. Joubert syndrome: Review and report of seven new cases. *Eur J Neurol* 2004; 11(8): 505-10.
3. Quisling RG, Barkovich AJ, Maria BL. Magnetic resonance imaging features and classification of central nervous system malformations in Joubert syndrome. *J Child Neurol* 1999; 14(10): 628-35.

Please cite this article as: Khajeh A, Elahifar M. Joubert Syndrome . Zahedan J Res Med Sci (ZJRMS) 2012; 14(6): 47.