

The Effect of Fruit Pod Powder and Aquatic Extract of *Prosopis farcta* on Healing Cutaneous wounds in Diabetic Rat

Azadeh Ranjbar-Heidari,¹ Jina Khaiatzadeh, ^{*1} Naser Mahdavi-Shahri,² Maryam Tehranipoor³

1. Department of Developmental Zoology, science Faculty, Mashhad branch, Islamic Azad University, Mashhad, Iran
2. Department of Histology, Mashhad branch, Islamic Azad University, Mashhad, Iran
3. Department of Animal Physiology, Mashhad branch, Islamic Azad University, Mashhad, Iran

Article information	Abstract
<p>Article history: Received: 16 July 2011 Accepted: 29 Aug 2011 Available online: 18 Mar 2012</p> <p>Keywords: Prosopis Farcta Diabetes Lesion Healing Rat</p> <p>*Corresponding author at: Msc of developmental zoology, science Faculty, Mashhad branch, Islamic Azad University, Mashhad, Iran E-mail: j.khayatzadeh@mshdiau.ac.ir</p>	<p>Background: Wound healing in diabetes is one of the challenges in the medical science. Accordingly, new quick wound-healing compounds are welcomed. It is likely that <i>Prosopis farcta</i> - indigenous to southeastern Iran – accelerates regenerating process for its anti-inflammatory, antimicrobial and antidiabetic effects. This study is aimed at examining the local effect of the fruit dusk powder and root extract of <i>Prosopis farcta</i> on diabetic healing.</p> <p>Materials and Methods: Twenty-four male Wistar rats were randomly divided into 4 groups of intact, diabetic control, Experimental group 1(diabetic treated with fruit powder) and Experimental group 2 (diabetic treated with root extract). Diabetic groups were injected streptozotocin (STZ). Then, three holes (4 mm diameter) were made on both dorsal sides of the rats in all groups. Experimental groups were treated by fruit dusk powder and the plant root aquatic extract and the control groups were treated by normal saline. The area of the holes was continuously measured till they were completely closed.</p> <p>Results: In the treatment groups using fruit dusk powder and plant root aquatic extract, the hole area had significantly decreased ($p < 0.05$).</p> <p>Conclusion: It Seems that local administration of <i>Prosopis farcta</i> fruit dusk powder and root aquatic extract probably accelerates healing in diabetic rats. Regarding the antidiabetic, anti-inflammatory and healing effects of this plant, we are hopeful that <i>Prosopis farcta</i> plant finds an appropriate status in traditional medicine and pharmacology.</p> <p>Copyright © 2012 Zahedan University of Medical Sciences. All rights reserved.</p>

Introduction

Chronic lesions are serious problems in patients visiting skin specialists and plastic surgeons. They are resulted from a variety of factors including pressure ulcers, burn-induced lesions, diabetic lesions, lower extremity wounds and etc. One percent of adults and 3.6% of the population over 65 suffer from the lower limb wounds mainly induced by high vessel pressure and diabetes [1]. Diabetes is the common reason of wound healing delay or disruption. 15% of the *mellitus diabeics* patients suffer from the lower limb lesion resulted from lack of necessary cellular-molecular signals for regenerating process such as: cell proliferation due to granulation step and epithelization [1, 2]. A variety of cytokines and particularly growth factor provides important signals for lesion regenerating process, however these mechanisms act weakly in rehabilitating diabetic lesions [3]. Lesion healing is a complicated physiological process comprising several consequent steps: the first is homeostasis happening at the time of damage for an hour; the second is the inflammation beginning in a short time after homeostasis and that cells, capillaries, platelets and cytokines of the damaged tissue are activated; the third is the cell proliferation step and the

forth is reformation step where complete tissue maturity or scar is formed [4].

To treat diabetic lesions, plants are potential medicinal sources of antidiabetic or healing effects [5]. In many countries, plants and herbal products have been used in treating lesions and burning for ages. Modern and traditional medicine both suffer from the scarcity of resources regarding lesion regeneration [6]. Study of the effective factors on lesion healing is one of the advancement fields of the medicine. In countries like India and China where traditional medicine has a long history, there is significant information about using most of the unknown plants in treating lesions [6]. *Prosopis farcta* (Figur.1) widely used by the general for healing lesions in Iran and particularly in Sistan-Baluchistan zone. This plant is from *Leguminosae* and sub-family *Mimosoideae*, the indigenous of dry and semi-dry areas of America, Asia, and Africa [7,8].

Some medicinal properties of this plan are treating gastric ulcers, fetus abortion, dysentery, arthritis, larynx inflammation, heart pains and asthma [9]. Antidiabetic, anti-inflammatory effects of this plant are reported in some studies [10, 11].

Some of the compounds existing in *Prosopis* plant are: Toxin, Quercetin (Flavonoids), Tryptamine, Apigenin 5-hydroxytryptamine (Alkaloids), L-arabinose, Lectin [12, 13].

Cutaneous holes healing process in non-diabetic rat treated with *Prosopis farcta* fruit husk powder were reported significantly faster than the control group [14]. Also, *Prosopis farcta* plant root extract increased expansion rate of aorta [15]. As a result, since using natural compounds has lower side effects comparing to chemical substances and also regarding the antidiabetic, anti-inflammatory, and healing effects of different parts of the plant - the effects of the fruit husk powder and root aquatic extract of *Prosopis farcta* on the healing process of diabetic rats were examined in this study.



Figur. 1: *Prosopis farcta*

Materials and Methods

In this experimental study, 24 male Wistar rats (body weight 250-300g) from Razi Serology Center of Mashhad were examined. They were kept in 12:12-h light: dark cycle, temperature $22\pm 2^{\circ}\text{C}$ and free access to water and food. Upon identification of *Prosopis farcta* by the herbalist of Mashhad Islamic Azad University's Herbarium, fruit husk and root of the plant were separately powdered by electrical mill. Root powder (40g) was poured in the filter paper, transferred into Suckle device (H626) and extraction was carried out. Then, the animals were randomly divided into 4 groups (N=6): group1: intact control; group2: diabetic control; group3: experimental1 (diabetic treated by fruit powder); group4: experimental2 (diabetic treated by root aquatic extract).

Streptozotocin (STZ) powder, prepared from central pharmacy of Mashhad Red Crescent, was solved in Sodium Citrate buffer (0.1M with pH=4.2). Diabete was induced in diabetic control and experimental groups by using 55 mg/kg intraperitoneal injection of STZ [16-18]. 72h post injection and following 12-h fasting, bleeding was conducted from the tail vessel and blood sugar was assessed using glucometer. Rats with serum glucose level exceeding 250mg/dl were considered as diabetic samples and the others were excluded from the study.

In order to skin pouncing, the rats were anesthetized using ether and the dorsal hairs were shaved. After swapping the skin using butadiene solvent, three holes (4mm diameter, depth up to hypodermis area) were made on each side of the body. Since there were 36 samples in each group, total numbers of 144 locations were prepared to study. Then, the control groups and experiment groups were respectively treated locally by using fruit husk powder and plant root aquatic extract twice a day at certain times (along two days).

The powder dose was administered so as to completely cover the lesion. Since the fruit husk powder is used without being entered into a basic substance like Vaseline to treat the lesions in the traditional use in the sampling zone (Sistan-Baluchistan Province), the same method was also applied in this study.

Two days after punching the holes, the groups were continuously undergone microscopic measurement of the holes area on days 2, 4, 8, 10, and 15 (N=6) using transparent sheet and millimeter paper until the holes were closed [19]. Microscopic observations data were analyzed using SPSS Software by One-way ANOVA.

Results

Progress of skin regeneration process, demonstrated increases of hole area in all groups on the second day. However, on the next day's lesions edges grown together and the holes closed. The effect of fruit husk powder and root extract of *Prosopis farcta* indicated fast healing in the treatment group holes comparing to the diabetic control group.

The lesion area square (on days 8 and 10) in both experimental groups 1 and 2 (diabetic, treated with the powder and extract) and the intact control group was significantly ($p<0.05$) less than the diabetic control sample (Fig 2). No significant difference was observed in the area of the holes between two experimental groups on none of the days (Table 1and 2). On day 15, the hole of the diabetic control samples had not closed, despite the hole closing in the intact control group and experimental groups 1 and 2 were completed.

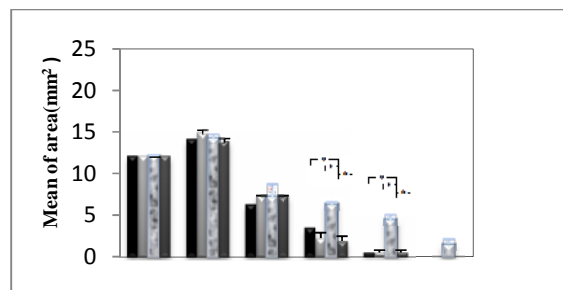


Figure 2. Area of the hole in the groups of study (from the first day of paunch, left columns, until hole closure, right columns) (black column: control, Low gray: diabetic control, 2 adjacent column: experimental 1,2)

Table 1. One-way ANOVA was used for comparison of holes area:

	Plural squares	Freedom degree	Mean Of square	F	p-Value
Between groups	2694.266	23	117.142	169.35	0.0001
In the groups	49.803	72	0.699		
Total	2780.122	95			

Table 2. Tukey analysis for significant difference between groups and days:

Groups\Days		0	2	4	8	10	15
Intact	Mean± SEM	12 g±0	14 gh±0.408	6.25ef±0.323	3.5cd±0.354	0.5ab±0.289	0a±0.25
Fruit powder	Mean± SEM	12 g±0	14.75 h±0.479	7.25 f±0.11	2.25 bcd±0.629	0.5 ab±0.289	0a±0
Diabetic control	Mean± SEM	12 g±0	14.25h±0.479	7.25 f±1.315	6.25ef±0.11	4.37 de±0.03	1.38 abc±0.554
Root extract	Mean± SEM	12 g±0	13.75 gh±0.479	7.25 f±0.10	1.88 abc±0.591	0.5 ab±0.289	0a±0

Mean with at least one common letter have no significant difference ($p < 0.05$)

Discussion

The local effect of *Prosopis farcta* root aquatic extract and fruit powder on healing diabetic rats' were examined in this study. Results showed that the lesion area increased on the first days that is probably based on the coincidence of lesion swelling phase. In addition to inflammation and swelling, skin and muscles stretch are also involved in increasing lesion area on these days [20]. Mean holes area is significantly decreased in the experimental groups comparing to the diabetic control group. These observations probably indicate the healing effect of *Prosopis farcta* plant aquatic extract and powder on diabetic rats' holes.

Several steps of lesion healing include: coagulation, inflammation, contraction and epithelization, granulation, fibroplasias and collagenesis [21]. Accordingly, the healing effect of *Prosopis farcta* plant aquatic extract and powder is probably through the advancement of some of these steps. Nakhaei Moghadam et al. had mixed *Prosopis farcta* fruit husk powder with animal butter and resulting pomade for treated non-diabetic holes in rat.

Their results showed increase of epithelization and consequently hole healing in treated groups [11]. In the same regard, present study results in the diabetic lesions healing through developing epidermis cell propagation. Since the decrease of vasculogenesis and cell proliferation in diabetes [22, 23], epithelization is likely the effective mechanism in diabetic regeneration. Gulalpa and Karcioğlu shown that Lectin and Toxin of *Prosopis farcta* plant have healing effect and destroy major parasites (leishmania) in infants [13].

A wide range of studies has been conducted regarding the effect of the substances on wound healing. Dweck et al demonstrated that plants with anti-inflammatory effect have high levels of flavonoids [24]. Azaizeh showed that Quercetin (flavonoid) has anti-inflammatory effect and results in inhibiting the production and secretion of histamine and other allergic and inflammatory mediators [25]. Kabir Soleimani et al. acknowledged that chronic inflammation and continuation of the lesion lead in healing delay, whereas the antimicrobial and anti-inflammatory effects can increase the healing speed [26]. Based on the existing compounds in the plant under

study (including toxin and flavonoids with antimicrobial and anti-inflammatory effects), it seems that the results of present study are correlated with the results of the other research and probably a part of the healing effects of *Prosopis farcta* has resulted from its inflammatory effect accelerating the wound healing in the diabetic groups of this study.

Danyaneshwar et al. studied the effect of the sensitive flower (*Mimosa pudica*) root on healing and concluded that methanolic extract of the root shows wound healing activity cause of phenolic substances existing in it [27]. Sachin et al examined the effect of root extract of *Ageratum conyzoides* on regeneration and considered the healing effect of a part of the plant root extract for presence of alkaloids whose antioxidant activities result in the progression of the healing steps [28].

There is amount of alkaloids (Tryptamine) in *Prosopis farcta* plant [12, 13]. So, results of the present study probably are according to the results of the above studies in terms of effective mechanisms in the lesion healing improvement. It must be noted that the healing results of this study are based on the holistic effect of the plant extract (the effect of its compounds all together on healing the lesion).

Since different compounds with various healing effects are reported for this plant; for exactly determination of effective healing substances existing in this plant, similar studies are suggested to be conducted separately after purifying each of the compounds existing in *Prosopis farcta*. Also, a comparison between the healing level of the plant and conventional medicines (including phenytoin) seems necessary in the future proposals. Then, more accurate information will be gained for pharmacological and medicinal application.

In sum and by comparing between the results of present study and results of the other scholars, it seems that *Prosopis farcta* plant is involved in the healing process of diabetic wounds through speeding up the inflammation, cell proliferation and also hypoglycemia; probably cause of containing alkaloids with antioxidant effects, flavonoids with anti-inflammatory effects, tannins with cell proliferation and vasculogenesis effect in healing and regeneration process of diabetic holes. Regarding the

healing effects of fruit powder and root extract of the plant on regeneration and healing the normal and diabetic tissues are reported through progression of cell proliferation [14], the plant role in treating diabetes [11] and since the outbreak of diabetes is increasing in present societies, detection of the effective methods in healing the lesion and reducing the organs' amputation rate will result in the improvement of the quality of life and

reduction of the treatment costs [29]. The application of *Prosopis farcta* plant and the similar healing plants in treating the lesion leads to the results improvement, lower costs and lower antibiotic use and resistance in the diabetic patients.

Acknowledgements

The article is adapted from Ms. Azadeh Ranjbar Heidari's thesis under the Code 11130517891004.

References

- McGrath JA. Wound healing. In: Breathnach SM. Textbook of dermatology. 7th ed. New York: Blackwell; 2004: 1-11, 250.
- Smits P, Kapma JA, Jacobs MC, et al. Endothelium-dependent vascular relaxation in patients with type I diabetes. *Diabetes* 1993; 42(1): 148-153.
- Weller R, Finnen M. The effects of topical treatment with acidified nitrite on wound healing in normal and diabetic mice. *Nitric Oxide* 2006; 15(4): 395-399.
- Strodtbeck F. Physiology of wound healing. *Clin Parc* 2001; 1(1): 43-52.
- Edwin J, Siddaheeswar B, Dharam C. [Diabetes and herbal Medicines] Persian. *Iran J Pharmacol Ther* 2008; 7(1): 97-106.
- Kumar B, Vijayakumar M, Govindarajan R and Pushpangadan P. Ethnopharmacological approaches to wound healing exploring medicinal plants of india. *J Ethnopharmacol* 2007; 114(2): 103-113.
- Saad B, Azaizeh H, Said O. Tradition and perspectives of arab herbal medicine: A review. *Evid Based Complement Alternat Med* 2005; 2(4): 475-479.
- Kramer SN. First pharmacopeia in mans recorded history. *Am J Pharm Sci Support Public Health* 1954; 126(3): 76-84.
- Al-Qura'n S. Taxonomical and pharmacological survey of therapeutic plants in Jordan. *J Nat Prod* 2008; 1(1): 10-26.
- Afifi F. Hypoglycemic effects of *Prosopis farcta*. *Int J Pharmacognosy* 1993. 31(1): 161-4.
- Al-Aboudi A, Afifi FU. Plants used for the treatment of diabetes in Jordan: A review of scientific evidence. *J Pharmacol Biol* 2011; 49(3): 221-239.
- Harzallah-Skhiri F, BenJannet H. Flavonoids diversification in organs of two *prosopis farcta* (banks & sol.) eig. (leguminosea, mimosoideae) populations occurring in the northeast and the southeast of Tunisia. *J Appl Sci Res* 2005; 1(2): 130-136.
- Gulalp B, Karcioğlu O. The first report of *Prosopis farcta* ingestion in children. *Int J Clin Practice* 2008; 62(5): 829-830.
- Nakhaee M, Mahdavi-Shahri N, Khayatzaadeh J, et al. [Effect of powder and hydroalcoholic extract of *Prosopis farcta* fruit sheath on epithelization of rat skin wound healing [Persian]. *J Biol Sci* 2009; 4(2): 7-15.
- Asadollahi K, Abassi N, Afshar N, et al. Investigation of the effects of *prosopis farcta* plant extract on Rat's aorta. *J Med Plants Res* 2009; 4(2): 142-147.
- Calvr D, Escobar G. Maternal non thyroidal illness and fetal thyroid hormone status, as studied in the streptococin – Induced diabetes mellitus Rat model. *J Endocrinol* 1997; 138(1): 1159-1169.
- Tehranipour M. Microanatomical study of the maternal diabetes on rats choroids plexus in embryonic, neonatal and adulthood stage. *J Biol Sci* 2008; 7(2): 1199-1204.
- Wei W, Ye Chen X, Yadong H. Acceleration of diabetic wound healing with chitosan-crosslinked collagen sponge containing recombinant human acide fibroblast growth factor in healing – impaired STZ diabetic rat. *J Life Sci* 2008; 82(1): 190-204.
- Manish PS, Chandra SS. Wound healing activity of *Terminalia Chebula* in experimentally induced diabetic rats. *Int J Pharm Tech Res* 2009; 1(4): 1267-1270.
- Rezaei A, Delazar A, Mohajeri D, et al. Effects of *Echinacea purpurea* herbal extract versus zinc oxide in rat skin wound healing model, histometric and histopathologic study. *J Pharm Sci* 2008; 74(2): 43-52.
- Forest RD. Development of wound therapy from Dark Ages to the present. *J R Soc Med* 1982; 75(4): 268-273.
- Goren I, Muller E, Pfeilschifter J, et al. Severely impaired insulin signaling in chronic wounds of diabetic ob/ob mice: A potential role of tumor necrosis factor-alpha. *Am J Pathol* 2006; 168(1): 765-777.
- Khaksar S, Kesmati M, Rezaie A, et al. [Topical estrogen accelerates wound healing in diabetic rats] Persian. *Iran J Endocrinol Metabol* 2010; 12(5): 544-551.
- Dweck A, Dweck D, Road M, et al. Herbal medicine for skin. *Personal Care Magazine* 2002; 3(2):19-21.
- Azaizeh H, Ljubuncic P, Portanya I, et al. Fertilization-induced changes in growth parameters and antioxidant activity of medicinal plants used in traditional Arab medicine. *Evid Based Complement Alternat Med* 2005; 2(4): 549-556.
- Kabirsoleimani M, Hoseini A, Khoshbaten A. Effect of fardmole on epithelization of burn wound in rat. *Yakhte* 1999; 1(3): 1-37.
- Dnyaneshwar D, Rahul Y, Mandar B, et al. Evaluation of wound healing activity of root of *Mimosa pudica*. *J Ethnopharmacol* 2009; 124(2): 311-315.
- Sachin J, Neetesh J, Tiwari A, et al. Simple Evaluation of wound healing activity of polyherbal formulation of roots of *ageratum conyzoides* linn. *Asian J Res Chem* 2009; 2(2): 12-22.
- Ollendorf AD, Kotsanos JG, Wishner WJ, et al. Potential economic benefits of lower-extremity amputation

prevention strategies in diabetes. Diabetes care 1998;

21(8): 1240-1245.

Please cite this article as: Ranjbar-Heidari A, Khaiatzadeh J, Mahdavi- Shahri N, Tehranipoor M. The effect of fruit pod powder and aquatic extract of prosopis farcta on healing cutaneous pores in diabetic Rat . Zahedan J Res Med Sci (ZJRMS) 2012; 14(5): 16-20.