



# Diagnostic Accuracy of Diffusion-Weighted MRI and Non-contrast CT in Hyperacute Ischemic Stroke

Basem Bahakeem<sup>1</sup>, Mohammad Khalil<sup>2</sup>, Alaa Alkhotani <sup>1</sup>, Amal Alkhotani<sup>1</sup>, Taghreed Alsinani<sup>3</sup>, Rakan Bokhari<sup>2</sup>, Humaira Waseem<sup>4</sup>, Amber Hassan<sup>5</sup>, Maher Kurdi <sup>2</sup>, \*

<sup>1</sup> Umm Al-Qura University, Mecca, Saudi Arabia

<sup>2</sup> King Abdulaziz University, Jeddah, Saudi Arabia

<sup>3</sup> King Fahad General Hospital, Jeddah, Saudi Arabia

<sup>4</sup> INTI International University, Malaysia

<sup>5</sup> Istituto Neurologico, Nazionale a Carattere Scientifico, Pavia, Italy

\*Corresponding Author: King Abdulaziz University, Rabigh, Saudi Arabia. Email: [ahkurdi@kau.edu.sa](mailto:ahkurdi@kau.edu.sa)

Received: 18 December, 2025; Revised: 22 January, 2026; Accepted: 27 January, 2026

## Abstract

**Background:** Prompt detection of acute ischemic stroke is essential for effective treatment and improved clinical outcomes. Diffusion-weighted imaging (DWI) and non-contrast computed tomography (NCCT) are commonly used imaging tools; however, their relative diagnostic accuracy within the hyperacute phase ( $\leq 6$  hours) requires further clarification.

**Objectives:** This study aimed to evaluate the diagnostic accuracy of NCCT compared with DWI magnetic resonance imaging (MRI) as the reference standard in patients presenting within 6 hours of symptom onset.

**Methods:** This prospective diagnostic accuracy study included 84 consecutive eligible cases presenting with symptoms suggestive of acute ischemic stroke within 6 hours of onset. All patients underwent NCCT followed by DWI MRI. The DWI MRI was predefined as the sole reference standard. Neuroimaging was evaluated by an independent radiologist blinded to clinical data and to the findings of the alternate imaging modality. Diagnostic performance of NCCT was calculated using sensitivity, specificity, positive predictive value (PPV), negative predictive value (NPV), overall accuracy, and 95% confidence intervals (CIs).

**Results:** Among the 84 patients, DWI identified 53 patients as positive for acute ischemic stroke. NCCT correctly identified 45 of these 53 DWI-positive cases, yielding a sensitivity of 84.9% (95% CI: 72.4% - 92.1%). It also correctly identified 24 of 31 DWI-negative cases, resulting in a specificity of 77.4% (95% CI: 59.8% - 89.4%). There were 8 false-negative cases (15.1%) and 7 false-positive cases (22.6%). Overall diagnostic accuracy of NCCT was 82.1% (69/84).

**Conclusions:** Diffusion-weighted imaging demonstrated higher sensitivity than NCCT for detecting hyperacute ischemic stroke. While NCCT remains essential for rapid exclusion of intracranial hemorrhage, DWI may provide complementary diagnostic value when available. These findings should be interpreted cautiously and require confirmation in larger multicenter studies.

**Keywords:** Acute Ischemic Stroke, Diffusion-Weighted MRI, Non-contrast CT, Early Ischemic Changes, Diagnostic Accuracy

## 1. Background

Timely identification of acute cerebral ischemia has become critically important with the emergence of therapies that require rapid and accurate evaluation and intervention within hours of symptom onset (1). Thrombolysis, the most commonly used reperfusion therapy, carries a risk of hemorrhagic complications,

underscoring the importance of rapidly identifying appropriate candidates (2). During the European Cooperative Acute Stroke Study II (ECASS II), 17% of patients treated with thrombolysis were later determined not to have suffered a stroke. Subsequent studies have similarly reported a substantial rate of thrombolytic administration in patients with so-called “stroke mimics” (3). This highlights the inadequacy of

clinical assessment alone for diagnosing ischemic stroke or determining therapy contraindications. Thus, reliable imaging techniques must be employed to quickly and accurately identify the most appropriate treatment (4).

Stroke affects 700,000 Americans yearly, causing death and disability, which accounts for 4% of hospital admissions and 2% of emergency department visits (5). In-hospital mortality is 15%, while 30-day mortality ranges from 20% to 25%. In-hospital mortality reaches 15%, 30-day mortality 20 - 25%, with \$41 billion annual costs; over half develop permanent disabilities, many needing assistance. The brain depends on continuous nutrients without energy storage; normal cerebral blood flow is 50 - 60 mL/100 g/min, with 50% reduction halting synaptic transmission (6). However, decreased cerebral blood flow disrupts ionic gradients, leading to neuronal death. The ischemic penumbra (25 - 50% cerebral blood flow) remains viable for hours, while the core (< 25% cerebral blood flow) undergoes necrosis, requiring urgent reperfusion (7).

Thrombolysis as a therapeutic approach originated in the 1950s; however, early trials employing intravenous streptokinase were discontinued because of increased mortality and hemorrhagic complications (8). While later studies like ECASS II evaluated the efficacy of tissue plasminogen activator (tPA) administration beyond three hours post-symptom onset, they did not show improved outcomes (9). Intra-arterial recombinant pro-urokinase (r-pro-UK) improved outcomes but increased early hemorrhage (10, 11). Currently, intravenous tPA remains the standard therapy for acute ischemic stroke within 3 - 6 hours of symptom onset, provided there is no intracranial hemorrhage (ICH) or extensive ischemic damage (12).

In the assessment of acute stroke, non-contrast computed tomography (NCCT) is the most frequently used imaging modality (13). It helps identify infarcts and ICH. Non-contrast computed tomography is advantageous for its widespread availability, cost-effectiveness, and ability to detect ICH (14). Initial ischemic changes on NCCT involve parenchymal hypodensity and cerebral edema, indicative of increased intra- and extracellular water. However, these signs may be absent or subtle in early ischemia, often requiring expert interpretation (15). Studies estimate NCCT sensitivity at approximately 50%, with inter-reader reliability showing kappa values between 0.51 and 0.72 (16). While NCCT remains a cornerstone of initial stroke assessment, its sensitivity may be insufficient for the growing demand for fast and reliable ischemia detection (17, 18).

By assessing the Brownian motion of water protons within tissue, magnetic resonance diffusion-weighted imaging (DWI MRI) provides greater accuracy in stroke imaging (19, 20). During ischemia, decreased ATP levels impair the sodium-potassium pump, causing water to move into the intracellular space. This limited motion reduces signal loss on DWI, causing lesions to appear bright (21). The DWI offers a 20-fold higher contrast-to-noise ratio, enhancing the distinction between ischemic and normal tissue compared to NCCT. Consequently, DWI sensitivity for early stroke detection surpasses that of NCCT, as supported by comparative studies within six hours of stroke onset (22).

## 2. Objectives

In our study, we aim to investigate the sensitivity and specificity of NCCT in the diagnosis of ischemic stroke, using DWI MRI as the gold standard method. This would specifically focus on patients presenting within the hyperacute window ( $\leq 6$  hours), a clinically critical decision-making period.

## 3. Methods

This prospective diagnostic accuracy study has been approved by an ethical committee to use the data for research. A convenient sampling technique was employed to enroll 84 cases during the study period, maintaining a 95% confidence interval and 8% absolute precision. This study was designed as a prospective diagnostic accuracy study in accordance with STARD reporting principles, with DWI MRI serving as the sole reference standard. The study included patients aged 30 to 65 years who presented with acute ischemic stroke within 6 hours of symptom onset, had a National Institutes of Health Stroke Scale (NIHSS) score of  $\geq 3$ , and underwent imaging within  $\leq 90$  minutes between modalities. Exclusion criteria were a history of myocardial infarction (MI), liver dysfunction (alanine aminotransferase [ALT]  $> 40$  IU/L, aspartate aminotransferase [AST]  $> 40$  IU/L), renal insufficiency (serum creatinine  $> 1.2$  mg/dL), rheumatic diseases, urinary tract infection (UTI), positive urine dipstick findings for hemoglobin, glucose, leukocytes, or nitrites, use of lipid-lowering therapy, or prior thrombolytic therapy. Patients with ICH, other intracranial pathologies (e.g., tumors or infections), or contraindications to imaging were also excluded. All enrolled patients underwent both NCCT and DWI MRI; no cases were excluded after imaging acquisition.

### 3.1. Imaging Protocol

### 3.1.1. Non-contrast Computed Tomography Imaging

The NCCT scans were performed with a slice thickness of 4 mm for the posterior fossa and 8 mm for the cerebrum, using either the Marconi PQ 2000 system (formerly Picker) or the Siemens Volume Zoom Scanner. MRI studies were conducted on a 1.5-T scanner with advanced gradient hardware (Edge, Marconi) for high-quality imaging. All MRI sequences were acquired on the same 1.5-T platform as described below.

### 3.1.2. Diffusion-Weighted Imaging

Diffusion-weighted imaging was performed for all patients presenting with focal neurological deficits using a 1.5-Tesla Signa Magnet system. Imaging was acquired with a single-shot echo-planar imaging (EPI) sequence using the following parameters: Repetition time of 6000 ms, echo time of 118 ms, field of view of 40 × 20 cm, acquisition matrix of 256 × 128, slice thickness of 6 mm with a 1-mm interslice gap, gradient strength of 14 mT/m, b-values of 4 and 1221 s/mm<sup>2</sup> applied in six diffusion directions, and three signal averages. The total acquisition time was 126 seconds. Acute ischemic lesions were defined as areas demonstrating hyperintensity on DWI with corresponding hypointensity on apparent diffusion coefficient (ADC) maps. An independent radiologist (BB), blinded to clinical data, assessed the scans for ischemic changes, restricted diffusion (DWI/ADC signals), and additional findings such as hemorrhagic transformation or recovery, and without reviewing patients' diagnostic reports or the findings of the alternate imaging modality. This imaging protocol, integrating high-resolution computed tomography and advanced MRI, was designed for accurate and timely ischemic stroke diagnosis. Moreover, reference-standard classification was based on DWI/ADC criteria.

### 3.2. Statistical Analysis

All data were recorded using a predefined Performa. Patient demographics and clinical histories were documented. The data were analyzed using SPSS version 25.0. Quantitative variables were presented as mean ± standard deviation (SD), and qualitative variables were reported as frequency percentages. The diagnostic accuracy of NCCT scans was assessed against DWI MRI, which served as the gold standard for detecting acute ischemic stroke using sensitivity and specificity with predictive values and overall accuracy. Diagnostic performance measures were calculated using exact binomial methods to derive 95% confidence intervals.

## 4. Results

The study involved 84 patients, with a mean age of 48.58 ± 10.62 years. The majority of participants were male, representing 71.4% (60/84) of the sample, while females made up 28.6% (24/84). Regarding the site of ischemic stroke, the most frequently affected region was the middle cerebral artery (MCA), observed in 83.3% (70/84) of patients, followed by posterior cerebral artery (PCA), which was involved in 16.7% (14/84) of cases (Table 1). No other vascular territories were affected in this cohort.

**Table 1.** Patient Profile and History

Variables	Values
Age (mean ± SD)	48.58 ± 10.62
<b>Gender; No. (%)</b>	
Male	60 (71.4)
Female	24 (28.6)
<b>Site of ischemic stroke; No. (%)</b>	
Middle Cerebral Artery	70 (83.3)
Posterior Cerebral Artery	14 (16.7)

Abbreviation: SD, standard deviation.

The diagnostic accuracy of NCCT was evaluated using DWI MRI as the gold standard (Figures 1 - 3). Among the 84 patients, NCCT correctly identified 45 out of 53 positive cases, yielding a sensitivity of 84.9% (95% CI: 72.4% - 92.1%). It also correctly identified 24 out of 31 negative cases, resulting in a specificity of 77.4% (95% CI: 59.8% - 89.4%) (Table 2, Figure 4). False-negative NCCT cases primarily involved subtle cortical or small territorial infarcts identified only on DWI, whereas false-positive NCCT cases were mainly attributed to early parenchymal hypoattenuation or imaging artifact.

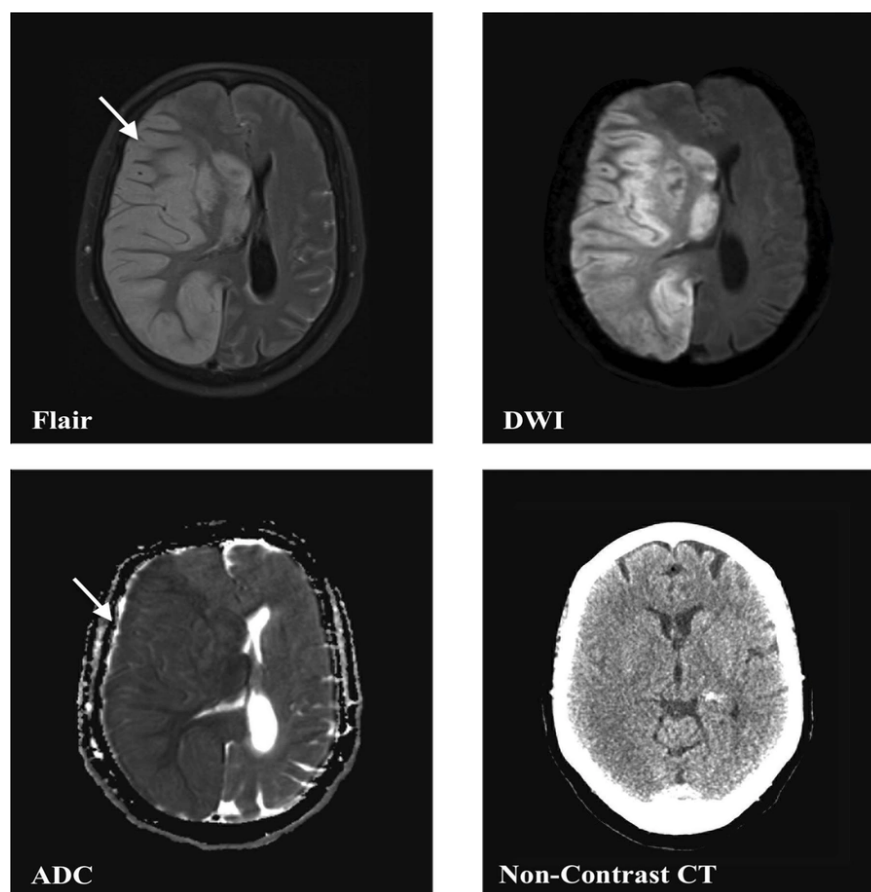
**Table 2.** Evaluating the Diagnostic Accuracy of Non-contrast Computed Tomography with Diffusion-Weighted Imaging MRI as the Gold Standard

NCCT Findings	DWI MRI Findings; No. (%)		Total; No. (%)
	Positive	Negative	
<b>Positive</b>	45 (84.9)	7 (22.6)	52 (61.9)
<b>Negative</b>	8 (15.1)	24 (77.4)	32 (38.1)
<b>Total</b>	53	31	84

Abbreviations: NCCT, non-contrast computed topography; DWI-MRI, diffusion weight magnetic resonance imaging.

## 5. Discussion

Current strategies for managing acute ischemic stroke play a key role in the diagnosis of patients so that they can benefit from reperfusion therapies. Given the time-sensitive nature of thrombolytic treatments and



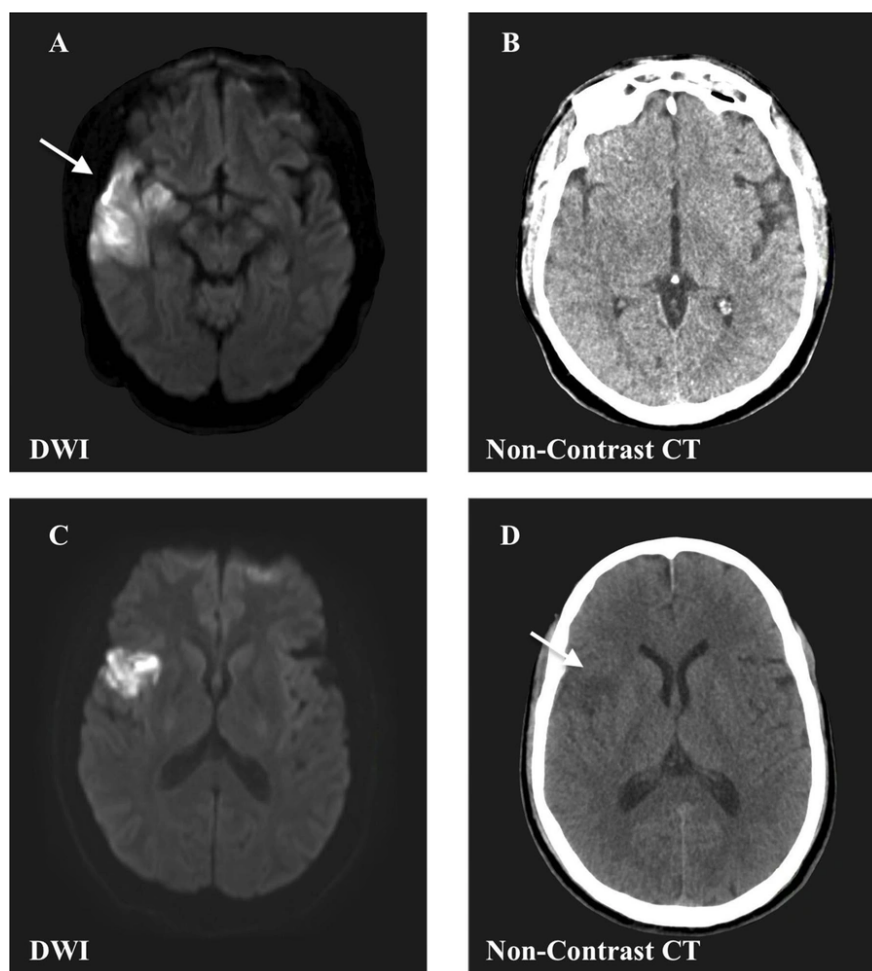
**Figure 1.** 43-year-old patient with large right middle cerebral artery ischemic infarction involving the basal ganglia, frontal, parietal, and insular lobes, with subsequent mass effect with subfalcine herniation. The infarcted area (arrows) is clearly visualized in four scan modalities (flair, diffusion-weighted imaging, apparent diffusion coefficient, and non-contrast computed tomography).

the limited early sensitivity of NCCT, it is common to administer thrombolytics even when NCCT results are unremarkable (23, 24). Studies indicate that up to 20% of patients initially diagnosed with stroke are later identified as having stroke mimics, many of whom receive unnecessary thrombolytic therapy. The higher sensitivity of DWI during the early stages of ischemia not only minimizes unnecessary thrombolytic administration but also supports the development of protocols requiring radiographic confirmation of ischemia before treatment (1).

Using DWI MRI as the reference standard, NCCT correctly identified 45 of 53 positive cases (sensitivity 84.9%) and 24 of 31 negative cases (specificity 77.4%). Overall, 69 of 84 cases were accurately classified, reflecting the diagnostic performance of NCCT compared with DWI MRI. These findings are consistent

with prior comparative work and support the interpretation of our observed diagnostic performance in the hyperacute window. The superior sensitivity is attributable to its ability to detect restricted water diffusion in ischemic tissues, a hallmark of acute ischemia, which manifests within minutes of stroke onset. This rapid detection is critical for initiating timely therapeutic interventions, such as thrombolysis or mechanical thrombectomy (24).

The NCCT's inability to accurately measure ischemic volume in the early stages of stroke often results in low inter-rater reliability, particularly among less experienced clinicians who frequently make therapeutic decisions (25). Conversely, DWI's superior ability to delineate infarct size, even early in the disease process, has the potential to enhance stroke volume assessment and reduce hemorrhagic complications, although this

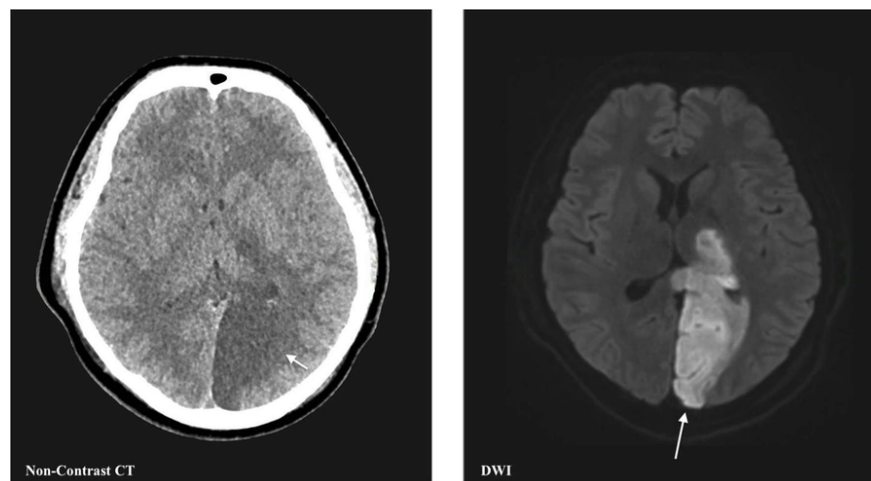


**Figure 2.** A and B, 65-year-old patient with an ischemic infarct in the inferior division of right middle cerebral artery territory involving the lateral temporal lobe and inferior parietal lobe (arrows); C and D, 61-year-old patient with an ischemic infarct affecting the opercular branches of right middle cerebral artery and involving frontal and orbital opercula. The infarcted area is clearly visualized in diffusion-weighted imaging and non-contrast computed tomography scan (arrows).

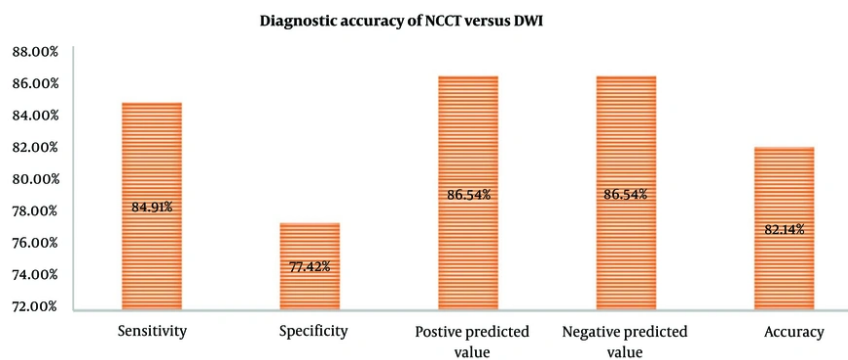
benefit remains theoretical. Additionally, DWI can differentiate the age of infarcts and reveal multiple ischemic areas in up to 17% of acute stroke cases, a finding that correlates with an elevated risk of hemorrhagic transformation when thrombolytic therapy is used (26).

Interestingly, specificity was relatively comparable between the two modalities, with DWI achieving 92.1% and NCCT achieving 90.3%. This finding indicates that while NCCT is less sensitive, it remains a reliable tool for ruling out non-ischemic causes, such as ICH. Thus, NCCT retains value in the initial triage of stroke patients, particularly in settings where DWI is not immediately available (27, 28).

A major strength of NCCT lies in its capacity to identify acute ICH, which constitutes an absolute contraindication to thrombolytic therapy. Although MRI was historically considered limited in detecting ICH, advances in imaging techniques—such as gradient-echo sequences, DWI, and perfusion-weighted imaging (PWI)—have markedly enhanced its sensitivity for acute hemorrhage (29). During ICH, hemoglobin transitions into the brain parenchyma, leading to red blood cell stagnation and reduced oxygenation, which alters the MRI signal. Studies have shown that MRI can detect ICH as early as 23 minutes after symptom onset, with findings visible on DWI and T2-weighted sequences within hours (30-32). Although additional studies are



**Figure 3.** 55-year-old patient with left posterior cerebral artery ischemic infarction. The infarcted area is clearly seen (arrows) in both scan modalities (diffusion-weighted imaging and non-contrast computed tomography).



**Figure 4.** The diagnostic accuracy of non-contrast computed tomography with diffusion-weighted imaging MRI as the gold standard.

needed to confirm its standalone efficacy, MRI's ability to exclude ICH and detect ischemic changes with DWI makes it a compelling alternative for stroke imaging (33).

Concerns about MRI have historically included acquisition time, limited availability, higher costs, and challenges in imaging uncooperative or claustrophobic patients. However, advancements in echo-planar imaging have significantly reduced scan times, enabling the entire brain to be imaged in under two minutes (34). Despite these improvements, the widespread adoption of MRI as the standard of care for acute stroke remains constrained by its cost and availability. A recent study

demonstrated that 24/7 MRI access is feasible and offers diagnostic and therapeutic advantages, with improved efficiency over time. As MRI technology becomes more accessible and affordable, its role in acute stroke management is likely to expand (35).

While DWI is invaluable for acute stroke imaging, other MRI modalities can also provide critical information within short acquisition times (36). Combined with DWI, PWI can distinguish between irreversibly damaged tissue and salvageable ischemic penumbra, potentially guiding decisions about the risks and benefits of reperfusion therapy beyond the traditional six-hour treatment window (37). Although

computed tomography perfusion offers similar sensitivity to DWI and PWI, its limited brain coverage restricts its utility compared to MRI, which provides comprehensive cerebral imaging. Advances in imaging protocols and interventional radiology techniques will likely extend the therapeutic window for acute ischemic stroke, enhancing patient outcomes.

Our findings have profound implications for clinical workflows in stroke management. While NCCT remains indispensable for its widespread availability, cost-effectiveness, and ability to exclude hemorrhage, the incorporation of DWI into routine protocols could significantly enhance diagnostic accuracy. Hospitals equipped with advanced imaging capabilities should prioritize DWI for patients presenting within the hyperacute phase, especially when thrombolytic therapy is being considered (38).

Despite its advantages, DWI is not without limitations. The reliance on high-field MRI scanners and the longer acquisition time compared to NCCT may pose logistical challenges in emergency settings. Additionally, contraindications to MRI, such as metallic implants or severe claustrophobia, may preclude its use in certain patients. Addressing these challenges will require continued investment in MRI accessibility and the development of faster imaging protocols. Future research should explore the integration of artificial intelligence (AI) to enhance the diagnostic performance of both modalities. AI-driven algorithms could improve the sensitivity and specificity of NCCT by identifying subtle early ischemic changes with greater accuracy.

### 5.1. Limitation

This study has several limitations. It was conducted at a single center with a modest sample size ( $n = 84$ ), which may limit generalizability. The sample size was based on consecutive patient enrollment during the study period rather than a formal diagnostic accuracy sample size calculation, which may limit statistical precision. Detailed NIHSS stratification and exact time-to-imaging intervals were not analyzed. External validation was not performed. Additionally, characterization of false-positive and false-negative cases was limited. These factors should be considered when interpreting the findings.

### 5.2. Conclusion

In this study, NCCT demonstrated a sensitivity of 84.9% and a specificity of 77.4% when compared with DWI MRI as the reference standard. These findings reinforce the higher sensitivity of DWI in detecting early

ischemic stroke, particularly within the hyperacute phase ( $\leq 6$  hours). Nevertheless, NCCT remains an essential first-line imaging modality due to its rapid availability and reliability in excluding ICH. Our results support the complementary role of DWI when accessible, rather than advocating replacement of NCCT in routine emergency settings. Given the single-center design and modest sample size, larger multicenter studies are necessary to further validate these findings before influencing clinical imaging guidelines.

### Footnotes

**AI Use Disclosure:** The authors declare that no generative AI tools were used in the creation of this article.

**Authors' Contribution:** Basem Bahakeem, conceptualization, analysis, and imaging; Mohammed Khalil, clinical correlation, data collection, and analysis; Alaa Alkhotani, analysis; Amal Alkhotani, data collection, and analysis; Taghreed Alsinani, data collection; Rakan Bokhari, clinical interpretation and analysis; Humaira Waseem, statistical analysis; Amber Hassan, supervision; and Maher Kurdi project administration, and analysis. All authors have critically reviewed and approved the final draft and are responsible for the content and similarity index of the manuscript.

**Conflict of Interests Statement:** There is no financial and non-financial conflict of interest to declare.

**Data Availability:** The datasets generated during and/or analyzed during the current study are available from the authors on reasonable request.

**Ethical Approval:** The study was conducted according to the guidelines of the Declaration of Helsinki and approved by an ethical committee from Lahore University and in collaboration with scientific researchers from King Abdulaziz University and Umm Al-Qura University in Saudi Arabia [Reference No. IRB-UOL-SPMRAD/2024-11-II].

**Funding/Support:** The authors declare no funding/support.

**Informed Consent:** All participants were consented for the publication. Informed consent was obtained from all patients prior to this study.

### References

1. Saceleanu VM, Toader C, Ples H, Covache-Busuioc R, Costin HP, Bratu B, et al. Integrative Approaches in Acute Ischemic Stroke: From Symptom Recognition to Future Innovations. *Biomedicines*. 2023;**11**(10). [PubMed ID: 37892991]. [PubMed Central ID: PMC10604797]. <https://doi.org/10.3390/biomedicines11102617>.
2. Mohamad T, Kanaan E, Ogieuhi IJ, Mannaparambil AS, Ray R, Al-Nazer LWM, et al. Thrombolysis vs Anticoagulation: Unveiling the Trade-Offs in Massive Pulmonary Embolism. *Cureus*. 2024;**16**(1). <https://doi.org/10.7759/cureus.52675>.
3. Keselman B, Cooray C, Vanhooren G, Bassi P, Consoli D, Nichelli P, et al. Intravenous thrombolysis in stroke mimics: results from the SITS International Stroke Thrombolysis Register. *Eur J Neurol*. 2019;**26**(8):1091-7. [PubMed ID: 30793434]. <https://doi.org/10.1111/ene.13944>.
4. Sivakumaran P, Gill D, Mahir G, Baheerathan A, Kar A. A Retrospective Cohort Study on the Use of Intravenous Thrombolysis in Stroke Mimics. *J Stroke Cerebrovasc Dis*. 2016;**25**(5):1057-61. [PubMed ID: 26856459]. <https://doi.org/10.1016/j.jstrokecerebrovasdis.2016.01.012>.
5. Behera DK, Rahut DB, Mishra S. Analyzing stroke burden and risk factors in India using data from the Global Burden of Disease Study. *Sci Rep*. 2024;**14**(1). [PubMed ID: 39349946]. [PubMed Central ID: PMC11443044]. <https://doi.org/10.1038/s41598-024-72551-4>.
6. Razavipour SF. *Metabolic and Blood Flow Properties of Functional Brain Networks Using Human Multimodal Neuroimaging [thesis]*. Montreal, Canada: Concordia University; 2022.
7. Berge E, Sandercock P. Specific treatment of acute ischemic stroke. In: Hankey GJ, Macleod M, Chen C, Caprio FZ, Mattle H, editors. *Warlow's Stroke: Practical Management, Fourth Edition*. West Sussex, England: John Wiley & Sons Ltd; 2019. p. 587-656. <https://doi.org/10.1002/9781118492390.ch13>.
8. Lewandowski C, Barsan W. Treatment of acute ischemic stroke. *Ann Emerg Med*. 2001;**37**(2):202-16. [PubMed ID: 11174240]. <https://doi.org/10.1067/mem.2001.111573>.
9. Balami JS, Chen R, Sutherland BA, Buchan AM. Thrombolytic Agents for Acute Ischaemic Stroke Treatment: The Past, Present and Future. *CNS Neurol Disord Drug Targets*. 2013;**12**(2):145-54. [PubMed ID: 23394531]. <https://doi.org/10.2174/18715273113129990057>.
10. Hameed A, Zafar H, Mylotte D, Sharif F. Recent Trends in Clot Retrieval Devices: A Review. *Cardiol Ther*. 2017;**6**(2):193-202. [PubMed ID: 28702878]. [PubMed Central ID: PMC5688975]. <https://doi.org/10.1007/s40119-017-0098-2>.
11. Prajapati C, Huded V, Mahajan N, Kulkarni A. Mechanical Thrombectomy. *Ann Indian Acad Neurol*. 2022;**25**(4):606-15. [PubMed ID: 36211146]. [PubMed Central ID: PMC9540950]. [https://doi.org/10.4103/aian.aian\\_29\\_22](https://doi.org/10.4103/aian.aian_29_22).
12. Alhadid K, Oliveira L, Etherton MR. Intravenous Thrombolytics in the Treatment of Acute Ischemic Stroke. *Curr Treat Options Cardiovasc Med*. 2023;**25**(1):15-28. [PubMed ID: 36618509]. [PubMed Central ID: PMC9807245]. <https://doi.org/10.1007/s11936-022-00973-2>.
13. Shafaat O, Sotoudeh H. *Stroke Imaging*. Treasure Island (FL): StatPearls Publishing; 2023.
14. Herpe G, Platon A, Poletti P, Lövblad KO, Machi P, Becker M, et al. Dual-Energy CT in Acute Stroke: Could Non-Contrast CT Be Replaced by Virtual Non-Contrast CT? A Feasibility Study. *J Clin Med*. 2024;**13**(13). [PubMed ID: 38999213]. [PubMed Central ID: PMC11242297]. <https://doi.org/10.3390/jcm13133647>.
15. Luo J, Zhao X, Xiao M, Wei L, Zhu Z, Li B, et al. Clearance rate of contrast extravasation after endovascular therapy is associated with functional outcome and mediated by cerebral edema. *J Cereb Blood Flow Metab*. 2024;**45**(1):66-76. [PubMed ID: 39161252]. [PubMed Central ID: PMC11572124]. <https://doi.org/10.1177/0271678x241275763>.
16. Song L, Qiu X, Zhang C, Zhou H, Guo W, Ye Y, et al. Combining Non-Contrast CT Signs With Onset-to-Imaging Time to Predict the Evolution of Intracerebral Hemorrhage. *Korean J Radiol*. 2024;**25**(2). [PubMed ID: 38238018]. [PubMed Central ID: PMC10831293]. <https://doi.org/10.3348/kjr.2023.0591>.
17. Baron J, Shen J, Li X, Li Y, Wu B. Comparative accuracy of CT perfusion in diagnosing acute ischemic stroke: A systematic review of 27 trials. *Plos One*. 2017;**12**(5). [PubMed ID: 28520753]. [PubMed Central ID: PMC5435168]. <https://doi.org/10.1371/journal.pone.0176622>.
18. Fan Y, Song Z, Zhang M. Emerging frontiers of artificial intelligence and machine learning in ischemic stroke: a comprehensive investigation of state-of-the-art methodologies, clinical applications, and unraveling challenges. *EPMA J*. 2023;**14**(4):645-61. [PubMed ID: 38094579]. [PubMed Central ID: PMC10713915]. <https://doi.org/10.1007/s13167-023-00343-3>.
19. D'Agata F, Coriasco M, De Luca A. Introduction to Diffusion Weighted MRI. In: Coriasco M, D'Agata F, De Luca A, Gennari L, editors. *A Practical Guide to Advanced Diffusion MRI*. Cham, Germany: Springer; 2024. p. 33-52. [https://doi.org/10.1007/978-3-031-70337-9\\_2](https://doi.org/10.1007/978-3-031-70337-9_2).
20. Holdsworth S, Bammer R. Magnetic Resonance Imaging Techniques: fMRI, DWI, and PWI. *Semin Neurol*. 2008;**28**(4):395-406. [PubMed ID: 18843569]. [PubMed Central ID: PMC3985850]. <https://doi.org/10.1055/s-0028-1083697>.
21. Ferrero JM, Gonzalez-Ascaso A, Matas JF. The mechanisms of potassium loss in acute myocardial ischemia: New insights from computational simulations. *Front Physiol*. 2023;**14**:1074160. [PubMed ID: 36923288]. [PubMed Central ID: PMC10009276]. <https://doi.org/10.3389/fphys.2023.1074160>.
22. Márquez J, Sananmuang T, Srinivasan A, Schaefer PW, Forghani R. Clinical Applications of Diffusion. In: Faro SH, Mohamed FB, editors. *Functional Neuroradiology*. Cham, Germany: Springer; 2023. p. 49-117. [https://doi.org/10.1007/978-3-031-10909-6\\_4](https://doi.org/10.1007/978-3-031-10909-6_4).
23. Wang Z, Sun B. A Short Review on Advances in Early Diagnosis and Treatment of Ischemic Stroke. *Galen Med J*. 2023;**12**. e2993. <https://doi.org/10.31661/gmj.v12i.2993>.
24. Magoufis G, Safouris A, Raphaeli G, Kargiotis O, Psychogios K, Krogias C, et al. Acute reperfusion therapies for acute ischemic stroke patients with unknown time of symptom onset or in extended time windows: an individualized approach. *Ther Adv Neurol Disord*. 2021;**14**. [PubMed ID: 34122624]. [PubMed Central ID: PMC8175833]. <https://doi.org/10.1177/17562864211021182>.
25. Chung KJ. *Improving the Reliability and Accessibility of CT Perfusion Imaging in Acute Ischemic Stroke [thesis]*. Canada: The University of Western Ontario; 2023.
26. Tong DC, Adami A, Moseley ME, Marks MP. Prediction of Hemorrhagic Transformation Following Acute Stroke. *Arch Neurol*. 2001;**58**(4). <https://doi.org/10.1001/archneur.58.4.587>.
27. Alkathiri AM. *Optimizing the Diagnostic Workflow for Acute Stroke Assessment: A Comparative Study of Diffusion Weighted-MRI & CT Imaging Protocols for Early Diagnosis in Acute Ischemic Stroke Patients in the Emergency Department [thesis]*. Riyadh, Saudi Arabia: Alfaisal University; 2024.
28. Newitt DC, Zhang Z, Gibbs JE, Partridge SC, Chenevert TL, Rosen MA, et al. Test-retest repeatability and reproducibility of ADC measures by breast DWI: Results from the ACRIN 6698 trial. *J Magn Reson Imaging*. 2018;**49**(6):1617-28. [PubMed ID: 30350329]. [PubMed Central ID: PMC6524146]. <https://doi.org/10.1002/jmri.26539>.
29. Rehmani R, Han A, Hassan J, Farkas J. Role of prothrombin complex concentrate (PCC) in Acute Intracerebral Hemorrhage with Positive CTA spot sign: An institutional experience at a regional and state designated stroke center. *Emerg Radiol*. 2016;**24**(3):241-7. [PubMed ID: 27915393]. <https://doi.org/10.1007/s10140-016-1464-4>.

30. Linfante I, Llinas RH, Caplan LR, Warach S. MRI Features of Intracerebral Hemorrhage Within 2 Hours From Symptom Onset. *Stroke*. 1999;**30**(11):2263-7. <https://doi.org/10.1161/01.Str.30.11.2263>.
31. Macellari F, Paciaroni M, Agnelli G, Caso V. Neuroimaging in Intracerebral Hemorrhage. *Stroke*. 2014;**45**(3):903-8. [PubMed ID: 24425128]. <https://doi.org/10.1161/strokeaha.113.003701>.
32. Dowlatshahi D, Brouwers H, Demchuk AM, Hill MD, Aviv RI, Ufholz L, et al. Predicting Intracerebral Hemorrhage Growth With the Spot Sign. *Stroke*. 2016;**47**(3):695-700. [PubMed ID: 26846857]. [PubMed Central ID: PMC4766058]. <https://doi.org/10.1161/strokeaha.115.012012>.
33. Yang J, Jing J, Chen S, Liu X, Tang Y, Pan C, et al. Changes in Cerebral Blood Flow and Diffusion-Weighted Imaging Lesions After Intracerebral Hemorrhage. *Transl Stroke Res*. 2022;**13**(5):686-706. [PubMed ID: 35305264]. <https://doi.org/10.1007/s12975-022-00998-6>.
34. Lawal O, Regelous P, Omiyi D. Supporting claustrophobic patients during magnetic resonance imaging examination- the radiographer perspective. *Radiography (Lond)*. 2024;**30**(1):80-6. [PubMed ID: 37871369]. <https://doi.org/10.1016/j.radi.2023.10.011>.
35. Hudson DM, Heales C, Vine SJ. Radiographer Perspectives on current occurrence and management of claustrophobia in MRI. *Radiography (Lond)*. 2022;**28**(1):154-61. [PubMed ID: 34657799]. <https://doi.org/10.1016/j.radi.2021.09.008>.
36. Dogariu OA, Gheorman V, Dogariu I, Berceanu MC, Albu CV, Gheonea IA. Correlation between DWI-ASPECTS Score, Ischemic Stroke Volume on DWI, Clinical Severity and Short-Term Prognosis: A Single-Center Study. *Brain Sci*. 2024;**14**(6). [PubMed ID: 38928577]. [PubMed Central ID: PMC11201519]. <https://doi.org/10.3390/brainsci14060577>.
37. Mansour M. Reperfusion Therapies in Acute Ischemic Stroke Beyond the Conventional Time Window: A Narrative Review. *Cureus*. 2023;**15**(9). e45864. <https://doi.org/10.7759/cureus.45864>.
38. Christiansen SD. *Ischemic Stroke Thrombus Characterization through Quantitative Magnetic Resonance Imaging [thesis]*. Canada: The University of Western Ontario; 2021.