

Neurological Manifestations as Presenting Feature of Osteopetrosis in Children; A Review of 11 Cases

Saeed Saeedinia¹, Mohammad Jaafari², Farideh Nejat^{3,*}, Naghmeh Pourmand¹, Mostafa El Khashab⁴

¹ Department of Neurosurgery, Tehran University of Medical Sciences, Tehran, Iran

² Department of neurosurgery, Iran University of Medical Sciences, Tehran, Iran

³ Department of Neurosurgery, Children's Hospital Medical Center, Tehran University of Medical Sciences, Tehran, Iran

⁴ Department of Neurosurgery, Hackensack University Medical Center, New Jersey, United States of America

*Corresponding author: Farideh Nejat, Children's Hospital Medical Center, Tehran University of Medical Sciences, Tehran, Iran. Tel.: +98-9121494064, Fax: +98-2166930024, E-mail: nejat@sina.tums.ac.ir.

ABSTRACT

Background: Osteopetrosis is a rare congenital disorder characterized by the malfunction of osteoclast cells resulting in increased bone density and adverse complications such as bone marrow insufficiency, bone fragility, and neurological symptoms subsequent to increased cortical thickness of the skull.

Objectives: We studied neurologic manifestation of the disease, the main complaints that resulted in the diagnosis, the management and outcome during the follow up period.

Patients and Methods: This study comprised of children having neurological symptoms as their initial presentation of osteopetrosis that were referred to Children Medical Center Hospital in Tehran from June 2001 to 2011.

Results: Intracranial hypertension was the first presentation of osteopetrosis in 11 of the children; 7 patients showed signs and symptoms of hydrocephalous, and 4 had pseudotumor cerebri. In addition, visual disturbance was also a common finding. All patients aged 2 or more (5 children) complained of headache, and 2 of the patients (18%) had facial palsy. During the follow-up (2.1 ± 1.9 years), 3 patients (27%) died due to bone marrow insufficiency and sepsis.

Conclusions: The diagnosis of osteopetrosis with the aid of neurological presentation is uncommon and neurological complications are usually found during the follow-ups. All of our patients presented with signs and symptoms of intracranial hypertension and the diagnosis of osteopetrosis was established. After a trail of investigations, this observation considers the importance of extensive evaluation of a child with a new onset hydrocephalus to prevent further serious complications.

Keywords: Hydrocephalus; Osteopetrosis; Pseudotumor Cerebri

Copyright © Tehran University of Medical Sciences.

►Article type: Research Article; Received: 03 Jan 2013; Revised: 08 Apr 2013; Accepted: 16 Apr 2013; Epub: 01 Apr 2014; Ppub: 20 Apr 2014

►Implication for health policy/practice/research/medical education:

To introduce the rare presentation of this disease to neurosurgeons, to emphasize the role of early diagnosis of disease .

►Please cite this paper as:

Saeedinia S, Jaafari M, Nejat F, Pourmand N, El Khashab M. Neurological Manifestations as Presenting Feature of Osteopetrosis in Children; A Review of 11 Cases. Arch Neuro Sci. 2014; 1(1): 21-5. DOI: 10.5812/archneurosci.10010

►Copyright © Tehran University of Medical Sciences.

This is an Open Access article distributed under the terms of the Creative Commons Attribution License (<http://creativecommons.org/licenses/by/3.0>), which permits unrestricted use, distribution, and reproduction in any medium, provided the original work is properly cited.

1. Background

Osteopetrosis (Marble bone disease) is a hereditary disorder in which the abnormal function of osteoclast cells leads to decreased bone absorption and increased skeletal bony mass formation (1-4). The overall incidence of osteopetrosis is not known but it is estimated to be one in 20,000 to 500,000 persons (5-8). In the simplest classification, osteopetrosis can be classified into three major clinical types: infantile osteopetrosis (early onset) is inherited in an autosomal recessive pattern having the worse clinical course, intermediate osteopetrosis having relatively severe symptoms and an adult onset (late onset), the mildest form of the disorder is inherited in an autosomal dominant pattern (4, 5).

Common primary symptoms of osteopetrosis, according to the patient's age are failure to thrive, osteomyelitis, short stature, multiple fractures, hepatosplenomegaly, and cytopenia due to bone marrow suppression (4). Neurological symptoms may be present in the infantile type but are rarely found in late childhood and adolescence

(4, 6). Here, we present 11 patients whose primary neurological symptoms led to the diagnosis of osteopetrosis.

2. Objectives

Children with osteopetrosis in whom neurologic symptoms and signs led to the diagnosis of the disease were studied.

3. Patients and Methods

Neurological manifestations presented as the initial signs/symptoms leading to the diagnosis of osteopetrosis are uncommon. From June 2001 to 2011, eleven children with neurological presentations were referred to the neurosurgery ward of Children Medical Center Hospital in Tehran and after thorough investigations; the diagnosis of osteopetrosis was established. Several variables such as age, sex, duration of symptoms, neurological symptoms, management and outcomes were collected and analyzed using SPSS version 16 (Table 1).

Table 1. Demographic Information, Signs, Symptoms, Management, Follow-up and Outcome of Patients With Osteopetrosis (n = 11)

	Age, y	Gender	Symptom Duration, y	Reason for Referral	Diagnostic Group	Management	Follow up, y	Outcome
1	13	F ^a	5	Headache, blindness, papilledema	HCP	LP shunt	2	Blind, stable
2	3	F	7	Blindness, atrophy, headache, facial palsy	HCP	VP shunt	4	Facial palsy, blind
3	8	F	5	Blindness, vomiting, enlarged head	HCP	VP shunt	1	Blindness, normal cognition, motor delay/ Referred for BMT
4	6	M	2	Enlarged head, bulging fontanelles, no visual contact	PC	Acetazolamide/ Lumbar puncture	5	OUTPATIENT Referred for BMT
5	1	F	5	Irritability	HCP	Acetazolamide	5	OUTPATIENT Referred for BMT
6	1	F	1	Sunset eyes, organomegaly, femur Fx	HCP	VP shunt	3	Death (Sepsis)
7	5	M	1	Vomiting, bulging fontanelles	HCP	VP shunt	1	Death (pancytopenia sepsis)
8	13	F	1	Vomiting, papilledema, decreased vision, headache	PC	LP shunt	3	Stable vision normal course
9	2	M	3	Headache, vomiting, blindness	PC	Medical therapy (Indoral, Acetazolamide repeated Lumbar puncture)	3	Blind, normal development, refractory pancytopenia, repeated transfusion
10	5	M	1	Headache, vomiting, severe bulging fontanelles	HCP	VP shunting	.3	Death (sepsis)
11	4	F	5	Headache, vomiting, progressive blindness	PC	VP shunting	6	Total blindness, facial palsy, normal IQ

^a Abbreviations: F; female, HCP; hydrocephalus, LP; lumboperitoneal, M; male, PC; pseudotumor cerebri, VP; ventriculoperitoneal, Y; year

4. Results

Six (55%) of 11 patients were female. The mean age of the patients at the time of presentation was 3.6 ± 4.8 years, ranging from 6 months to 13 years. All patients with raised intracranial pressure (RICP) were classified into two major groups based on these clinical presentations: 7 patients with hydrocephalus (66%) having the mean age of 2.8 ± 4.6 years, and 4 patients with pseudotumor cerebri (34%) with the mean age of 4.9 ± 5.6 years. However, the age difference between the two groups was not statistically significant ($P = 0.519$).

5. Discussion

Radiography and brain CT scan were the mainstay of diagnosis of osteopetrosis in all patients which revealed increased bone density generally (Figure 1). Skull base was involved in cranial CT scan which showed underpneumatized paranasal sinuses and mastoid air cells associated with narrowing of cranial nerve foramina and canals due to severe thick and dense bone. The serum levels of calcium, phosphorus and alkaline phosphatase, and urine calcium level were in normal range in all 11 patients, but parathyroid hormone level was increased in 3 patients. Visual disturbances, including blindness was found to be the most common neurological presentation within the both groups. Seven patients (66%) experienced visual disturbances in the first visit and 6 had total bilateral blindness. All patients older than 2 years (5 children) complained of headaches, and 2 patients (18%) developed acquired facial palsy within the course of the disease.

Surgical and medical interventions were considered for all cases due to RICP. Six patients (55%) underwent ventriculoperitoneal (VP) shunting, 2 (18%) were managed with lumboperitoneal (LP) shunting, and 3 (27%) received conservative treatments such as the administration of acetazolamide and repeated lumbar punctures. Three patients were referred for bone marrow transplantation (BMT) to control the underlying disease. After an average of 2.1 ± 1.9 years, 3 patients (27%) died due to bone marrow insufficiency and sepsis. Any modality used to control RICP ameliorated the symptoms (headache, vomiting, bulged fontanel), but the patients with visual disturbance and facial palsy showed no improvement.

Osteopetrosis is an extremely rare disorder characterized by dysfunction of osteoclasts which leads to an imbalance between bone formation and absorption responsible for bone remodeling. An increase in the density and thickness of cranial bones can lead to foramina stenosis at the base of cranium, and subsequent neurological deficits. However, the incidence of osteopetrosis is not exactly clear, (4, 9, 10). Based on the clinical features and the age of presentation, osteopetrosis is classified into three major forms, namely, infantile (early onset), intermediate, and adult (late onset) (1, 9, 11).

Infantile osteopetrosis is the most severe and malignant

form, and is inherited in an autosomal recessive pattern. This form of the disease is diagnosed early in life and can be life-threatening. Intermediate osteopetrosis is less symptomatic, and usually occurs in childhood. Adult osteopetrosis, usually, is not symptomatic before the age of 20, and is often diagnosed incidentally (1, 5). All of our cases, except two with intermediate osteopetrosis, had the infantile form. Infantile osteopetrosis presents only a few years after birth, thus, leads to failure to thrive, and psycho-mental retardation. The initial presentations of this form of osteopetrosis can appear as bone marrow insufficiency, sepsis and repeated skeletal fractures, but neurological symptoms are uncommon. Some neurological symptoms such as blindness, deafness, facial palsy, and trigeminal neuralgia caused by over thickness of the skull and foramina narrowing are, as well, defined complaints. Similarly, foramen jugular narrowing and venous drainage abnormalities can lead to intracranial hypertension throughout the course of the disease (9, 10). Visual disturbances are the most common cranial nerve dysfunction of osteopetrosis (12-15) caused by optic nerve compression leading to enlargement of the subarachnoid space around the optic nerve and papilledema (16). Peripheral facial palsy, deafness and trigeminal neuralgia have the same pathophysiology as optic nerve involvement, therefore, cannot be recovered or stabilized with procedures that reduce intracranial hypertension and visual disturbances. In the physical examination, bulging, tense or wide fontanelles in the patients along with an increased head circumference confirmed raised ICP. The cranial CT scans, chest X-rays and skeletal radiographs revealed increased bone mineral density and cortical thickness of the skull. In all patients, the symptoms associated with raised ICP improved with ventriculo-peritoneal/ lumbo-peritoneal shunt or appropriate medical therapy. However, visual or facial nerve disturbances did not change after the correction of raised ICP. The most common causes of death in patients with infantile osteopetrosis are bone marrow insufficiency and sepsis (4, 17). Death due to neurological problems, especially intracranial hypertension, is not common. Nevertheless, complications of shunt surgery in these patients are higher than the normal population (10).

Bone marrow transplantation, if performed at an early stage of the disease, can improve hematogenous disorders; however, this treatment does not have any effect on the neurological complications (18). Typically, neurological symptoms are usually found during the follow-ups of a patient that has been diagnosed with osteopetrosis. The diagnosis of osteopetrosis with neurological symptoms, as the only presenting feature is very uncommon. For all of our patients presented with signs and symptoms of intracranial hypertension, the diagnosis of osteopetrosis was established with radiographies and CT scans during further investigations. Patients meeting the criteria of pseudotumor cerebri had intracranial hypertension long before an exact diagnosis of the disease was established. They were older than the pa-

tients presenting with hydrocephalus, nonetheless, this difference was not statistically significant. Here we wanted to emphasize that any new case of hydrocephalus with unknown cause should be evaluated for the etiological factors. Brain MRI can reveal intracranial pathologies but CT scan and radiography can evaluate the bone density and thickness for suspicious cases of osteopetrosis.

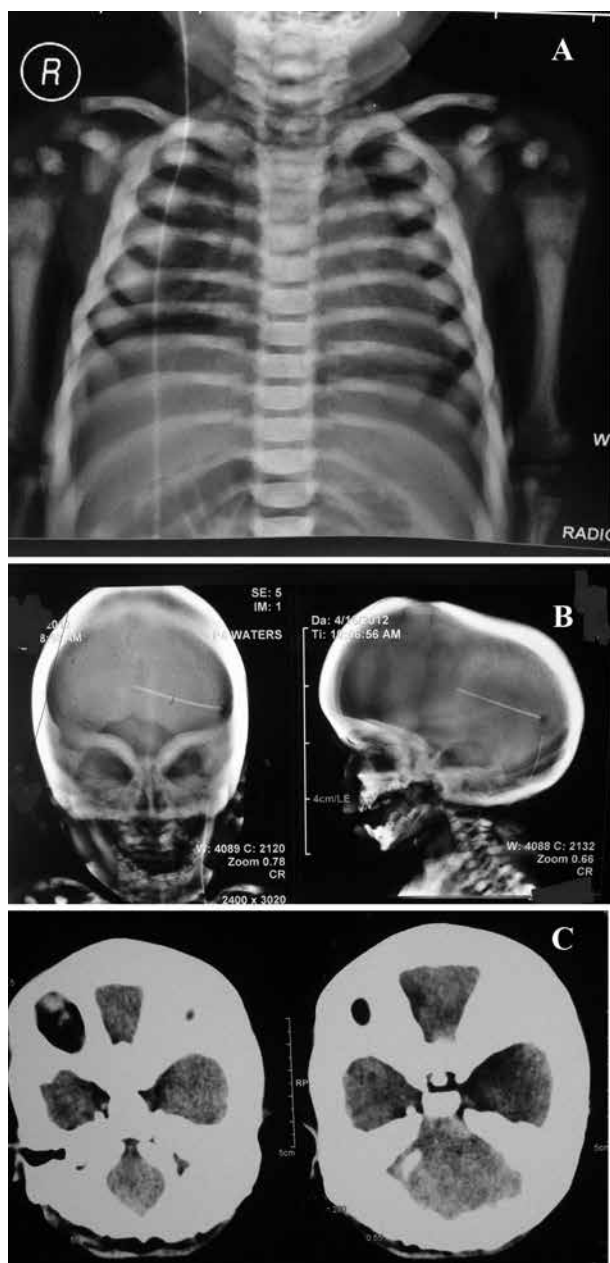


Figure 1. A, Chest X-ray of patient of osteopetrosis presented with hydrocephalus which managed with ventriculoperitoneal shunt. Note the increased density of bone in the ribs, limbs, and vertebral column; B: Skull X-ray of a patient presented with hydrocephalus needed shunt procedure shows severely thick and dens cranium, especially in the skull base region, and underpneumatized paranasal sinuses and mastoid air cells, C: Axial slices of brain CT scan confirm very dens skull base and narrow foramen magnum.

6. Conclusions

Children with osteopetrosis may refer to a neurosurgeon for neurological complications before the final diagnosis of osteopetrosis is made. In addition, osteopetrosis should be included within the differential diagnosis of children having symptoms of intracranial hypertension and cranial nerve dysfunctions.

Acknowledgements

None declared.

Authors' Contribution

Author contributions to the study and manuscript preparation include the following. Conception and design: Farideh Nejat. Acquisition of data: Farideh Nejat Saeed saeedinia, Mohammad Jaafari, Analysis and interpretation of data: Saeed saeedinia, Mohammad Jaafari, Drafting the article: all authors. Critically revising the article: all authors. Reviewed submitted version of manuscript: all authors. Approved the final version of the manuscript on behalf of all authors: Farideh Nejat Administrative/technical/material support: Farideh Nejat, Studysupervision: Farideh Nejat Mostafa EL Khashab.

Financial Disclosure

None declared.

Funding/Support

None declared.

References

1. Al-Tamimi YZ, Tyagi AK, Chumas PD, Crimmins DW. Patients with autosomal-recessive osteopetrosis presenting with hydrocephalus and hindbrain posterior fossa crowding. *J Neurosurg Pediatr.* 2008;1(1):103-6
2. Fasth A, Porras O. Human malignant osteopetrosis: pathophysiology, management and the role of bone marrow transplantation. *Pediatr Transplant.* 1999;3 (Suppl 1):102-7
3. Shapiro F, Key LL, Anast C. Variable osteoclast appearance in human infantile osteopetrosis. *Calcif Tissue Int.* 1988;43(2):67-76
4. Steward CG. Neurological aspects of osteopetrosis. *Neuropathol Appl Neurobiol.* 2003;29(2):87-97
5. Stark Z, Savarirayan R. Osteopetrosis. *Orphanet J Rare Dis.* 2009;4:5
6. Tolar J, Teitelbaum SL, Orchard PJ. Osteopetrosis. *N Engl J Med.* 2004;351(27):2839-49
7. Loria-Cortes R, Quesada-Calvo E, Cordero-Chaverri C. Osteopetrosis in children: a report of 26 cases. *J Pediatr.* 1977;91(1):43-7
8. Bollerslev J, Andersen PE, Jr. Radiological, biochemical and hereditary evidence of two types of autosomal dominant osteopetrosis. *Bone.* 1988;9(1):7-13
9. Dhamija B, Pettorini BL, Solanki G. Endoscopic third ventriculostomy for the treatment of osteopetrosis-related hydrocephalus: a case-based update. *Childs Nerv Syst.* 2011;27(11):1861-5
10. Grossman R, Feldman Z. Bone growth causing ventriculoperitoneal shunt malfunction in a patient with osteopetrosis. Case report. *J Neurosurg.* 2004;100(5 Suppl Pediatrics):530-1
11. el-Tawil T, Stoker DJ. Benign osteopetrosis: a review of 42 cases showing two different patterns. *Skeletal Radiol.* 1993;22(8):587-93

12. Aasved H. Osteopetrosis from the ophthalmological point of view. A report of two cases. *Acta Ophthalmol (Copenh)*. 1970;**48**(4):771-8
13. Beighton P, Hamersma H. Ophthalmological complications in the sclerosing bone dysplasias. *Ophthalmic Paediatr Genet*. 1985;**6**(3):129-34
14. Hoyt CS, Billson FA. Visual loss in osteopetrosis. *Am J Dis Child*. 1979;**133**(9):955-8
15. Siatkowski RM, Vilar NF, Sternau L, Coin CG. Blindness from bad bones. *Surv Ophthalmol*. 1999;**43**(6):487-90
16. Chandravanshi S, Rathore M, Vyas G. Ocular findings in osteopetrosis. *Int Med*. 2010;**49**(6):631-2
17. Wilson CJ, Vellodi A. Autosomal recessive osteopetrosis: diagnosis, management, and outcome. *Arch Dis Child*. 2000;**83**(5):449-52
18. Abinun M, Newson T, Rowe PW, Flood TJ, Cant AJ. Importance of neurological assessment before bone marrow transplantation for osteopetrosis. *Arch Dis Child*. 1999;**80**(3):273-4