



Diagnostic Challenges in Pediatric Basidiobolomycosis: A Case of Retroperitoneal Mass and Multisystem Complications

Mahmood Gorjizad ^{1,*}, Amirreza Taherkhani ¹, Maryam Kazemi Aghdam ², Fariba Shirvani ³, Javad Ghoroubi ⁴, Roxana Mansour Ghanaiee ^{3,**}

¹ Student Research Committee, Faculty of Medicine, Shahid Beheshti University of Medical Sciences, Tehran, Iran

² Associate Professor of Pathology, Pediatric Pathology Research Center, Research Institute for Children's Health, Shahid Beheshti University of Medical Sciences, Tehran, Iran

³ Pediatric Infections Research Center (PIRC), Research Institute for Children's Health (RICH), Shahid Beheshti University of Medical Sciences, Tehran, Iran

⁴ Associate Professor of General Surgery, Pediatric Surgery, and Pediatric Urology, Shahid Beheshti University of Medical Sciences, Tehran, Iran

*Corresponding Author: Student Research Committee, Faculty of Medicine, Shahid Beheshti University of Medical Sciences, Tehran, Iran. Email: mahmood.gorjizad99@gmail.com

**Corresponding Author: Pediatric Infections Research Center (PIRC), Research Institute for Children's Health (RICH), Shahid Beheshti University of Medical Sciences, Tehran, Iran. Email: roxanaghanaiee@gmail.com

Received: 13 January, 2025; Revised: 11 March, 2025; Accepted: 16 March, 2025

Abstract

Introduction: Gastrointestinal basidiobolomycosis (GIB) is a rare fungal infection caused by *Basidiobolus ranarum*, often misdiagnosed as inflammatory bowel disease (IBD) or malignancy. This misidentification frequently results in diagnostic delays and severe complications, including hydronephrosis and thrombosis.

Case Presentation: An 11-year-old boy presented with abdominal pain and significant weight loss, accompanied by a retroperitoneal mass causing bilateral hydronephrosis and venous thrombosis. Histopathological evaluation confirmed basidiobolomycosis. Due to adhesions, surgery was not feasible, but antifungal therapy with voriconazole and amphotericin B led to clinical improvement, with plans for extended follow-up.

Conclusions: The nonspecific symptoms of GIB and its similarity to other conditions highlight the critical role of histopathological examination in diagnosis. Faster diagnosis and antifungal therapy are crucial for preventing potential complications. This case underscores the necessity for a high index of suspicion for GIB in children presenting with unexplained abdominal symptoms and abdominal mass. Timely diagnosis and tailored management can significantly enhance outcomes.

Keywords: Basidiobolomycosis, Pediatric Fungal Infections, Retroperitoneal Mass, Hydronephrosis, Thrombosis, Antifungal Therapy

1. Introduction

Basidiobolomycosis is a rare fungal infection caused by the saprophytic fungus *Basidiobolus ranarum*, which naturally thrives in soil, decomposing plant matter, and the gastrointestinal tracts of reptiles, amphibians, and certain mammals (1, 2). Transmission typically occurs through contact with infected soil, organic material, gecko secretions, or via minor skin abrasions, particularly in warm and humid tropical or subtropical regions (3). Although subcutaneous basidiobolomycosis was previously the most reported type, there has been a concerning rise in gastrointestinal basidiobolomycosis

(GIB) in recent years (4, 5). This more severe and invasive condition, particularly seen in children, underscores the need for early diagnosis and treatment in regions where the fungus is endemic to prevent serious health complications (5, 6).

Gastrointestinal basidiobolomycosis poses considerable diagnostic challenges due to its nonspecific and overlapping symptoms, which can mimic conditions like inflammatory bowel disease (IBD), intestinal tuberculosis, appendicitis, or gastrointestinal malignancies (7, 8). Commonly reported symptoms include abdominal pain, fever, weight loss, and eosinophilia, often accompanied by

mass formation or signs of intestinal obstruction (9). Histopathological evaluation plays a pivotal role, often revealing features such as granulomatous inflammation, necrosis, and fungal hyphae surrounded by eosinophilic material, known as the Splendore-Hoeppli phenomenon (6, 10, 11). A delayed diagnosis can lead to severe complications like intestinal perforation or abscess formation, emphasizing the need for heightened clinical vigilance in endemic regions (2, 5, 12).

This case of an 11-year-old boy with GIB highlights the complex diagnostic and therapeutic challenges associated with this illness. Initially misdiagnosed with IBD and lymphoma, the true diagnosis of basidiobolomycosis was confirmed only after comprehensive diagnostic evaluations, including imaging and pathology. By detailing this case, we aim to stress the significance of early diagnosis and intervention in managing fungal infections, especially in endemic regions, to reduce complications and improve patient recovery.

2. Case Presentation

An 11-year-old boy presented with an 8-month history of abdominal pain, bloody diarrhea, significant weight loss, and generalized weakness. Ulcerative lesions were discovered during the initial diagnostic workup through colonoscopy, leading to an initial diagnosis of IBD. Treatment was initiated with prednisolone and anti-TNF therapy (Infliximab). However, his symptoms persisted, with ongoing fever, abdominal pain, and worsening anemia, despite this therapeutic approach. This necessitated further investigation into the etiology of his persistent problems.

At a secondary care center, imaging studies revealed a large retroperitoneal mass originating from the kidney, encircling the aorta and inferior vena cava (IVC), and causing bilateral hydronephrosis by compressing the ureters. A bone scan indicated areas of hyperactive uptake in the L3-L5 vertebrae and the right proximal radius, raising suspicion of metastatic involvement. Bone marrow biopsy excluded hematologic malignancies, and MRI with contrast further ruled out infiltrative tumors in these regions. A CT-guided biopsy of the kidney lesion demonstrated necrotizing inflammatory changes without evidence of malignancy. Histopathological analysis of the biopsy confirmed basidiobolomycosis, a rare fungal infection. Due to the inability to perform surgical intervention at this facility, the patient was referred to our hospital for definitive diagnosis and management.

2.1. Investigations

Initial laboratory and imaging investigations were conducted to assess the underlying cause of the patient's symptoms and complications.

2.2. Laboratory Findings

The laboratory findings demonstrated the following:

- Severe anemia (Hb: 5.8 g/dL), hypoalbuminemia (Alb: 3.2 g/dL), leukocytosis (WBC: $25.1 \times 10^9/L$), and elevated C-reactive protein (CRP: 91 mg/L).
- Despite significant hydronephrosis, renal function remained normal (creatinine: 0.7 mg/dL).

2.3. Histopathology

A biopsy from the kidney lesion performed at the secondary facility revealed necrotizing granulomas with broad fungal hyphae. Periodic acid-Schiff (PAS) and PAS-diastase (PAS-D) stains confirmed the presence of fungal components, leading to the diagnosis of basidiobolomycosis.

2.4. Imaging Studies

2.4.1. Ultrasonography

Bilateral moderate hydronephrosis with pelvic anteroposterior diameters of 17 mm (right) and 14 mm (left) due to compression of the ureters by the retroperitoneal mass.

2.4.2. Venous Doppler Ultrasound

Acute thrombosis in the left common femoral vein (CFV), superficial femoral vein (SFV), and iliac veins, with collateral venous dilation manifesting as variceal vessels throughout both legs, attributed to impaired venous return caused by the mass effect.

2.4.3. Spiral Abdominal CT Scan

A large retroperitoneal mass encasing the aorta, IVC, superior mesenteric artery (SMA), and ureters (Figure 1). Thrombosis extended into the IVC and right iliac vein, with moderate bilateral hydronephrosis.

2.4.4. MRI

Retroperitoneal mass measuring 38×31 mm encasing major vessels and ureters, with persistent hydronephrosis.

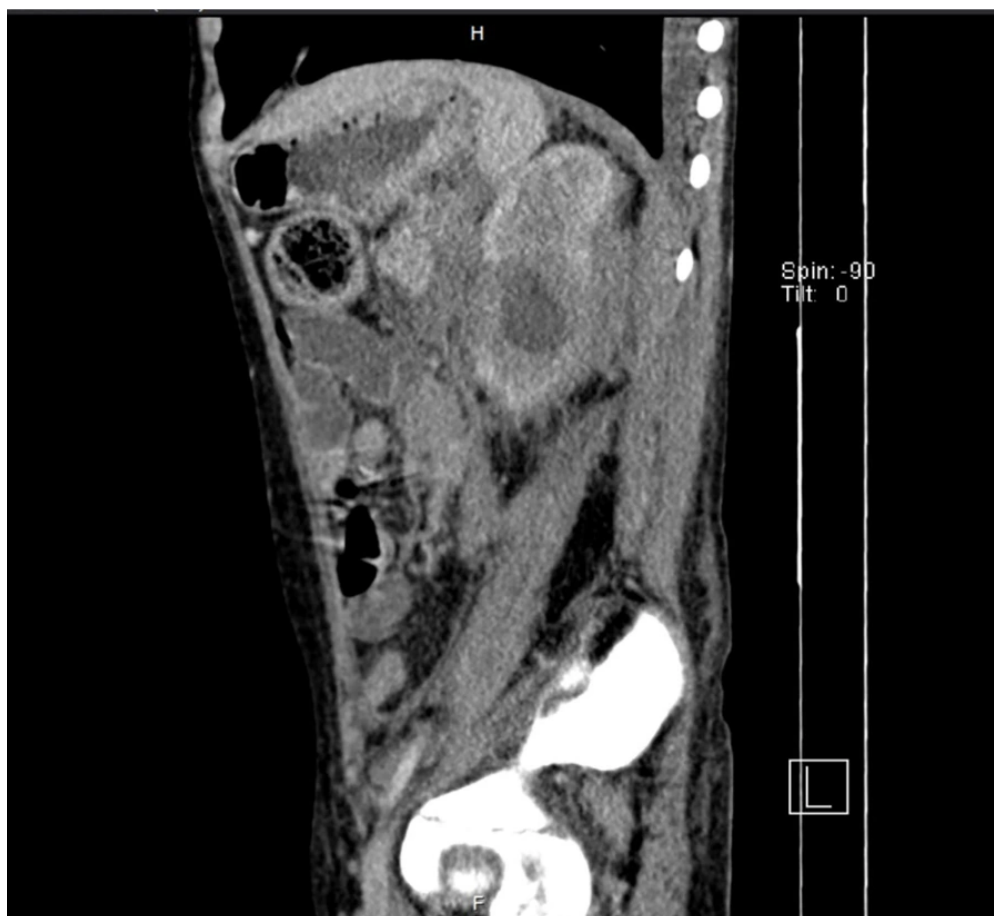

Figure 1. Contrast-enhanced CT demonstrating a retroperitoneal mass compressing major vessels and surrounding structures in the presented case.

2.5. Surgical Intervention

The patient underwent an exploratory laparotomy to assess the retroperitoneal mass. During the procedure, the mass was found to be fibrotic and extensive, with adhesions involving the aorta, IVC, and adjacent structures such as the ureters, kidneys, and surrounding lymphatic tissues, rendering complete resection unfeasible. A biopsy was taken during the operation, and the abdomen was subsequently closed. Histopathological examination of the specimen verified basidiobolomycosis, consistent with previous diagnoses (Figure 2).

2.6. Treatment and Clinical Outcome

The patient was treated with an extensive antifungal and antibiotic regimen, including amphotericin B for 12 days, voriconazole for 12 days, and adjunct antibiotics such as meropenem for 12 days and vancomycin for 7 days. Initial treatment with itraconazole was attempted but discontinued due to disease progression and a lack of clinical response, necessitating a switch to alternative antifungal agents. Bilateral double-J (DJ) stents were inserted to manage hydronephrosis resulting from ureteral compression by the retroperitoneal mass. Despite the procedure, the obstruction persisted due to the ongoing mechanical pressure exerted by the mass.

Enoxaparin was initiated as anticoagulation therapy to manage thrombosis identified in the left common femoral, superficial femoral, and iliac veins. Post-discharge, follow-up monitoring of anti-Xa levels was planned to ensure the efficacy of anticoagulation.

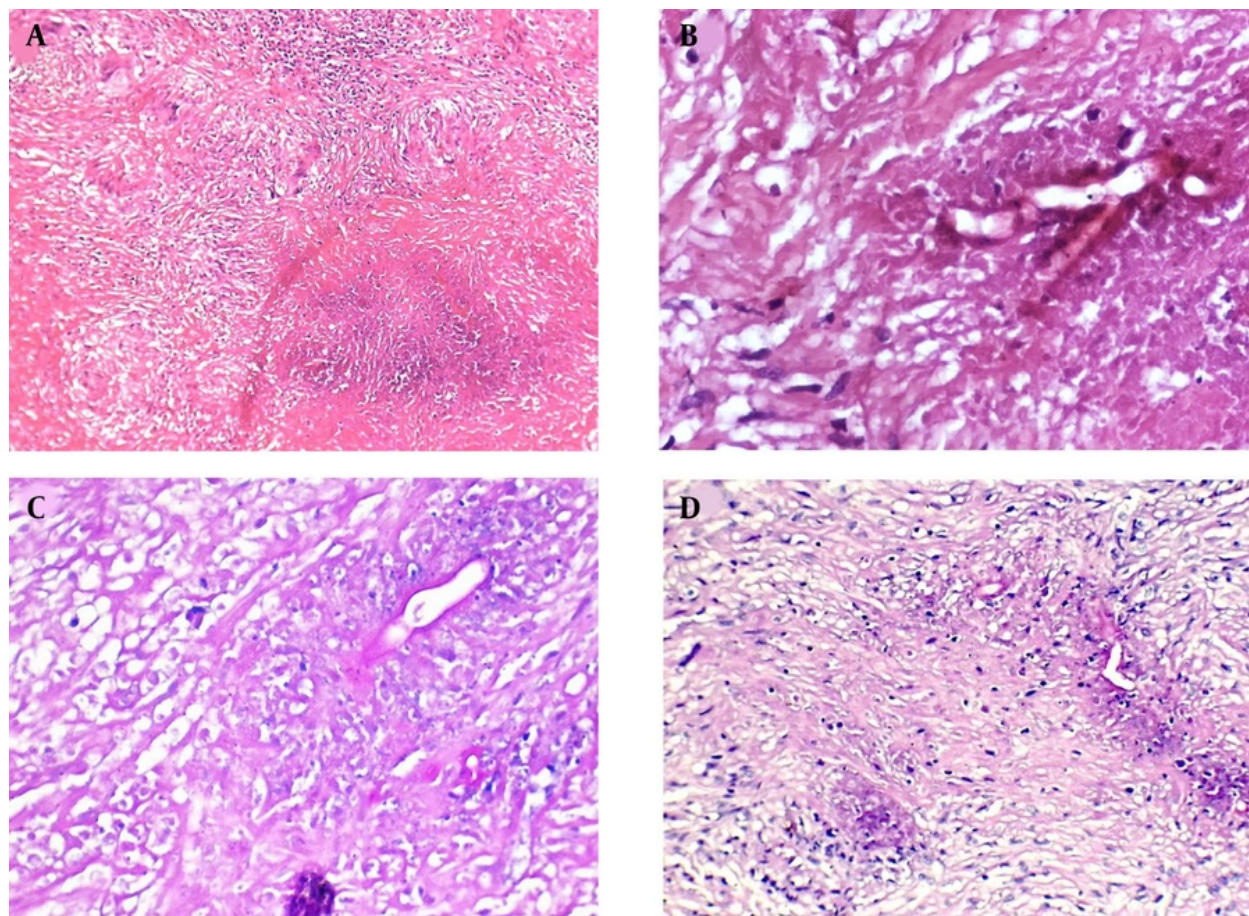


Figure 2. A, Necrotizing granulomatous inflammation (H&E, X100); B, eosinophilic cuff surrounding the hyphae, characteristic of the Splendore-Hoeppli phenomenon (H&E, X400); C, broad-based hyphae of basidiobolomycosis (PAS, X400); D, fungal hyphae within necrotic debris (H&E, X200).

therapy. At the time of admission, the patient was febrile, unable to tolerate oral intake, and had a firm abdomen on examination. Following the initiation of antifungal therapy, anticoagulation, and supportive care, the fever resolved completely. Gastrointestinal symptoms improved markedly, allowing the patient to return to a full oral diet. Abdominal examination findings normalized, transitioning from a firm and tense state to soft by the time of discharge.

Despite the administration of nephrotoxic medications such as amphotericin B and voriconazole, renal function remained stable, demonstrating the effectiveness of comprehensive monitoring. Although the retroperitoneal mass could not be resected due to severe adhesions to vital structures, the patient showed notable clinical improvement. The patient was

discharged with ongoing antifungal therapy and anticoagulation, and a comprehensive follow-up plan was established to monitor thrombosis resolution, renal function, and the response of the mass to continued treatment.

3. Discussion

Gastrointestinal basidiobolomycosis, caused by the fungus *B. ranarum*, represents a rare infectious disease associated with contact with contaminated soil or organic matter (1). This infection predominantly affects children living in tropical and subtropical zones and is frequently underdiagnosed due to its nonspecific presentation (4, 5). Presenting with prolonged abdominal pain, colonic ulcerative lesions, and systemic manifestations like fever and weight loss, the patient

was initially diagnosed with IBD, specifically Crohn's disease, and treated with anti-TNF therapy due to unresponsiveness to common treatment. A considerable overlap in symptoms between GIB and IBD has been thoroughly documented, with diagnostic delays often worsening morbidity (3, 13).

In this case, the imaging findings introduced further complexity to the diagnostic process. The presence of a large retroperitoneal mass, bilateral hydronephrosis, and vertebral lesions raised suspicion for lymphoma, highlighting a common diagnostic pitfall in GIB cases (10, 14). Hypermetabolic activity observed in the L3-L5 vertebrae and proximal radius initially raised concerns for potential metastatic disease. These findings align with documented cases where GIB mimics neoplastic or granulomatous diseases, often delaying appropriate treatment (15, 16). Unresponsive symptoms, coupled with inconclusive imaging findings, prompted an exploratory laparotomy, underscoring the challenges in diagnosing such a rare condition (7).

Histopathological confirmation remains pivotal in diagnosing GIB, as demonstrated in this case. Biopsy findings showed necrotizing granulomas containing fungal hyphae surrounded by the Splendore-Hoeppli phenomenon, indicative of basidiobolomycosis (6, 10). The application of PAS and GMS stains was crucial in diagnosing basidiobolomycosis, as these techniques helped detect fungal elements and ruled out malignancies or chronic inflammatory conditions (3, 14). These findings underscore the importance of histopathological evaluation in cases where imaging and clinical characteristics are inconclusive, as it provides definitive confirmation of the diagnosis (2).

Antifungal therapy remains the foundation of GIB management, and while itraconazole has been traditionally used, recent evidence suggests that liposomal amphotericin B and voriconazole are more effective for invasive cases, especially those involving vascular or retroperitoneal complications (17, 18). In our patient, itraconazole was discontinued due to unresponsiveness, requiring a switch to amphotericin B and voriconazole, a regimen consistent with alternative therapies described in the literature (7, 13). Following voriconazole treatment, a significant reduction in the retroperitoneal mass was observed, validating its effectiveness. However, extended treatment and vigilant observation remain crucial to achieve complete resolution and address potential recurrence (4, 5). The successful preservation of renal function despite nephrotoxic treatment, particularly in the context of hydronephrosis, highlights the importance of vigilant monitoring and tailored management (7).

The complications associated with GIB in this case were significant. Despite the placement of bilateral DJ stents, hydronephrosis persisted, as the obstruction was due to mechanical compression from the retroperitoneal mass rather than functional obstruction. Hydronephrosis resulting from ureteral compression is also observed in abdominal GIB and typically requires surgical or urological management (5, 19). Additionally, the patient developed venous thrombosis in the iliac and femoral veins, accompanied by collateral variceal vessels, a rare but serious complication potentially attributable to mass effect (20). Anticoagulation therapy with enoxaparin was initiated, with plans for post-discharge follow-up to check anti-Xa levels, aligning with management protocols reported in previous cases (18).

The environmental conditions of Yazd, a hot and arid city in the central region of Iran, likely played a key role in the patient's infection (14). Soil, a recognized reservoir for *B. ranarum*, likely served as the source of exposure, reflecting findings from comparable cases in endemic regions (9, 11). Public health awareness in endemic regions remains crucial to reduce the risk of soil-borne infections, particularly in children who are more likely to have frequent soil contact.

This case provides an important contribution to understanding GIB, highlighting its diagnostic challenges and mimicry of IBD and malignancies. The inclusion of skeletal involvement, vascular complications, and unrelenting mass effect underlines an expanded spectrum of GIB characteristics documented in the literature. This underscores the critical importance of early diagnosis through histopathology and the necessity for tailored therapy to effectively manage complications. Future research should prioritize developing advanced diagnostic tools for earlier detection, refining antifungal therapy protocols, and investigating adjunctive treatments to improve outcomes in this rare yet significant disease.

Footnotes

Authors' Contribution: Study concept and design: M. G., R. M. G., and F. S.; Acquisition of data: M. G., F. S., M. K. A., and A. T.; Analysis and interpretation of data: M. G. and A. T.; Drafting of the manuscript: M. G. and A. T.; Critical revision of the manuscript for important intellectual content: R. M. G., F. S., and J. G.; Administrative, technical, and material support: M. K. A., F. S., and J. G.; Study supervision: F. S. and R. M. G.

Conflict of Interests Statement: The authors declare that they have no conflicts of interest related to this manuscript.

Data Availability: The dataset presented in this study is available upon request from the corresponding author. The data are not publicly available due to ethical and privacy restrictions.

Funding/Support: This research did not receive any specific grant from funding agencies in the public, commercial, or not-for-profit sectors.

Informed Consent: Written informed consent was obtained from the participant.

References

1. Shaaban HE, Almatrafi MA, Telmesani A. A Pediatric Case of Basidiobolomycosis Presenting With an Abdominal Mass. *Cureus*. 2022;**14**(6). e25986. <https://doi.org/10.7759/cureus.25986>.
2. Mirmoosavi S, Salehi M, Fatahi R, Arero AG, Kamali Sarvestani H, Azmoudeh-Ardalan F, et al. Gastrointestinal basidiobolomycosis - A rare fungal infection: Challenging to diagnose yet treatable - Case report and literature review. *IDCases*. 2023;**32**. e01802. [PubMed ID: 37250379]. [PubMed Central ID: PMC10220263]. <https://doi.org/10.1016/j.idcr.2023.e01802>.
3. Mohammed M, Albishri A, Alabbas A, Abdelmogeit SE, Alasmari BG, Alqahtani JA, et al. Gastrointestinal Basidiobolomycosis in Pediatric Cases With Multiple-Site Involvement: A Case Series. *Cureus*. 2024;**16**(12). e76451. <https://doi.org/10.7759/cureus.76451>.
4. Kurteva E, Bamford A, Cross K, Watson T, Owens C, Cheng F, et al. Colonic Basidiobolomycosis-An Unusual Presentation of Eosinophilic Intestinal Inflammation. *Front Pediatr*. 2020;**8**:142. [PubMed ID: 32373558]. [PubMed Central ID: PMC7186448]. <https://doi.org/10.3389/fped.2020.00142>.
5. Ateik A, Ghabisha S, Almutamaiz A, Almutawakel A, Mohamed A, Ahmed F. Hepatic basidiobolomycosis in a 2-year-old child: A case report. *J Pediatric Surg Case Rep*. 2025;**114**:102956. <https://doi.org/10.1016/j.epsc.2025.102956>.
6. Zekavat OR, Abdolkarimi B, Pouladfar G, Fathpour G, Mokhtari M, Shakibazad N. Colonic basidiobolomycosis with liver involvement masquerading as gastrointestinal lymphoma: a case report and literature review. *Rev Soc Bras Med Trop*. 2017;**50**(5):712-4. [PubMed ID: 29160525]. <https://doi.org/10.1590/0037-8682-0057-2017>.
7. Pezzani MD, Di Cristo V, Parravicini C, Sonzogni A, Tonello C, Franzetti M, et al. Gastrointestinal basidiobolomycosis: An emerging mycosis difficult to diagnose but curable. Case report and review of the literature. *Travel Med Infect Dis*. 2019;**31**:101378. [PubMed ID: 30660554]. <https://doi.org/10.1016/j.tmaid.2019.01.013>.
8. Alskaff R, Alkhudari A, Skaff F, Sabbah BN, Abouzied MM. A case of basidiobolomycosis mimicking rhabdomyosarcoma: A diagnostic challenge. *Radiol Case Rep*. 2022;**17**(9):3425-31. [PubMed ID: 35899086]. [PubMed Central ID: PMC9309575]. <https://doi.org/10.1016/j.radcr.2022.07.004>.
9. Alshenawy W, Abdulrahim Mohamed A, Mohammed Saad A, Othman A, Alshehri M, AlDandan S. Two Case Reports of Pediatric Gastrointestinal Basidiobolus Treated Medically, With Literature Review. *Saudi Med Horizons J*. 2024;**4**(3):159-68. <https://doi.org/10.54293/smhj.v4i3.110>.
10. Bshabshe AA, Joseph MRP, Hakami AMA, Azraqi TA, Humayed SA, Hamid ME. Basidiobolus haptosporus-like fungus as a causal agent of gastrointestinal basidiobolomycosis. *Med Mycol*. 2020;**58**(2):264-7. [PubMed ID: 3111900]. <https://doi.org/10.1093/mmy/myz046>.
11. Al Yazidi L, Al Sinani S, Al Adawi B, Al Riyami M, Wali Y, Al Rawas A, et al. Disseminated Basidiobolomycosis Caused by Basidiobolus omanensis in a Child with Acute Lymphoblastic Leukemia (ALL). Case Report and Literature Review. *Mycopathologia*. 2024;**189**(1):12. [PubMed ID: 38231359]. [PubMed Central ID: PMC10794288]. <https://doi.org/10.1007/s11046-023-00820-3>.
12. Tadayon A, Azh OR, Poor Khosravani M, Hamzavi SS, Yarmahmoodi F, Yeganeh BS, et al. Case Report: Gastrointestinal Basidiobolomycosis in a Young Girl with Cystic Fibrosis and Celiac Disease. *Am J Trop Med Hyg*. 2024;**110**(2):279-82. [PubMed ID: 38150739]. [PubMed Central ID: PMC10859802]. <https://doi.org/10.4269/ajtmh.23-0404>.
13. Mousavi MR, Pouladfar G, Taherifard E, Badiie P, Anbardar MH. An Infant with Acute Bloody Diarrhea and Gastrointestinal Basidiobolomycosis: An Unusual Presentation of a Rare Disease. *J Trop Pediatr*. 2021;**67**(3). [PubMed ID: 32734302]. <https://doi.org/10.1093/tropej/fmaa039>.
14. AlNuwaiser S, Allaf S, Mosaad F, Mirza A, Ahyad RA, Alawi A. Intussusception as a complication of gastrointestinal basidiobolomycosis: A case report. *J Pediatric Surg Case Rep*. 2023;**98**. <https://doi.org/10.1016/j.epsc.2023.102724>.
15. Krishnamurthy S, Singh R, Chandrasekaran V, Mathiyazhagan G, Chidambaram M, Deepak Barathi S, et al. Basidiobolomycosis complicated by hydronephrosis and a perinephric abscess presenting as a hypertensive emergency in a 7-year-old boy. *Paediatr Int Child Health*. 2018;**38**(2):146-9. [PubMed ID: 28112037]. <https://doi.org/10.1080/20469047.2016.1162392>.
16. Pouladfar G, Jahangiri S, Shahpar A, Nakhaie M, Nezhad AM, Jafarpour Z, et al. Navigating treatment for basidiobolomycosis: a qualitative review of 24 cases. *BMC Infect Dis*. 2024;**24**(1):816. [PubMed ID: 39134962]. [PubMed Central ID: PMC11318116]. <https://doi.org/10.1186/s12879-024-09664-8>.
17. Ghazwani SM, Arishi HM, Dhayhi NS, Shami MO, Gosadi IM, Rajab M, et al. Pediatric Gastrointestinal Basidiobolomycosis: A Retrospective Study from Jazan Province, Saudi Arabia. *Infect Drug Resist*. 2023;**16**:4667-76. [PubMed ID: 37484908]. [PubMed Central ID: PMC10362874]. <https://doi.org/10.2147/IDR.S416213>.
18. Al-Juaid A, Al-Rezqi A, Almansouri W, Maghrabi H, Satti M. Pediatric Gastrointestinal Basidiobolomycosis: Case Report and Review of Literature. *Saudi J Med Med Sci*. 2017;**5**(2):167-71. [PubMed ID: 30787778]. [PubMed Central ID: PMC6298377]. https://doi.org/10.4103/sjmm.sjmm_138_15.
19. Alsharidah A, Mahli Y, Alshabyli N, Alsuhailani M. Invasive Basidiobolomycosis Presenting as Retroperitoneal Fibrosis: A Case Report. *Int J Environ Res Public Health*. 2020;**17**(2). [PubMed ID: 31952125]. [PubMed Central ID: PMC7014094]. <https://doi.org/10.3390/ijerph17020535>.
20. Al Haq AM, Rasheedi A, Al Farsi M, Mehdaar A, Yousef Y, Rasheed K, et al. Gastrointestinal Basidiobolomycosis in pediatric patients: A diagnostic dilemma and management challenge. *Int J Pediatr Adolesc Med*. 2021;**8**(4):212-20. [PubMed ID: 34401445]. [PubMed Central ID: PMC8356120]. <https://doi.org/10.1016/j.ijpam.2020.05.003>.