

Severe Hypertension and Encephalopathy Due to Renin-Producing Hepatoblastoma

Azita Tavasoli¹, Mitra Mehrazma², Nakisa Hooman³, Ladan Afshar Khas¹

Abstract

Paraneoplastic syndromes result from secretion of hormones, peptides or cytokines by tumor or immune cross-reactivity between malignant and normal tissues. These conditions are rare in children, but when the clinical presentation of patients with a tumor is unusual, these syndromes should be emphasized.

Extrarenal tumors with renin-secretion are rare in children. They may be related to paraneoplastic syndromes. We report a 22-month-old infant with hepatoblastoma presented with severe hypertension and related neurologic symptoms due to high plasma renin activity. To the best of our knowledge, this is the second report of renin producing hepatoblastoma in the literature. However, due to lack of laboratory facilities such as immunohistochemical study or polyclonal antibody for human renin activity, we could not prove the secretion of renin just by tumor tissue cells, but this potentiality is very likely. Other intensive investigations did not show any other origin for rennin secretion or hypertension in this patient.

Keywords: Hepatoblastoma; Hypertension; Paraneoplastic syndromes; Renin

Please cite this article as: Tavasoli A, Mehrazma M, Hooman N, AfsharKhas L. Severe Hypertension and Encephalopathy Due to Renin-Producing Hepatoblastoma. *Iran J Cancer Prev.* 2013;6(4):227-30.

Introduction

Hypertension due to renin secretion by neoplastic tissue was first reported by Robertson et al in 1967 [1]. Subsequently, several cases of rennin-secreting tumors were presented with severe hypertension due to increased serum renin activity. Based on several recent case reports, in the majority of patients, rennin-secreting tumors arise in the kidney as benign juxtaglomerular cell tumors [2-6] and more rarely as wilm's tumors, Grawitz's tumors or renal hamartomas [7]. Extrarenal origin for renin - secreting tumors is rare; however, some cases of adrenal and ovarian tumors or pelvic teratoma were reported [8-10]. The prognosis of these tumors is usually poor because the tumor is histologically aggressive and advanced at the time of diagnosis [7]. Severe hypertension due to increased serum rennin activity is usually the primary clinical manifestation of these tumors [7] and the term "primary reninism" has been applied for the clinical symptoms resulting from renin-secreting tumors.

In this study, we report an infant with a rennin-producing hepatoblastoma that presented with severe hypertension and neurologic symptoms. To the best of our knowledge, this is the second report of renin producing hepatoblastoma in the literature.

1. Dept. of Pediatric Neurology, Ali Asghar Hospital, Tehran University of Medical Sciences, Tehran, Iran

2. Oncopathology Research Center, Tehran University of Medical Sciences, Tehran, Iran

3. Dept. of Pediatrics Nephrology, Ali Asghar Hospital, Tehran University of Medical Sciences, Tehran, Iran

Corresponding Author:

AzitaTavasoli, MD;
Assistant Professor of Pediatric Neurology

Tel: (+98) 21 22 22 20 42-45

Email: azita_tavasoli@yahoo.com

Received: 6 Jan. 2011

Accepted: 28 Mar. 2011

Iran J Cancer Prev. 2013; 4:227-30

Case Report

A 22-month-old boy was admitted in the Pediatric Intensive Care Unit with recurrent partial seizures in the right side of his body in Jun 2010. The patient had had cough and intermittent fever since a month ago and had not recovered despite using oral antibiotics. The past history was remarkable for the presence of developmental delay, poor weight gain, and recurrent oral candidiasis since 4-month old. The studies for metabolic, immunologic, and endocrine disorders were inconclusive.

From 2 weeks ago, the infant had developed right hemiparesis due to stroke, so he could not sit independently. He was the first offspring of consanguineous parents born in the thirty second week of gestational age with 2300gr birth body weight.

At admission, physical examination revealed severe hypertension (160/100mmHg), marked hepatomegaly, and right hemiparesis. Laboratory findings showed the following results: WBC count 9400/mm³ with 82% segmented cells, Hb was 9.7 gr/dl and MCV 69 fl, Platelets were normal. Serum biochemistry was normal except for mildly elevated

liver enzymes. LDH level was 1056 IU/L, prothrombotic factors were done with normal results, and Alfa-Feto Protein (AFP) was 446.3 IU/ml (normal: up to 5.5 IU/ml). Vanilmandelic Acid (VMA) and Hemovanilic Acid (HVA) in 24-hr. urine were normal at two separate measurements. Cortisol, metanephrine, normetanephrine, epinephrine and norepinephrine in 24-hr. urine were also normal.

Abdominal sonography revealed multiple solid and isoechoic masses in both lobes of the liver which was confirmed with abdominal Computed Tomography (CT scan) (Figure 1).

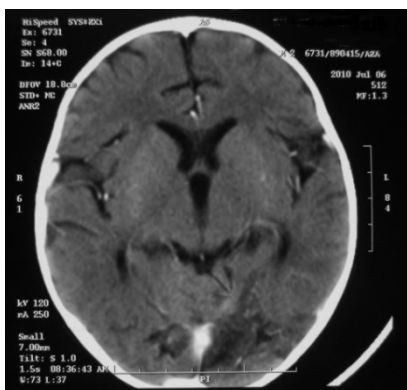


Figure 1. Brain MRI showed gliosis in medial portions of biparietal lobes and left occipital lobe.

Chest CT scan showed pneumonia. Magnetic resonance imaging of brain showed gliosis in medial portions of biparietal lobes and left occipital lobe due to previous vascular insult (Figure 2).

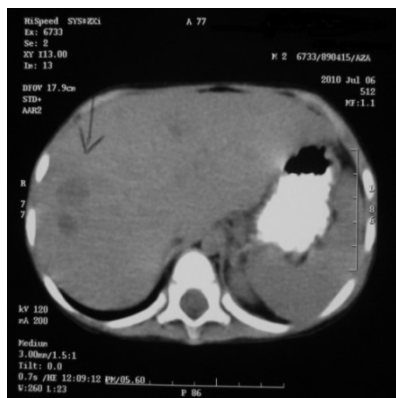

Figure 2. Abdominal CT scan showed multiple intrahepatic lesions.

Echocardiography, ruled out coarctation and other heart diseases. Renal function tests were normal. Doppler sonography performed by an expert radiologist did not show renal artery stenosis.

A markedly increased plasma renin activity was found (200 miclu/ml, normal level was up to 46.1); however, the level of plasma aldosterone was normal. Bone marrow aspiration was also normal.

Subsequently, hypertension and seizures were controlled, but pneumonia has progressed

despite different antibiotic and even antifungal therapy, the patient underwent assisted ventilation due to respiratory distress and depressed consciousness. His general condition deteriorated despite supportive therapy. Closed biopsy of liver suggested hepatoblastoma. For definite diagnosis, open biopsy was also done. Histological examination of the tumor showed sheets of small, round, uniform cells with moderate amount of eosinophilic or clear cytoplasm, and distinct cytoplasmic membranes. The cells arranged into these trabeculae, usually two or three cells thick, with alternating light and dark areas and reported definitely as hepatoblastoma, epithelial type, fetal pattern (Figure 3).

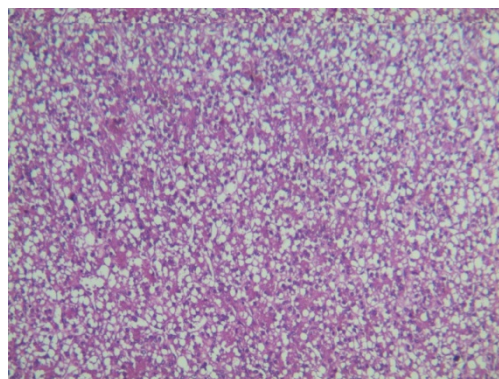


Figure 3. Histologic examination of the tumor showed sheets of small, round, uniform cells with clear or eosinophilic cytoplasm and distinct cytoplasmic membrane (H&E).

This report was confirmed independently by two pathologists. The tumor was not resectable, and the patient expired finally at 12th day of the admission.

Discussion

Paraneoplastic syndromes result from secretion of hormones, peptides or cytokines by tumor or immune cross-reactivity between malignant and normal tissues [11]. The most common tumors are small cell lung cancer, breast, gynecologic, and hematologic cancers. The proper and timely diagnosis of paraneoplastic syndromes can result in finding an occult tumor at an early stage [11]. These conditions are rare in children [7], but when the clinical presentation of a patient with a tumor is unusual, these syndromes should be emphasized like this

infant with renin producing hepatoblastoma that presented with severe hypertension and neurologic symptoms. The plasma renin activity of the patient was severely increased. Extensive work-up including radiological and biochemical studies did not demonstrate any renal parenchymal or renovascular origin. The laboratory facilities such as immunohistochemical study or polyclonal antibody for human renin activity were not available. Therefore, we could not prove the secretion of renin just by tumor tissue cells, but this potentiality is very likely. Hiroshi Moritake et al have reported an 8-year-old boy with renin producing hepatoblastoma in 1999 [7]. They confirmed the existence of renin messenger RNA in the tumor tissue by reverse transcriptase polymerase chain reaction and immunohistochemical study. We also supposed that high plasma renin activity and severe hypertension resulted in Cerebrovascular Accident (CVA), seizure and encephalopathy in our patient. Several work ups for other causes of encephalopathy and CVA were negative.

Hepatoblastoma consists of two thirds of malignant liver tumors in children [12]. It is the most common primary and malignant tumor of the liver in children [13, 14] and includes over 1% of pediatric cancers [12, 14]. In children under the age of 15, 79% of liver cancers are hepatoblastoma and in infants, the incidence is the highest [12]. Male to female ratio is 1.6-3.3 [2, 5, 8]. The etiology of tumor is not well known, but it may be linked to several congenital anomalies such as Beckwith-Wideman syndrome, familial adenomatosis polyp, hemihypertrophy and low birth weight [12, 14]. The incidence of hepatoblastoma is seemingly increased due to perinatal exposures and decreased premature infant mortality [12, 15]. An association between premature birth and later development of hepatoblastoma has been suggested by several recent studies [16-18]. Increased alfa-feto protein is a useful marker, but may also be found in hepatocellular carcinoma [12].

The most common presentation of hepatoblastoma is an enlarging mass. Less common symptoms are anorexia, weight loss, and pain [14]. Association with precocious puberty and hypertension has been reported [19, 7]. Metastases are seen in 10-20% of patients at the time of the diagnosis and the lung is the most common site [14]. Therefore, chest radiography and CT scan are recommended at the time of diagnosis of hepatoblastoma [12]. In our patient, pulmonary infiltrations in the form of pneumonia were seen by radiography, but chest CT scan did not reveal any metastatic foci.

Hepatoblastoma in abdominal sonography or CT scan appears as a focal or multifocal mass sometimes with calcification [20]. The most effective treatment is complete surgical resection [14, 21]. Recently, the role of chemotherapy has become increasingly important by enhancing the number of resectable tumors [4, 22].

Although liver transplantation is a useful treatment in children with unrespectable tumor with 90% survival rate [20], the outcome for such patients is poor [7, 14, 22].

Conclusion

While hepatoblastoma is the most common primary and malignant tumor of the liver in children, hypertension is a very rare and unusual presentation for it.

When the clinical presentation of patients with a specific tumor is unusual, paraneoplastic syndromes should be emphasized; like our case with renin producing hepatoblastoma that presented with severe hypertension and neurologic symptoms. Several cases of rennin-secreting tumors were presented with severe hypertension due to increased serum renin activity. In the majority of these cases, the renin-producing tumor is located in the juxtaglomerular cells of the kidney and in some cases in other organs. As found in the literature, only in one other report the hepatoblastoma was the origin of renin secretion and the authors could prove the secretion of renin by tumor cells.

Although due to lack of specific laboratory tests we could not confirm the secretion of renin just by the tumor tissue cells in this patient, this potentiality is very likely.

Acknowledgment

We would like to thank our colleagues in Departments of Radiology and Pediatric Surgery in Ali Asghar Hospital for their sincere cooperation.

Conflict of Interest

The authors have no conflict of interest in this article.

Authors' Contribution

Azita Tavasoli reviewed the literature and wrote the paper, Mitra Mehrzad contributed to literature review, Nakisa Hooman contributed to literature review and writing-up process and Ladan Afshar Khas collected the data from record of the patient.

References

1. Roswell RH. Renin secreting tumors. J Okla State Med Assoc. 1990;83(2):57-9.
2. Lin SY, Liu WY, Chen WC, Chen RH. Secondary hypertension due to a rennin-secreting juxtaglomerular cell tumor. J Formos Med Assoc. 2010;109(3):237-40.
3. Regolisti G, Cabassi A, Parenti E. Long-standing high-renin hypertension and hypokalemia : rennin-secreting tumor of the juxtaglomerular apparatus. Am J Kidney Dis. 2009;54(3):A41-4.
4. Beevers DG, Maheshwari MB, Ryan PG, Moss MS, Harding LK. Hypertension due to a renin-secreting juxtaglomerular cell tumor. Am J Hypertens. 2008; 21(12): 1359-61.
5. Ducret F, Turc-Baron C, Pointet P, Vernin G, Skowron O, Mc Gregor B. Renin-secreting tumor: about a new diagnosed case during pregnancy. NephrolTher. 2005;1(1):52-61.
6. Fujita K, Yoneda N, Yoshimura H. Secondary hypertension due to juxtaglomerular cell tumor. Nippon NaikaGakkaiZasshi. 2005;94(6):1143-5.
7. Moritake H, Taketomi A, kamimura S, Ikuno Y, Yousuke S, Toshirou F. Renin-producing Hepatoblastoma. Journal of Pediatric Hematology/Oncology. 2000; 22(1): 78-80.
8. Anderson PW, d'Ablaing G 3rd, Penny R, Sherrod A, Do YS. Secretion of prorenin by a virilizing ovarian tumor. GynecolOncol. 1992;45(1):58-61.
9. Limura O, shimamoto K, Hotta D, Nakata T, Mito T, Kumamoto Y. A case of adrenal tumor producing renin ,aldosterone , and sex steroid hormones. Hyppertension. 1986;8(10):951-6.
10. Pursell RN, Quinlan PM. Secondary hypertension due to a rennin producing teratoma. Am J Hypertens. 2003;16(7):592-5.
11. Pelosof LC, Gerber DE. Paraneoplastic syndromes: an approach to diagnosis and treatment . Mayo Clin Proc. 2010;85(9):838-54.
12. Litten JB, Tomlinson GE. Liver Tumors in Children. Oncologist. 2008;13:812-20.
13. Krstovski N, Janic D, Dokmanovic L, Smolijanac Z, Vukanic D. Clinical characteristic and survival of children with hepatoblasdtoma-single centre experience. Srp Arch CelokLek. 2008;136(11-12):603-8.
14. Herzog CE, Andrassy RJ, Eftekhari F. Childhood cancers: hepatoblastoma. Oncologist. 2000; 5(6): 445-53.
15. Reynolds P, Urayama KY, Von Behren J, Feusner J. Birth characteristics and hepatoblastoma risk in young children. Cancer. 2004;100(5):1070-6.
16. Spector LG, Puumala SE, Carozza SE, Chow EJ, Fox EE, Horel S, et al. Cancer risk among children with very low birth weights. Pediatric. 2009; 124(1):96-104.
17. Jaing TH, Hung IJ, Lin JN, Lien RI, Hsueh C, Lu CS. Hepatoblastoma in a child of extremely low birth weight. Am J Perinatol. 2002;19(3):149-53.
18. Pu CL, Guo CB, Jin XQ, Deng C, Zhang MM, Li YC, et al. Retrospective analysis of maternal and infant birth fitures of hepatoblastoma patients. ZHONGHUA GanZang Bing ZaZhi. 2009;17(6):459-61.
19. Saxena R, Leake JL, Shafford EA. Chemotherapy effects on hepatoblastoma. Am J SurgPathol. 1993;17:1266-71.
20. Jabra AA, Fishman EK, Taylor G. Hepatic masses in infants and children: CT evaluation .Am J Roengenol. 1992;158:143-9.
21. Browne M, Sher D, Grant D, DELUCA e, Alonso E, Whittington PF. Survival after liver transplantation for hepatoblastoma: a 2- center experience. J Pediatr Surg. 2008;43(11):1973 -81.
22. Horton JD, Lee S, Brown SR, Bader J, Meyer DE. Survival trends in children with hepatoblastoma. PediatrSurg int. 2009;25(3):407-12.