Uncorrected Proof

Int J Cardiovasc Pract. 2026 December; 11(2): e176786 https://doi.org/10.5812/intjcardiovascpract-176786

Published Online: 2026 November 23

Case Report

# Successful Administration of Very High Dose of Adenosine Into Distal Coronary Using a Thrombus Aspiration Catheter for Resistant No-reflow

Mohammad Reza Movahed [1,2,*], Mohammad Javad Namazi [3]

[1] Department of Medicine, University of Arizona Sarver Heart Center, Tucson, United States
[2] Department of Medicine, University of Arizona, Phoenix, United States
[3] Department of Radiation Oncology, Mayo Clinic, Rochester, United States

[*] ***Corresponding Author:*** Department of Medicine, University of Arizona Sarver Heart Center, Phoenix, United States. Email: rmova@aol.com

**Received:** 12 November, 2026; **Revised:** 19 November, 2026; **Accepted:** 22 November, 2026

## Abstract

Resistant no-reflow can be difficult to treat. Unfortunately, persistent no-reflow can increase cardiac adverse events. Intracoronary injections of vasoactive substances into the proximal coronaries may not efficiently reach the distal coronary bed. In this case, we report distal administration of a very high dose of adenosine in a native coronary artery for a severe life-threatening resistant no-reflow. Using an export catheter (Medtronic, Minneapolis, USA), flow was restored within seconds after the injection. Transient ventricular fibrillation occurred after reperfusion and was successfully cardioverted. This case suggests that giving high doses of vasoactive drugs as distally as possible may be an option for resistant no-reflow, and that an export catheter may be a practical way to do so.

*Keywords:* No-Reflow Phenomenon, Percutaneous Coronary Intervention, Angioplasty, Stents

## 1. Introduction

No-reflow occurring during percutaneous coronary intervention (PCI) can be unpredictable and can increase cardiovascular adverse events. Initial treatment with intracoronary vasoactive drugs administered into a proximal coronary artery has limited success because of the inability to reach the distal coronary bed (1). Despite available treatment modalities, persistent no-reflow can occur in a substantial number of patients and is associated with worse outcomes, including severe mitral regurgitation and cardiogenic shock (2-4). Furthermore, because of proximal injection, more systemic side effects can occur, limiting the doses that can be administered. Therefore, administering active drugs very distally may help them reach the distal coronary bed and, at the same time, may reduce the systemic drug effect. This can be done using an over-the-balloon or a microcatheter. However, this approach is time-consuming, as it requires docking the short wire and removing the wire after distal advancement of the balloon or microcatheter. In addition, the small lumen makes it more difficult to administer high doses of drugs. An export catheter (Medtronic, Minneapolis, USA) is a monorail system with a very large lumen, making it a potentially suitable catheter for this purpose. In this case report, building on previous reports of distal drug delivery, we describe the distal administration of a high dose of adenosine through an export catheter in a native coronary artery for life-threatening resistant no-reflow.

## 2. Case Presentation

A 69-year-old White man presented to the emergency department with sudden-onset severe substernal chest pain that had lasted for two hours. His electrocardiogram revealed an inferior ST-elevation myocardial infarction. The patient was urgently taken to the cardiac catheterization laboratory, and access was obtained via his right radial artery. He was found to have a distal right coronary artery occlusion, which was successfully stented, with resolution of his ST elevation and chest pain. His left anterior descending artery (LAD) angiogram revealed two 80 – 90% mid lesions (Figure 1). He remained free of chest pain, with persistently normal creatinine levels. He was treated with

Copyright © 2026, International Journal of Cardiovascular Practice. This open-access article is available under the Creative Commons Attribution 4.0 (CC BY 4.0) International License (https://creativecommons.org/licenses/by/4.0/), which allows for the copying and redistribution of the material only for noncommercial purposes, provided that the original work is properly cited.

**How to Cite:** Movahed MR, Namazi MJ. Successful Administration of Very High Dose of Adenosine Into Distal Coronary Using a Thrombus Aspiration Catheter for Resistant No-reflow. Int J Cardiovasc Pract. 2026;11(2):e176786. doi: https://doi.org/10.5812/intjcardiovascpract-176786

prasugrel, atorvastatin, aspirin, and metoprolol and had a normal ejection fraction on echocardiography. He was brought back to the cardiac catheterization laboratory two days later for staged PCI of his LAD lesions using the same right radial access. No significant thrombotic lesions were seen in the LAD, but the LAD appeared to contain numerous soft plaques. A 6-French slender sheath was used for radial access. His oral prasugrel, statin, and aspirin were given in the morning before the staged PCI. A weight-based bivalirudin bolus was given, and a continuous intravenous infusion was started after sheath insertion.




**Figure 1.** Coronary angiogram shows two 80 – 90% mid-LAD lesions (Right Anterior Oblique, Cranial view).

A 6-French EBU 3.5 catheter was used to engage the left main coronary artery. A Balance Middle Weight 0.014-inch wire (Abbott Vascular, Santa Clara, California) was easily advanced across the lesions. An Emerge 2.0 mm × 12 balloon (Boston Scientific, Marlborough, Massachusetts) was advanced across both lesions and inflated to 8 – 10 atmospheres. Next, a Synergy 2.5 × 16 stent (Boston Scientific, Marlborough, Massachusetts) was advanced across the distal lesion and inflated to 18 atm. After stenting, severe no-reflow occurred, with severe chest pain and anterior ST elevation (Figure 2). The no-reflow was thought to be caused by distal embolization of soft plaque debris. Multiple intracoronary doses of 80 and 100 micrograms of adenosine administered into the left main coronary artery did not improve the flow, and his chest pain worsened. The patient was restless, with severe chest pain and persistent ST elevation. The decision was made to proceed with distal administration of a very high dose of adenosine. An Export thrombectomy catheter (Medtronic, Minneapolis, MN) was advanced into the mid-LAD (Figure 3). We did not see any sign of thrombus formation as the cause of no-reflow; therefore, no thrombus extraction was performed. Within seconds of distal administration of a high dose (500 micrograms) of adenosine, distal flow immediately normalized. The patient developed transient ventricular fibrillation, which was thought to be a reperfusion arrhythmia, and was successfully cardioverted. Because the initial stent had already been deployed at a very high pressure of 18 atmospheres, no post-dilatation was performed, to reduce the risk of recurrent no-reflow. The patient underwent additional proximal stenting with a Synergy 2.75 × 20 mm stent (Boston Scientific, Marlborough, Massachusetts) deployed at 18 atm, with excellent results (Figure 4). The patient remained free of chest pain, with persistent Thrombolysis in Myocardial Infarction (TIMI) grade 3 flow, and was discharged the next day on aspirin, a statin, metoprolol, and prasugrel. His predischarge echocardiogram revealed a persistently normal ejection fraction with mild basal inferior wall hypokinesia.

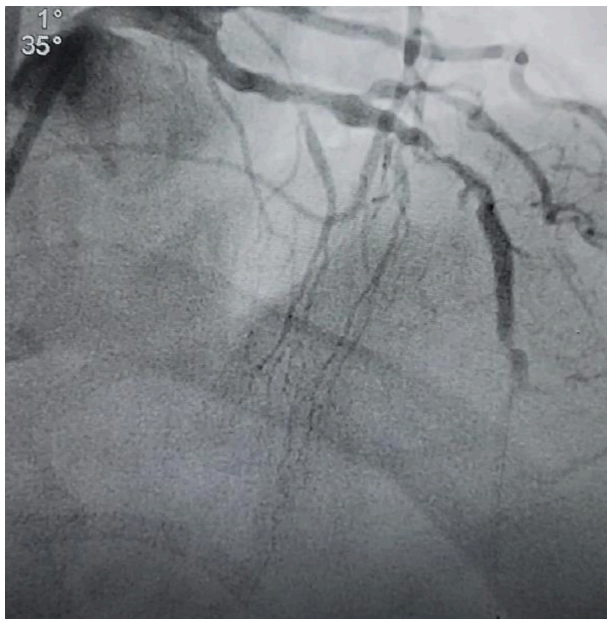


**Figure 2.** The occurrence of no-reflow (Anterior Oblique, Cranial view).

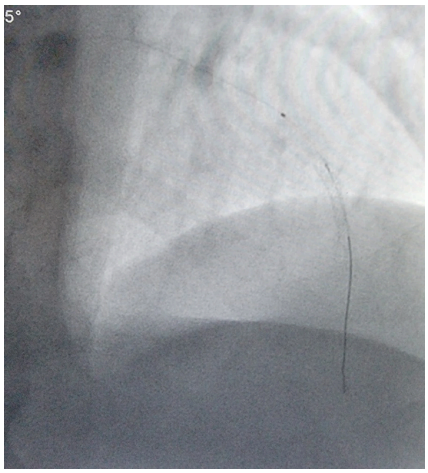

**Figure 3.** Export catheter is seen in mid left anterior descending artery for distal adenosine administration (Anterior Oblique, Cranial view).



**Figure 4.** Final results with resolution of no-reflow (Right Anterior Oblique, Cranial view).

## 3. Discussion

No-reflow is a serious condition that requires immediate attention. Many therapeutic interventions have been described in the literature, with varying success. Treatment options for no-reflow focus on medications that induce vasodilatation in the microvascular bed. Three well-known and commonly used vasodilators are adenosine, verapamil, and nitroprusside (1). Intracoronary infusion of verapamil is supposed to improve flow in more than 80% of cases but has failed to reduce mortality in patients with no-reflow in the setting of myocardial infarction (1, 5). Adenosine is another vasoactive drug; it has a very short half-life and is a potent microvascular dilator. It has been successful in 90% of no-reflow cases (1, 6). However, because of transient sinus arrest, its dose is limited. On the other hand, the very short half-life of adenosine is a great advantage over other vasoactive drugs. Intracoronary nitroprusside is the third most commonly used drug for treating no-reflow (1, 7). It has been shown to improve no-reflow in 75% of cases but could not show any mortality benefit. Similar to verapamil, it has a longer half-life and, in high doses, can cause hypotension, but it will not cause any bradycardia, unlike adenosine or verapamil. Intracoronary epinephrine has been successful in reversing no-reflow in 69% of cases with refractory no-reflow (1, 5). However, severe hypertension and arrhythmia can occur, limiting its use. Other agents, such as glycoprotein IIbIIIa inhibitors or intracoronary antithrombotic agents, have also been used with some success (1). Prophylactic nicardipine injection before vein graft intervention has been successful (8). Unfortunately, many of these approaches often fail to reverse persistent no-reflow (2, 4). However, with the availability of an export catheter, distal administration of very high doses of adenosine may be performed easily and quickly. Distal administration of vasoactive substances has been successfully reported in a limited number of case reports but remains underutilized. We reported the first successful case in 2008, before export catheters were available, using an over-the-wire balloon catheter, which is more time-consuming and requires wire extension (9). Another successful case in a vein graft was reported recently (10). More recently, the Clearway catheter (Atrium Medical, Hudson, NH), a rapid-exchange balloon catheter, has been successfully used for this purpose (11). To our knowledge, this is among the first reports of a high dose of adenosine (500 micrograms) given distally through an export catheter for resistant no-reflow in a native coronary artery. Distal delivery through an export catheter has been described previously in a vein graft (10) and in a comparative study (12); thus, the new aspect of our case is the use of a high adenosine dose in a native coronary artery after no-reflow had not responded to proximal adenosine. We believe that this approach may be considered in patients with resistant no-reflow (13), but more experience is needed. Because of the very short half-life of adenosine, distal administration of higher doses may be feasible. However, the safety of this approach cannot be established from a single case. Our patient developed transient ventricular fibrillation after reperfusion that required cardioversion. We attributed it to reperfusion, but a contribution of the high-dose adenosine or of the catheter itself cannot be excluded. Other vasoactive drugs may also

be given with this approach. A recent study comparing proximal versus distal administration of vasoactive drugs through an export catheter in patients with no-reflow reported restoration of flow in 88% versus 76% of patients, which is consistent with our observation (12). However, that study did not assess the feasibility and safety of giving high doses distally, which remain to be determined. A transit catheter could also be used for distal vasoactive drug administration, but its lumen is very small compared with that of an export catheter, making it a less than ideal device for this purpose. Experience with aspiration catheters and forceful saline injection in patients with ST-elevation myocardial infarction (STEMI) (the SALINE technique) has shown some clinical success, with improvement in ST elevation (14). This may be an alternative treatment for no-reflow. Furthermore, this experience with forceful distal saline injection through aspiration catheters is in line with our case, in which distal administration of a drug-containing fluid via an aspiration catheter appeared feasible and effective. Repeated distal administration of 50 micrograms of nitroprusside (up to a total dose of 200 micrograms) has been reported to reverse no-reflow in two vein graft interventions without significant adverse events (11). These two case reports suggest that distal coronary administration of vasoactive drugs may be safe. However, only standard doses of nitroprusside were used; therefore, these reports could not show the safety of a much higher dose, which could cause hypotension because of the longer half-life of nitroprusside, in contrast to the very short half-life of adenosine, which may allow the administration of higher doses. With this manuscript, we hope to raise awareness in the interventional community of this approach for treating resistant no-reflow. Furthermore, we suggest that an aspiration catheter may be a practical method for this treatment option.

### 3.1. Conclusions

Distal high-dose administration of a vasoactive drug with a short half-life, such as adenosine, through an export catheter restored flow in a patient with resistant no-reflow. This approach may be a safe and effective option for resistant and persistent no-reflow; however, transient ventricular fibrillation occurred in our patient, and further experience and larger studies are needed to define its safety and efficacy.

## Footnotes

**AI Use Disclosure:** The authors declare that no generative AI tools were used in the creation of this article.

**Authors' Contribution:** Conceptualization: Mohammad Reza Movahed; Writing—original draft: Mohammad Javad Namazi.

**Conflict of Interests Statement:** The authors declare no conflict of interests.

**Data Availability:** The dataset presented in this study is available from the corresponding author upon request during submission or after publication.

**Ethical Approval:** This study adhered to all the principles of the Declaration of Helsinki. As this study is a case report, written informed consent was obtained from the patient.

**Funding/Support:** No funding was used for this study.

**Informed Consent:** Written informed consent was obtained from the patient for publication of this case report.

## References

1. Movahed MR, Butman SM. The pathogenesis and treatment of no-reflow occurring during percutaneous coronary intervention. *Cardiovasc Revasc Med*. 2008;**9**(1):56-61. [PubMed ID: 18206640]. https://doi.org/10.1016/j.carrev.2007.08.005.
2. Zuccarelli V, Andreaggi S, Walsh JL, Kotronias RA, Chu M, Vibhishanan J, et al. Treatment and care of patients with ST-segment elevation myocardial infarction-what challenges remain after three decades of primary percutaneous coronary intervention? *J Clin Med*. 2024;**13**(10):2923. [PubMed ID: 38792463]. [PubMed Central ID: PMC11122374]. https://doi.org/10.3390/jcm13102923.
3. Movahed MR, Balian H, Moraghebi P. Reversible severe ischemic mitral regurgitation and cardiogenic shock as a complication of percutaneous coronary intervention. *J Invasive Cardiol*. 2005;**17**(2):104-107. [PubMed ID: 15687537].
4. Papapostolou S, Andrianopoulos N, Duffy SJ, Brennan AL, Ajani AE, Clark DJ, et al. Long-term clinical outcomes of transient and persistent no-reflow following percutaneous coronary intervention (PCI): A multicentre Australian registry. *EuroIntervention*. 2018;**14**(2):185-193. [PubMed ID: 28966156]. https://doi.org/10.4244/EIJ-D-17-00269.
5. Abu Arab T, Sedhom R, Gomaa Y, El Etriby A. Intracoronary adenosine compared with adrenaline and verapamil in the treatment of no-reflow phenomenon following primary PCI in STEMI patients. *Int J Cardiol*. 2024;**410**:132228. [PubMed ID: 38844092]. https://doi.org/10.1016/j.ijcard.2024.132228.
6. Marchi E, Muraca I, Berteotti M, Gori AM, Valenti R, Marcucci R. Adenosine in interventional cardiology: Physiopathologic and pharmacologic effects in coronary artery disease. *Int J Mol Sci*. 2024;**25**(11):5852. [PubMed ID: 38892037]. [PubMed Central ID: PMC11172110]. https://doi.org/10.3390/ijms25115852.
7. Scarpone M, Cenko E, Manfrini O. Coronary no-reflow phenomenon in clinical practice. *Curr Pharm Des*. 2018;**24**(25):2927-2933. [PubMed ID: 29962336]. https://doi.org/10.2174/1381612824666180702112536.
8. Habibzadeh MR, Thai H, Movahed MR. Prophylactic intragraft injection of nicardipine prior to saphenous vein graft percutaneous intervention for the prevention of no-reflow: A review and comparison to protection devices. *J Invasive Cardiol*. 2011;**23**(5):202-206. [PubMed ID: 21562350].

9. Movahed MR, Baweja G. Distal administration of very high doses of intracoronary adenosine for the treatment of resistant no-reflow. *Exp Clin Cardiol*. 2008;**13**(3):141-143. [PubMed ID: 19343130]. [PubMed Central ID: PMC2586412].
10. Movahed MR. Successful distal administration of high doses of adenosine and nicardipine using export catheter for treatment of resistant no-reflow in a vein graft. *Am J Cardiovasc Dis*. 2022;**12**(1):53-55. [PubMed ID: 35291506]. [PubMed Central ID: PMC8918739].
11. Wilson W, Eccleston D. How to manage no reflow phenomenon with local drug delivery via a rapid exchange catheter. *Catheter Cardiovasc Interv*. 2011;**77**(2):217-219. [PubMed ID: 21290555]. https://doi.org/10.1002/ccd.22722.
12. Kumar D, Ahmed I, Bardooli F, Saghir T, Sial JA, Khan KA, et al. Techniques to treat slow-flow/no-reflow during primary percutaneous coronary intervention. *Cardiovasc Revasc Med*. 2023;**47**:1-4. [PubMed ID: 36266151]. https://doi.org/10.1016/j.carrev.2022.09.014.
13. Movahed MR. Distal administration of very high doses of adenosine using over-the-wire balloon or export catheter should be the first choice for treatment of patients with resistant no-reflow. *Catheter Cardiovasc Interv*. 2022;**99**(1):E43. https://doi.org/10.1002/ccd.29280.
14. Grancini L, Diana D, Centola A, Monizzi G, Mastrangelo A, Olivares P, et al. The SALINE technique for the treatment of the no-reflow phenomenon during percutaneous coronary intervention in STEMI. *J Clin Med*. 2023;**12**(6):2405. [PubMed ID: 36983405]. [PubMed Central ID: PMC10057061]. https://doi.org/10.3390/jcm12062405.