

M. Alimohamadi MD<sup>1</sup>  
 A. Naim MD<sup>1</sup>  
 S.E. Ketabchi MD<sup>2</sup>  
 A.H. Sina MD<sup>3</sup>  
 A. Amirjamshidi MD, MPH<sup>2</sup>

1. Department of Neurosurgery, Sina Hospital, Tehran University of Medical Sciences, Tehran, Iran.

2. Professor, Department of Neurosurgery, Sina Hospital, Tehran University of Medical Sciences, Tehran, Iran.

3. Department of Pathology, Sina Hospital, Tehran University of Medical Sciences, Tehran, Iran.

Corresponding Author:  
 Abbas Amirjamshidi  
 Address: Department of Neurosurgery,  
 Sina Hospital, Imam Khomeini Ave.,  
 Tehran, Iran  
 Tel: +9821-66701041  
 Fax: +9821-66701041  
 Email: abamirjamshidi@yahoo.com

Received July 27, 2008;  
 Accepted after revision December 20,  
 2008.

Iran J Radiol 2009;6(2):83-86

## Low Grade Astrocytoma Originating from the Prechiasmatic Intracranial Optic Nerve Presenting as an Intra-Axial Intracerebral Lesion; Rarity in Rarity

Optic nerve glioma (ONG) originating purely from the intracranial part of the optic nerve is a very rare presentation of optic pathway gliomas. We encountered a 48-year-old woman presenting with an intra-axial lesion in preoperative magnetic resonance imaging (MRI), which turned out to be a lesion originating from the intracranial segment of the optic nerve. We intend to present the case and discuss the interesting and misleading images and the different aspects of management of this rare pathology briefly.

**Keywords:** Pilocytic Astrocytoma, Exophytic Glioma, Optic Nerve Glioma.

### Introduction

Intracranial optic nerve glioma (ONG) is a rather rare entity comprising about 0.6-1.2% of all brain tumors.<sup>1</sup> The natural course of optic apparatus glioma is highly variable, depending mainly on the patient's age.<sup>1-3</sup> Approximately 90% of the cases are children, in whom the lesion keeps a more indolent course and the histological pattern is compatible with 'pilocytic astrocytoma'. These patients mostly suffer from neurofibromatosis type 1 disease and compose one-sixth to one-third of the cases of pediatric optic pathway glioma.<sup>1-3</sup> It is interesting that less than 10% of the cases occur in adulthood and those cases usually have a malignant behavior and a poor outcome.<sup>1-5</sup>

We report a rare case of low-grade astrocytoma originating from the intracranial part of the optic nerve showing a misleading and interesting pattern in MRI.

### Case Presentation

A 48-year-old woman was referred from the ophthalmology department because of severe impairment of vision in her left eye of 6 months duration. The vision had become blurred in the right eye recently. In physical examination, she could count fingers up to 1 meter with her left eye with a pale optic disc in funduscopy. External ocular movements of the eyes were intact and no exophthalmos was detectable. The direct light reflex was non-responsive in the left eye suggesting a relative afferent pupillary light reflex defect in this eye. Examination of the visual field confirmed significant restriction of the field in the left eye

and a temporal hemianopia in the right eye.

Brain MRI (GE, 1.5 T) showed a round mass located in the left subfrontal region beside the optic chiasm and within the gyrus rectus. It was iso-intense in both T1 (Fig. 1A) and T2-weighted sequences (Fig. 1B) without significant enhancement after gadolinium injection (Figs. 2.A-C). It was difficult to ascertain whether it was an intra- or extra-axial lesion regarding these images.

A left fronto-temporal craniotomy was performed. The tumor was separated from the adjacent cerebral cortex easily via a plane of pia-arachnoid existing between the tumor and the adjacent brain tissue. A pressure effect of the tumor on the chiasma was noted but it was separated simply and no obvious adhesion to the optic chiasma was noted. The tumor did not have any separating plane with the optic nerve and after dissecting the periphery of the tumor, a wide based connection was noted between the exophytic verrucous mass and the optic nerve. After piecemeal resection of most of the tumor, the optic nerve was saved with minimal residual tumor. The histo-pathological examination revealed islands of compact elongated cells that were markedly fibrillated, and were interposed with sparse areas of loose microcystic tissue. Eosinophilic granular bodies were scattered among the cellular aggregates. Interestingly,

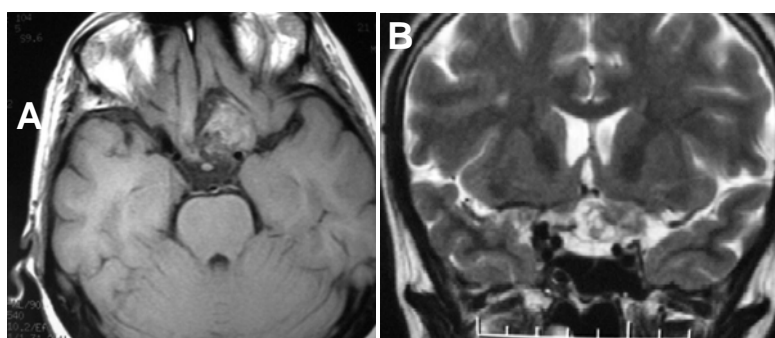
normal structures of the optic nerve fibers were preserved in the neighboring regions (Fig. 3A). The surgical findings are illustrated in the sketch of the operative field visualized microscopically (Fig. 3B). The diagnosis was pilocytic astrocytoma of the optic nerve. The postoperative course was uneventful and when visited after 4 weeks, her vision was almost 5/10 in routine computed grading scale. She received a standard course of brain irradiation consisting of 4500 Gy's in separated sessions and after 15 months there was no sign of tumor recurrence in the control MRI and her vision was unchanged (Fig.4).

## Discussion

### Genesis and Histology

Optic pathway glioma (OPG) includes a heterogeneous group of rare diseases, varying from a benign self-limiting condition in some patients to a rapidly progressive course in others.<sup>3,4</sup> Classically, two different patterns have been mentioned in these patients: 1) The more common childhood benign optic nerve gliomas, with a tendency to occur in patients with neurofibromatosis type 1 (NF1), and 2) The less common (about 10% of cases) comprising the adult malignant optic gliomas.<sup>1-5</sup>

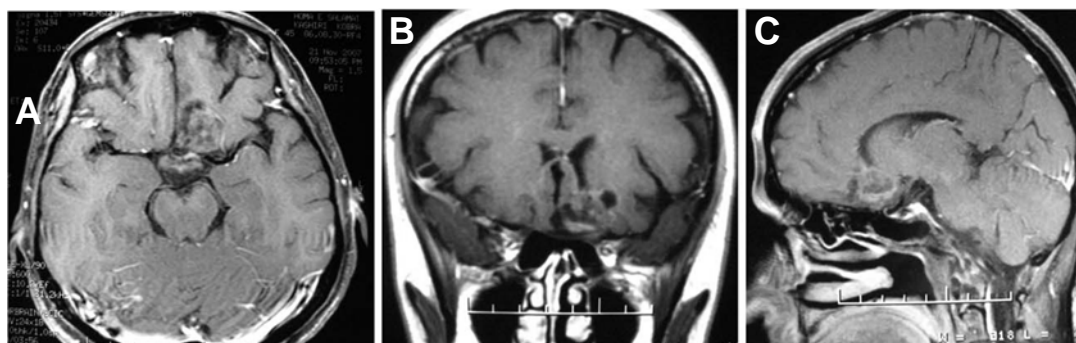
In adults, optic nerve glioma is a lethal condition



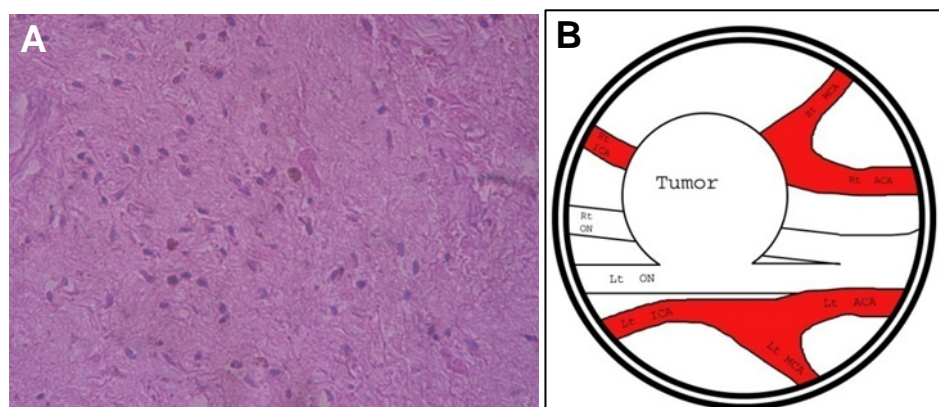
**Fig.1.** Brain MRI without contrast;

**A.** Axial T1-weighted sequence showing an isointense mass near the left rectus gyrus.

**B.** Coronal T2-weighted image revealing a left sided heterogeneous supra-sellar mass.

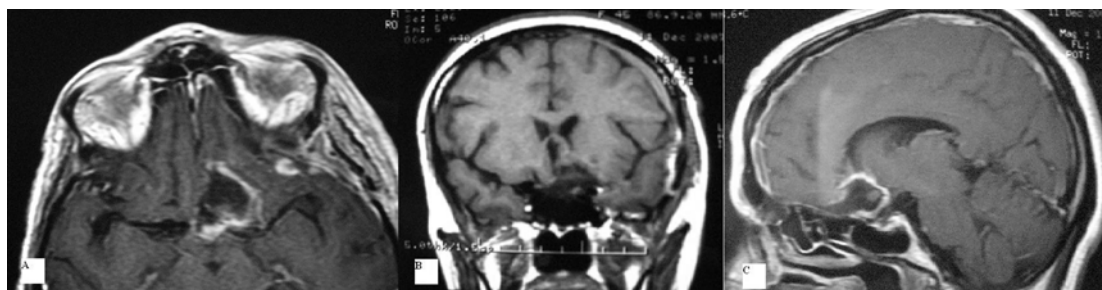


**Fig. 2.** Brain MRI after gadolinium injection; **A.** Axial, **B.** Coronal and **C.** Sagittal views depicting a heterogeneous and lobulated mass in the left supra-sellar region without significant gadolinium enhancement, difficult to ascertain whether intra-or extra-axial.



**Fig. 3. A.** H&E stained section of the left supra-sellar mass, reveals islands of compact elongated cells that are markedly fibrillated and are interposed with sparse areas of loose microcystic tissue. Eosinophilic granular bodies are scattered among the cellular aggregates. Normal structures of the optic nerve fibers are seen on the right side.

**B.** Schematic illustration of the operative field visualized microscopically.



**Fig. 4.** MRI performed 15 months after surgery denoting the nonhomogeneously enhancing tumor bed in all three planes of imaging without any sign of tumor recurrence.

**A.** Axial view, **B.** Coronal view, **C.** Sagittal view

characterized by a sudden onset of visual loss associated with enlargement of the optic nerve in MR images,<sup>4,7</sup> which is usually difficult to distinguish from other causes of optic nerve enlargement, such as optic neuritis.<sup>4,7,8</sup> A benign histopathology is rare in adult cases of OPGs. From another point of view, cases of OPG can be classified as those accompanying neurofibromatosis type 1, and the sporadic cases. Association with NF1 is believed to be linked with a more favorable outcome, while non-NF1 patients are thought to have a significant risk of progression and demand a kind of intervention.<sup>3,9</sup> This case happened in a middle-aged lady without NF1 but has had a benign histopathologic behavior based upon the histopathologic findings and natural history of the patient up to now.

### Clinical Presentation and Similar Cases

Although the old belief of spread via the proximal stump of the optic nerve in non-NF1 cases is not widely accepted anymore, the expected architectural form of the tumor in non-NF1 cases is the expansile-

intraneural pattern, and an exophytic growth pattern is uncommon in these cases.<sup>3,6,9</sup>

The largest reported series of adult OPGs consists of 7 cases that were all of an intra-orbital origin and presented as an expanding orbital mass.<sup>10</sup> There is one other report of benign adult ONG, which is also associated with intraorbital and intraocular tumor involvement.<sup>11</sup> According to our review of the literature, this seems to be a rare case of adult ONG neither involving the intra-orbital optic nerve, nor infiltrating the intracranial optic apparatus and only keeping an exophytic pattern from the intracranial optic nerve (Fig. 3).

To our knowledge, this is the first case report of unilateral benign ONG in an adult patient without involvement of the intraorbital portion of the optic nerve. We suggest that microsurgical resection of this histopathologically benign tumor may improve the visual outcome without the risk of residual tumor regrowth.<sup>6</sup>

## References

1. Miyamoto J, Sasajima H, Owada K, Mineura K. Surgical decision for adult optic glioma based on [<sup>18</sup>F] fluorodeoxyglucose positron emission tomography study. *Neurol Med Chir (Tokyo)* 2006 Oct;46(10):500-3.
2. Matsumoto H, Masuo O, Kuwata T, Moriwaki H, Uematsu Y, Itakura T. A case report and review: malignant optic glioma in adulthood. *No Shinkei Geka* 1997;6:838-43.
3. Astrup J. Natural history and clinical management of optic pathway glioma. *Br J Neurosurg* 2003;17(4):327-35.
4. Wabbels B, Demmler A, Seitz J, Woenckhaus M, Bloss HG, Lorenz B. Unilateral adult malignant optic nerve glioma. *Graefes Arch Clin Exp Ophthalmol* 2004;42(9):741-8.
5. Dario A, Iadini A, Cerati M, Marra A. Malignant optic glioma of adulthood. Case report and review of the literature. *Acta Neurol Scand* 1999;100(5):350-3.
6. Tong Z, Wanibuchi M, Uede T, Tanabe S, Hashi K. Significant improvement of visual functions after removal of an intracranial giant optic nerve glioma revealing exophytic growth: case report. *Neurosurgery* 2006;58(4):E792.
7. Millar WS, Tartaglino LM, Sergott RC, Friedman DP, Flanders AE. MR of malignant optic glioma of adulthood. *AJNR Am J Neuroradiol* 1995;16:1673-6.
8. Taphoorn MJ, de Vries-Knoppert WA, Ponsen H, Wolbers JG. Malignant optic glioma in adults. Case report. *J Neurosurg* 1989;70:277-9.
9. Stern J, Jakobiec FA, Housepian EM. The architecture of optic nerve gliomas with and without neurofibromatosis. *Arch Ophthalmol* 1980;98:505-11.
10. Wulc AE, Bergin DJ, Barnes D, Scaravilli F, Wright JE, McDonald WI. Orbital optic nerve glioma in adult life. *Arch Ophthalmol* 1989;107(7):1013-6.
11. Rodríguez-Francia P, Sánchez-Tocino H, García-Cantera M, Martín-Castillo J. Optic nerve pilocytic astrocytoma with retinal involvement. *Arch Soc Esp Ophthalmol* 2000;80(12):733-6.